



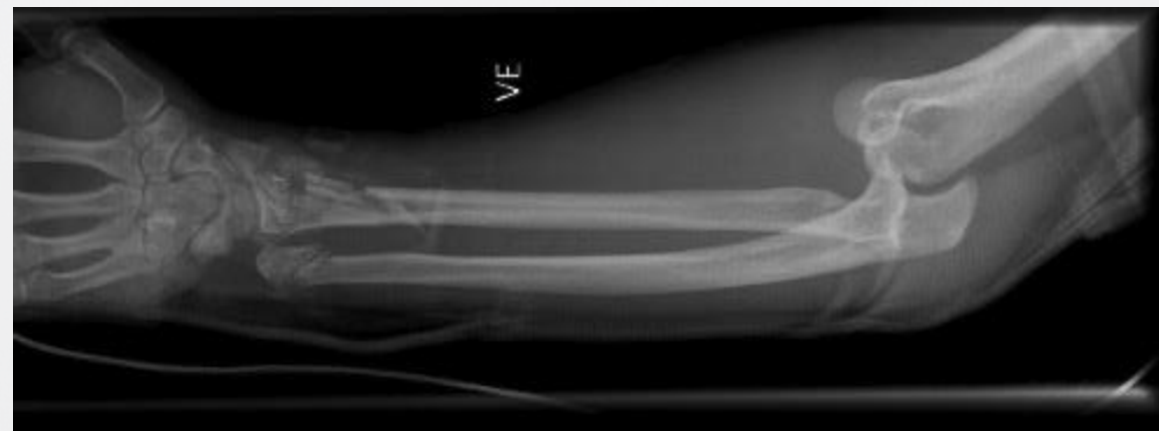Uncommon Forearm Fractures



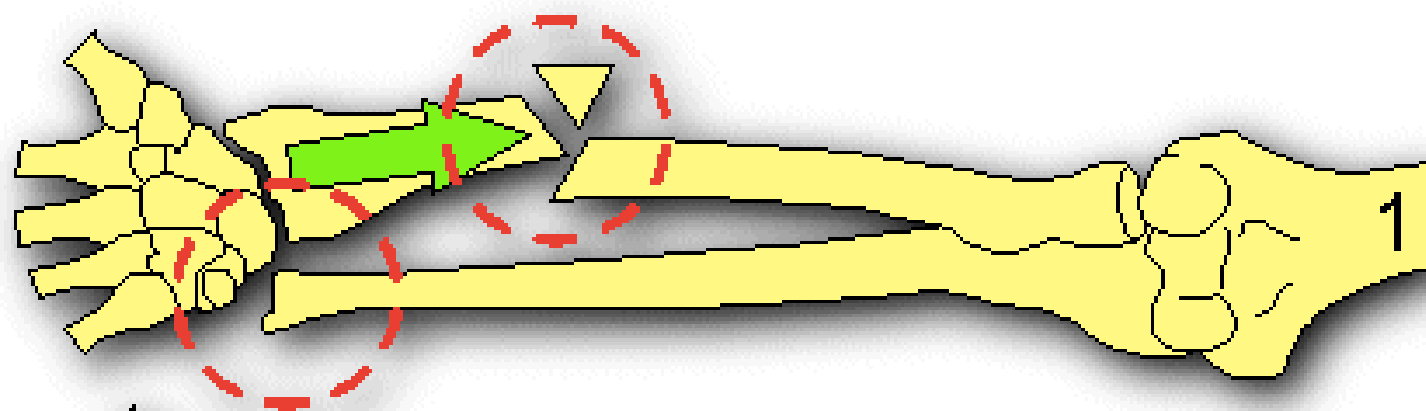
Longitudinal instability & Shaft fractures combined with luxations

Yngvar Krukhaug MD,PhD

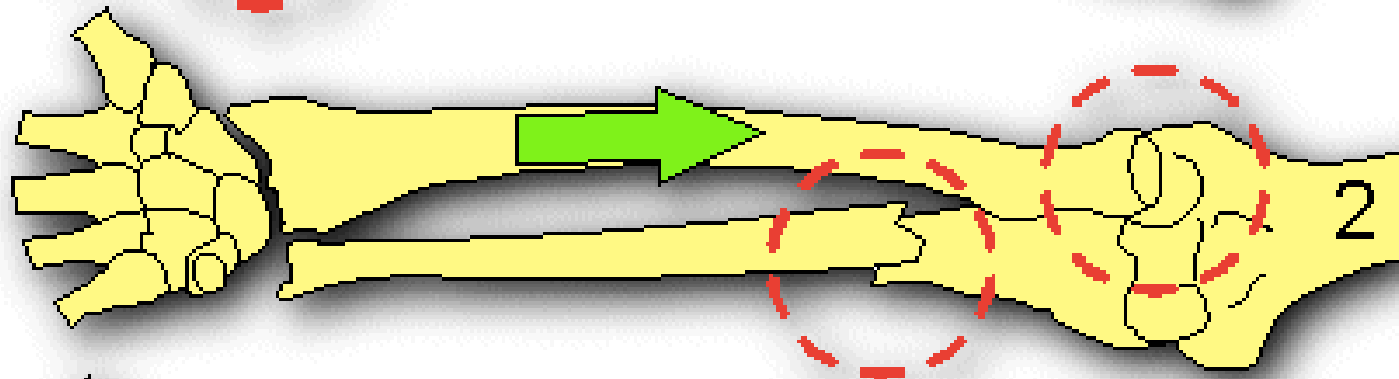
Consultant Orthopaedic Surgeon
Associate Professor
Section for Orthopaedic Surgery
Haukeland University Hospital
Department of Surgical Sciences,
University of Bergen,
Bergen, Norway



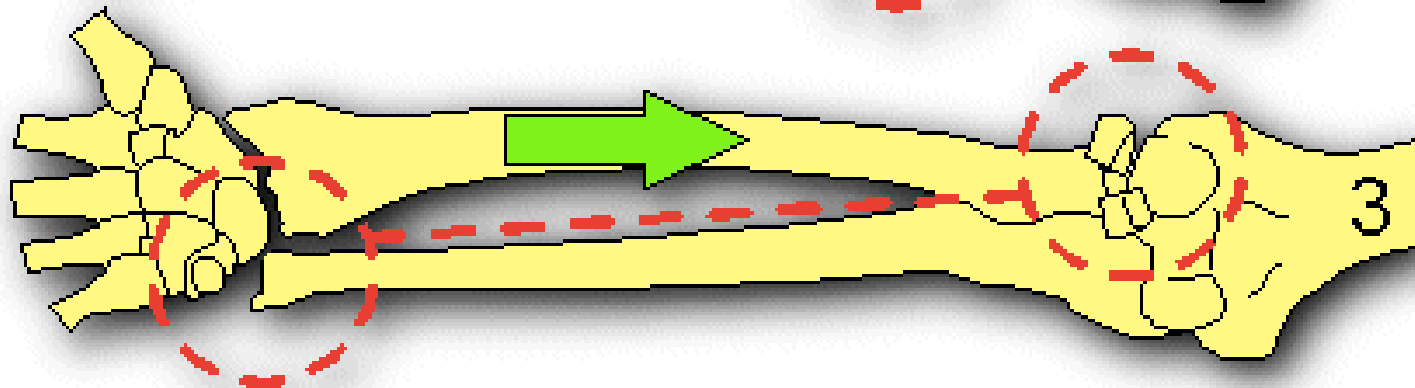
Uncommon Forearm Fractures



Galeazzi



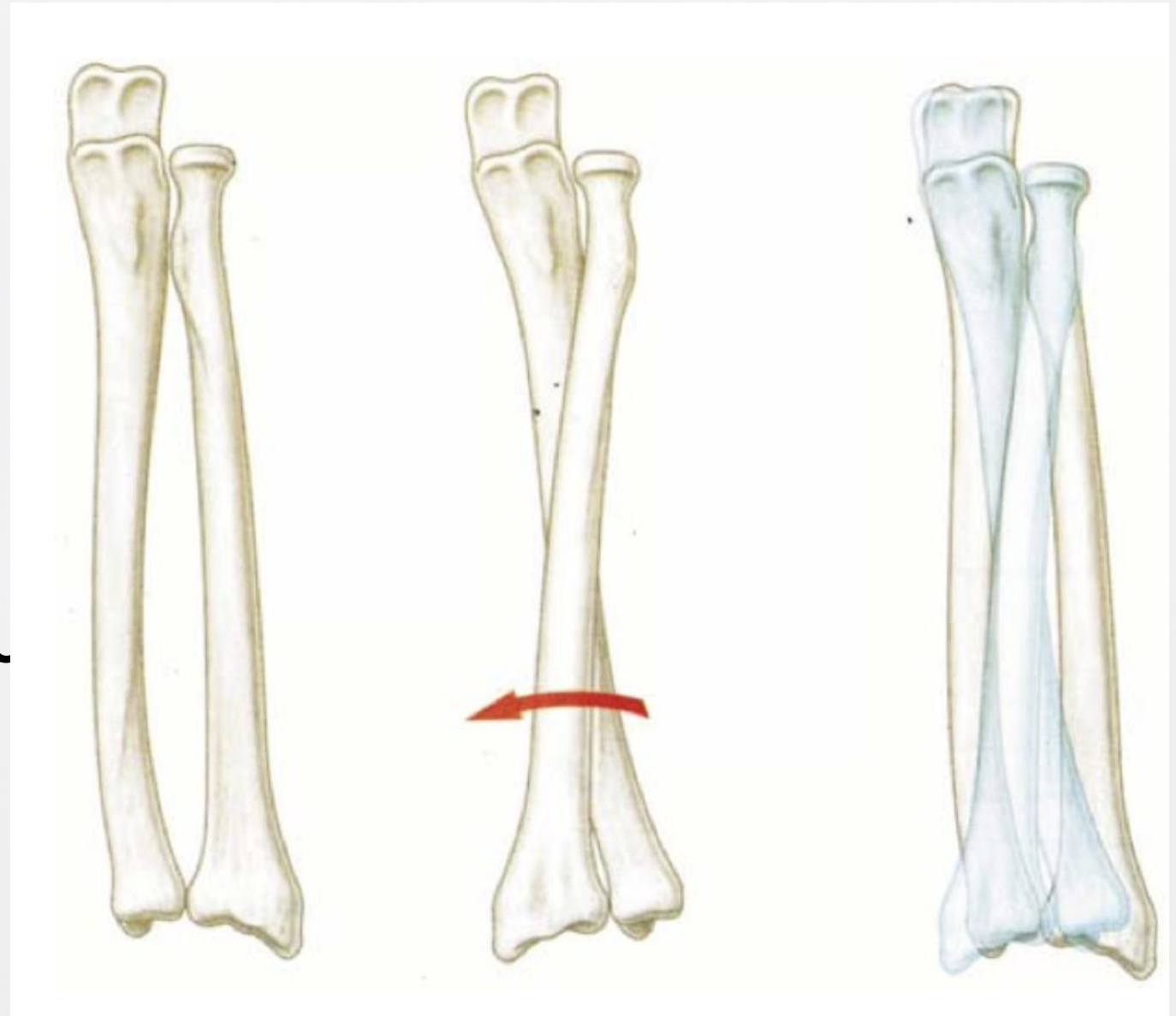
Monteggia



Essex-Lopresti

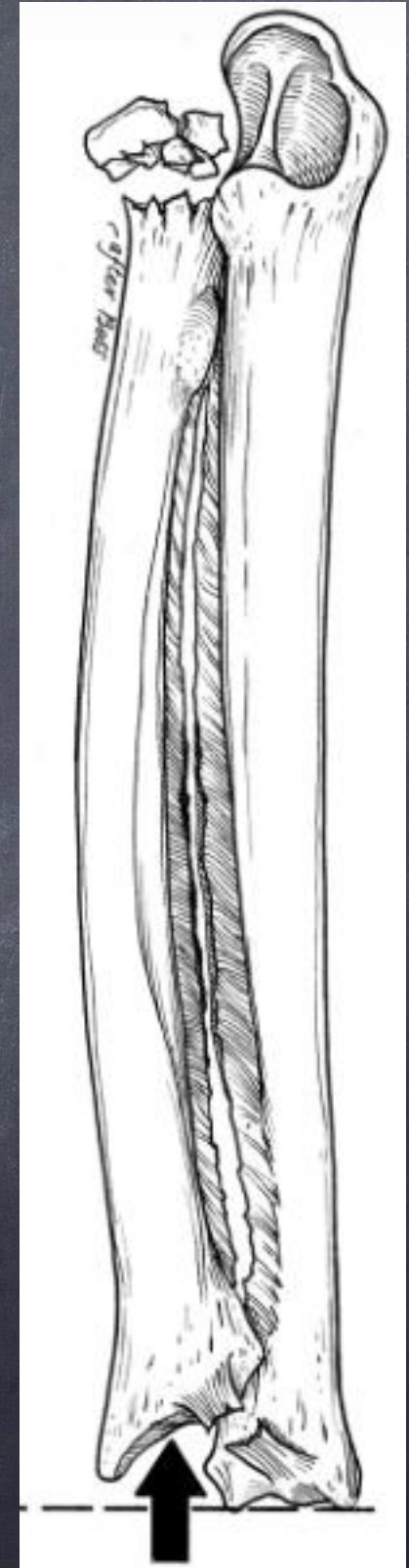
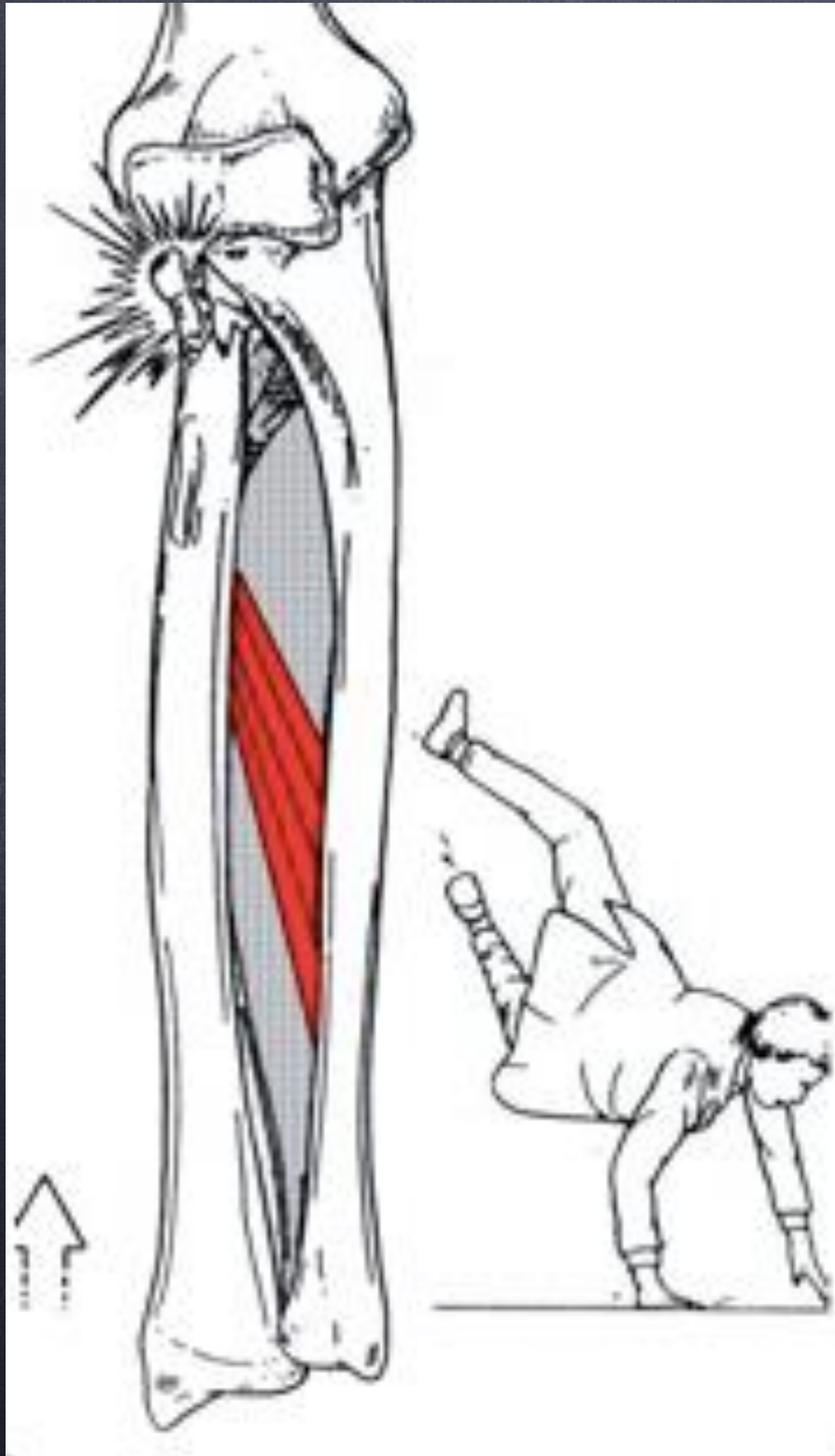
"The forearm joint"

Forearm fractures should be treated similar as intra articular fractures

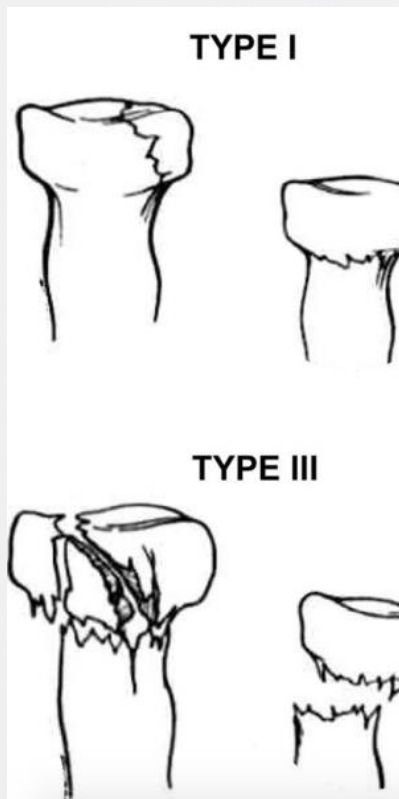


Hagert CG. Distal radius fracture and the distal radioulnar joint--anatomical considerations. Handchir Mikrochir Plast Chir. 1994; 26:22-26.

Essex- Loopresti



Mason classification



ent

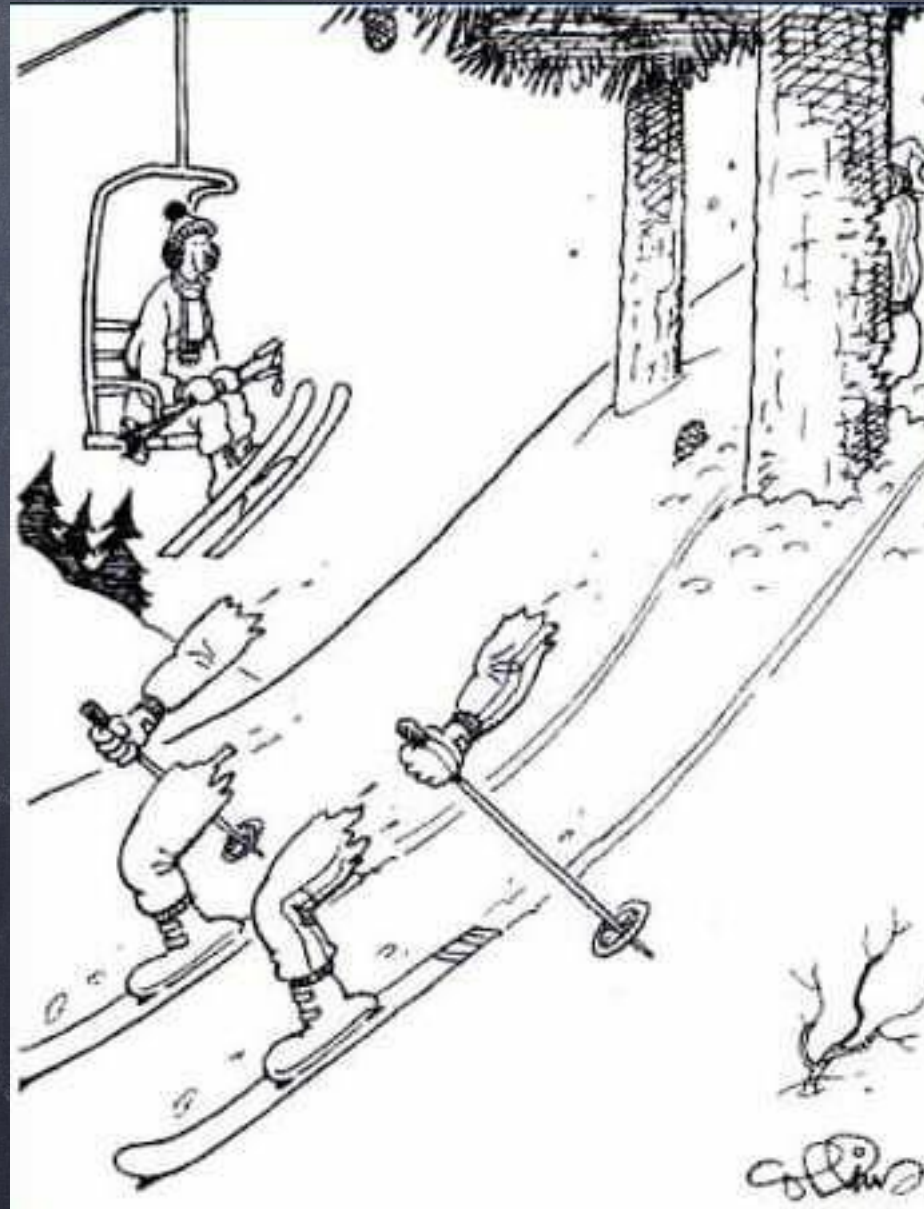
stability → ORIF or excision

ility → ORIF +/- ligament

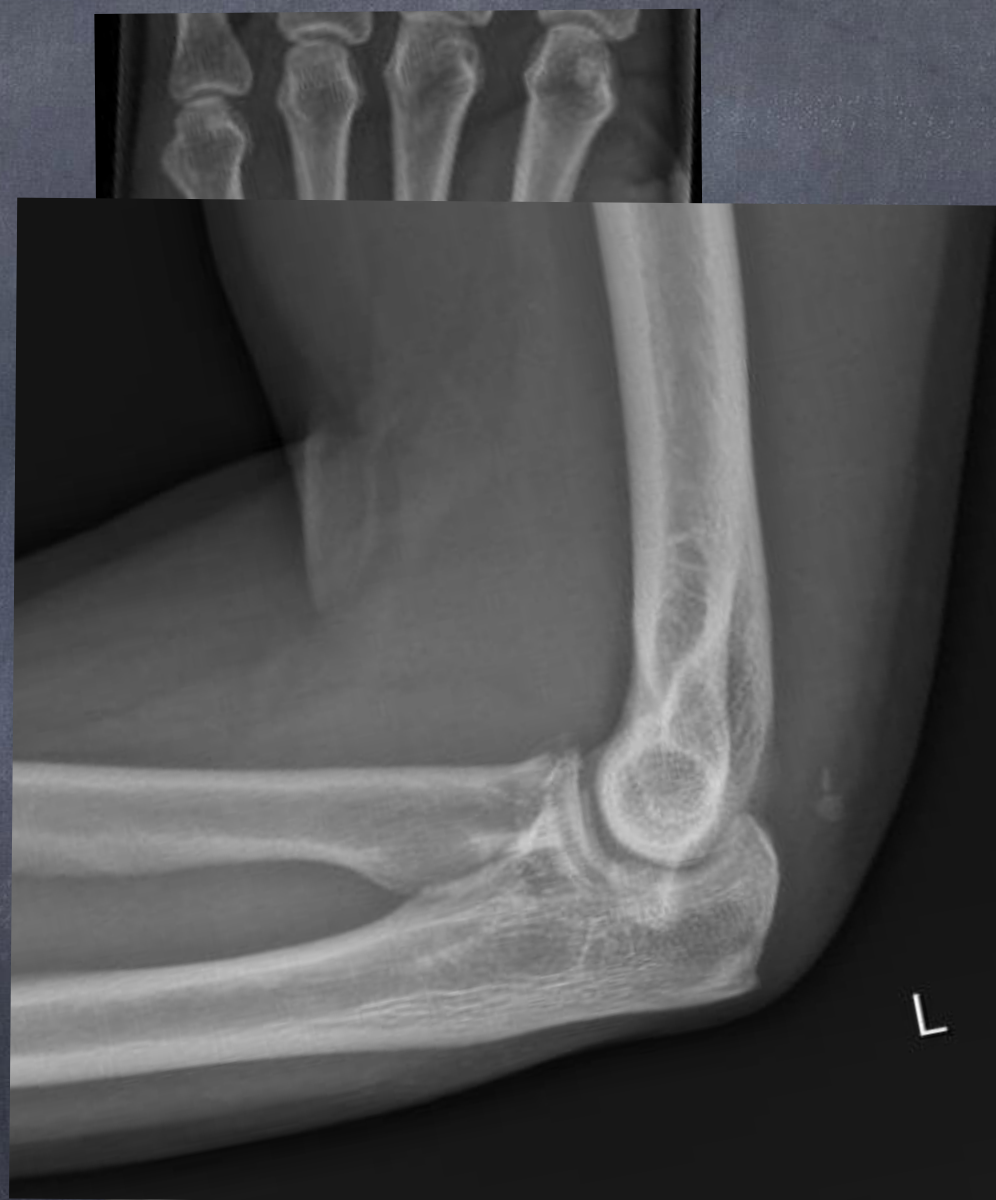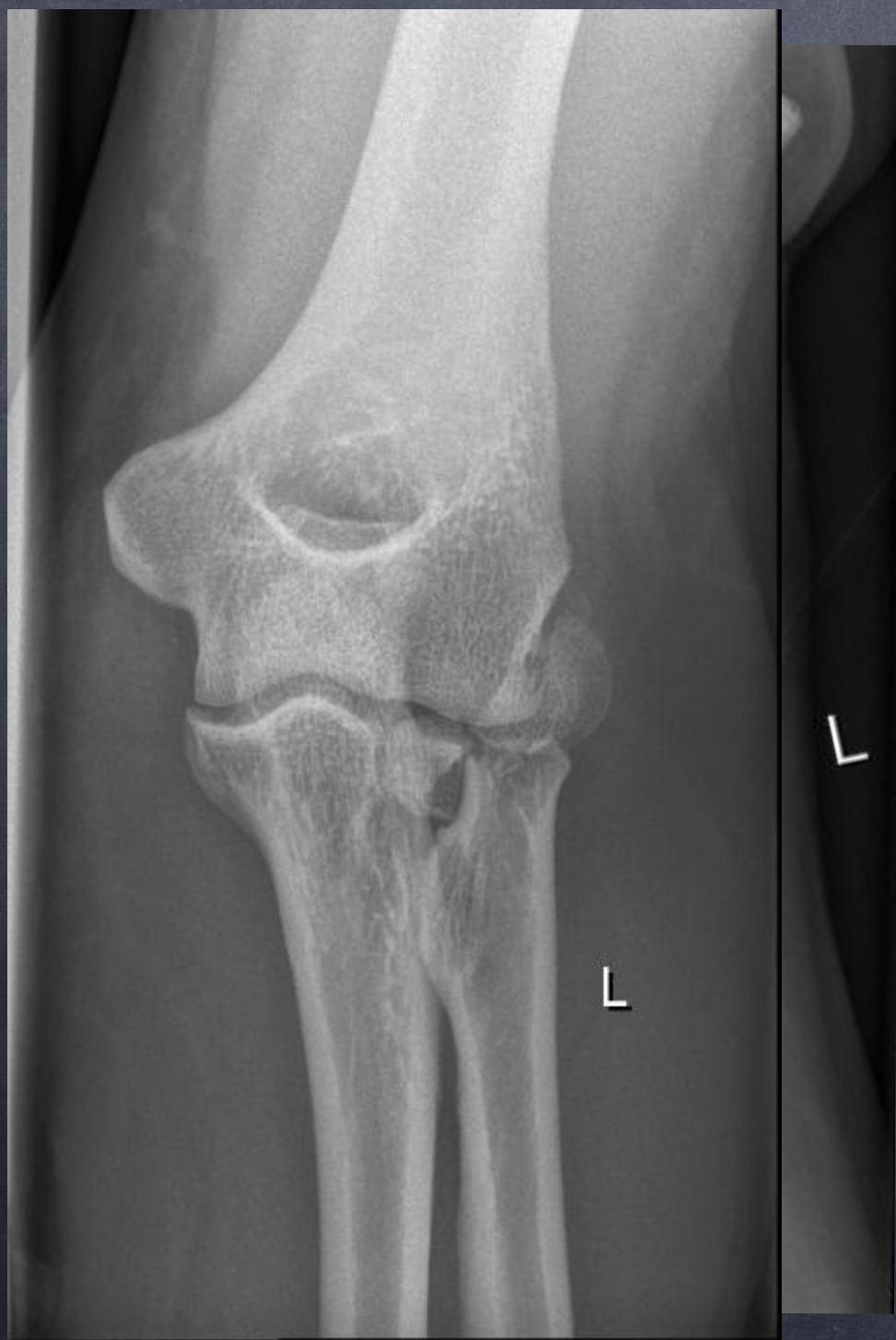
ction of
ligament reconstruction

Fix or replace the head **ALWAYS**

Male 52 years Downhill skiing accident

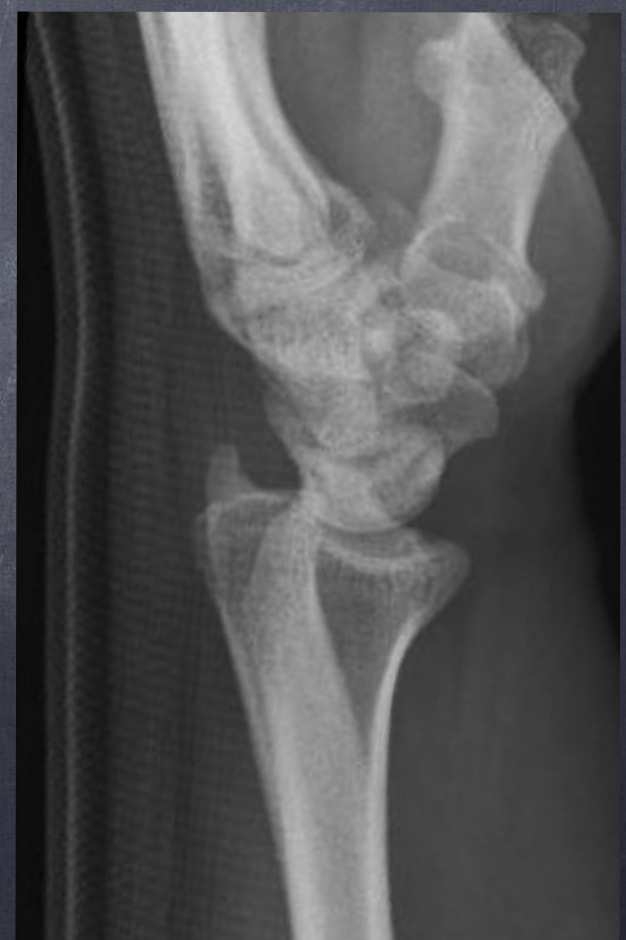
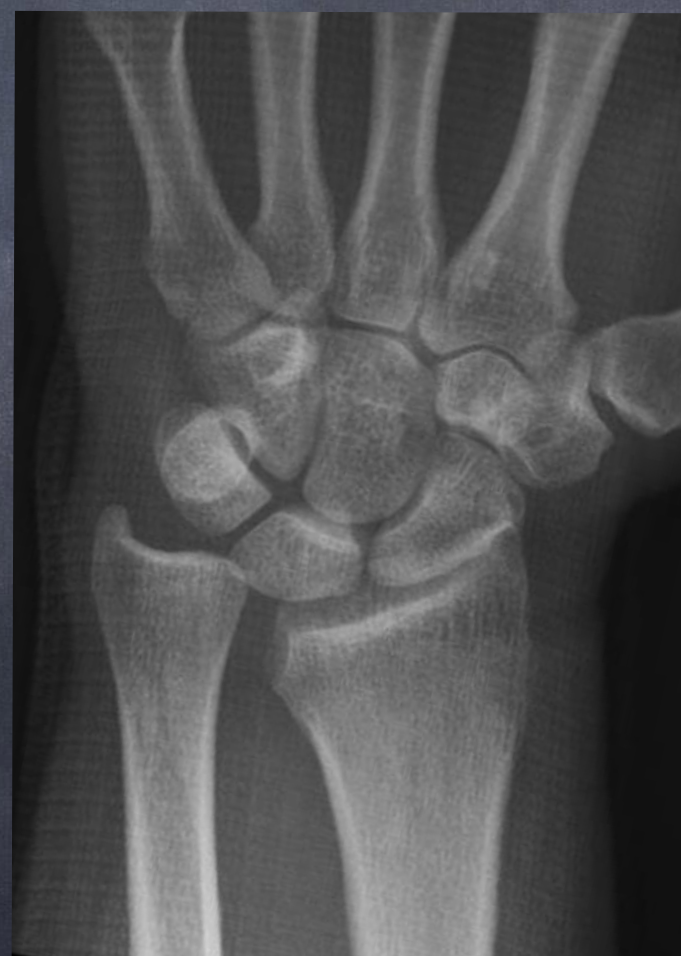
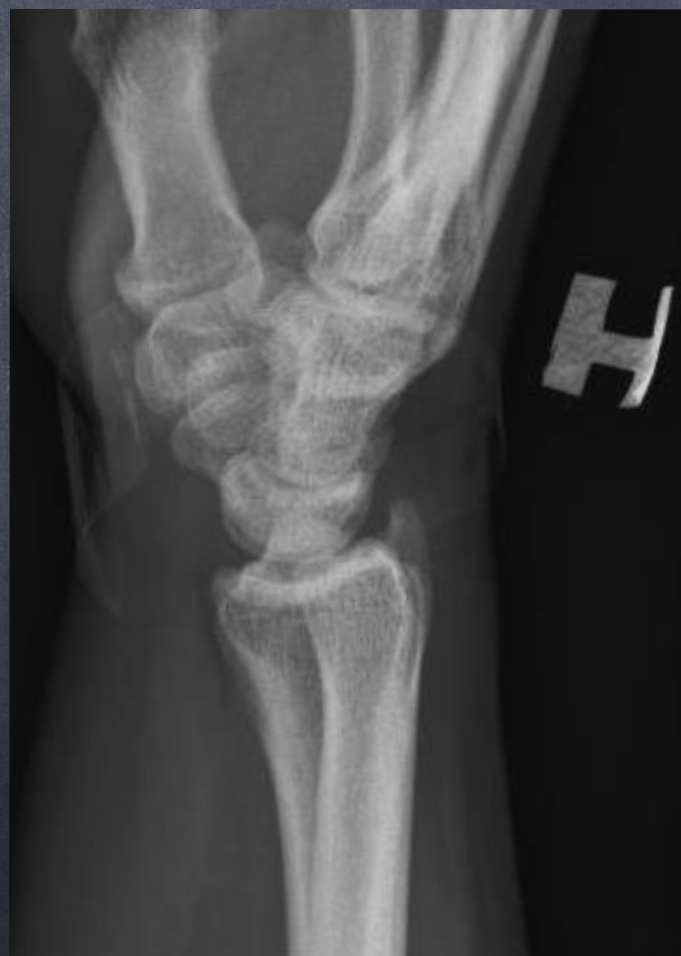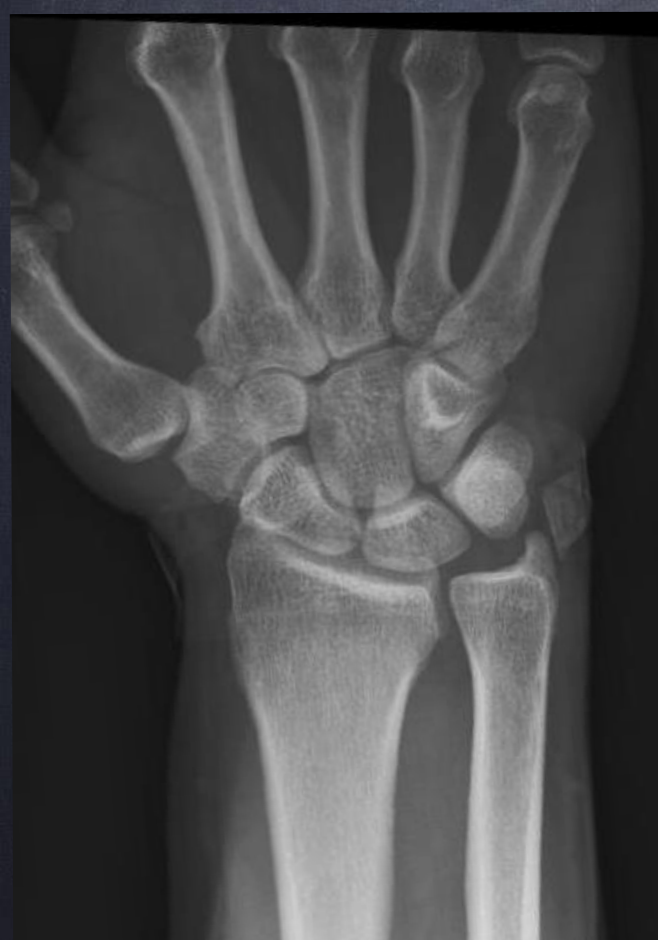Acute



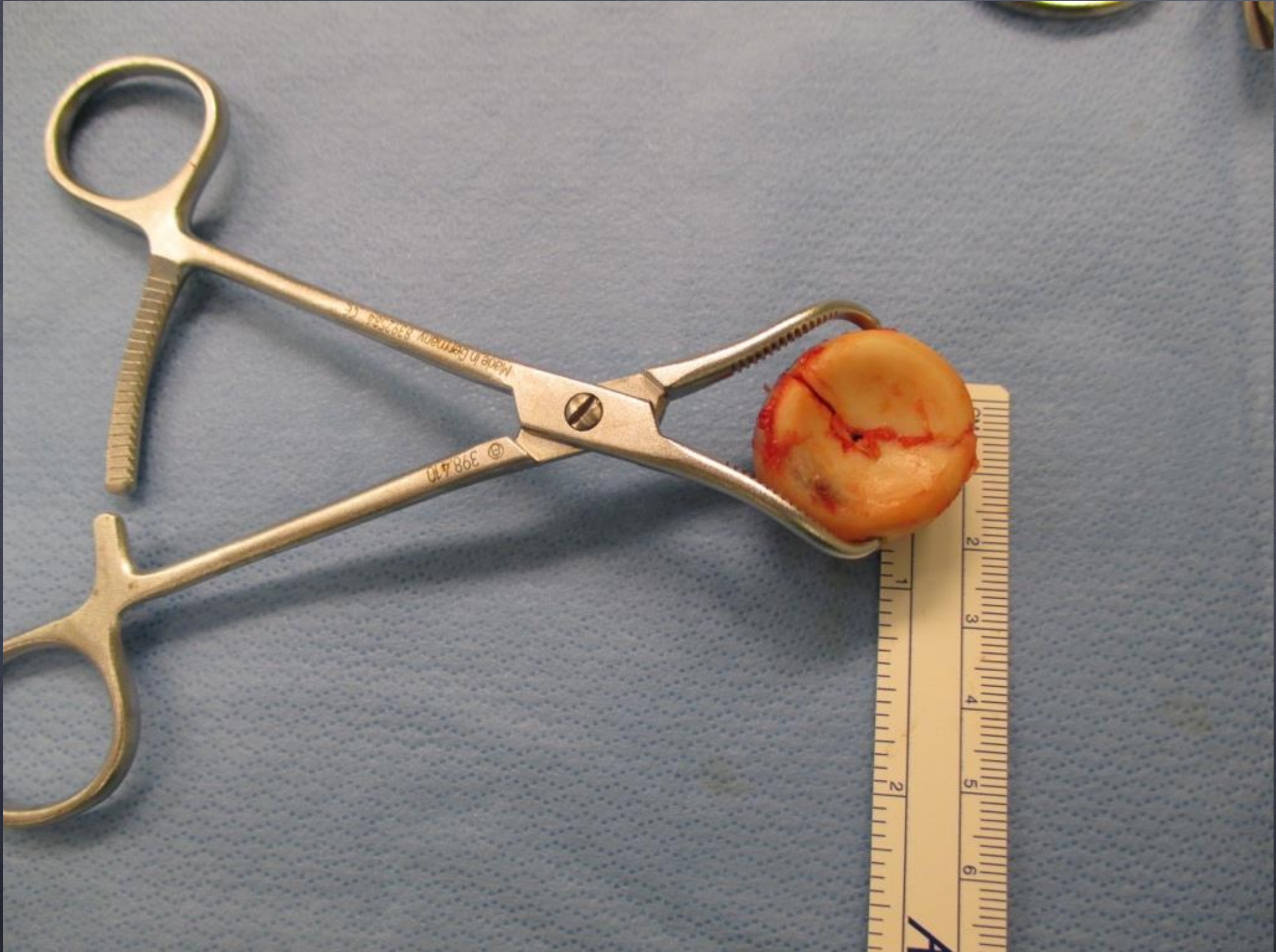
One week after injury

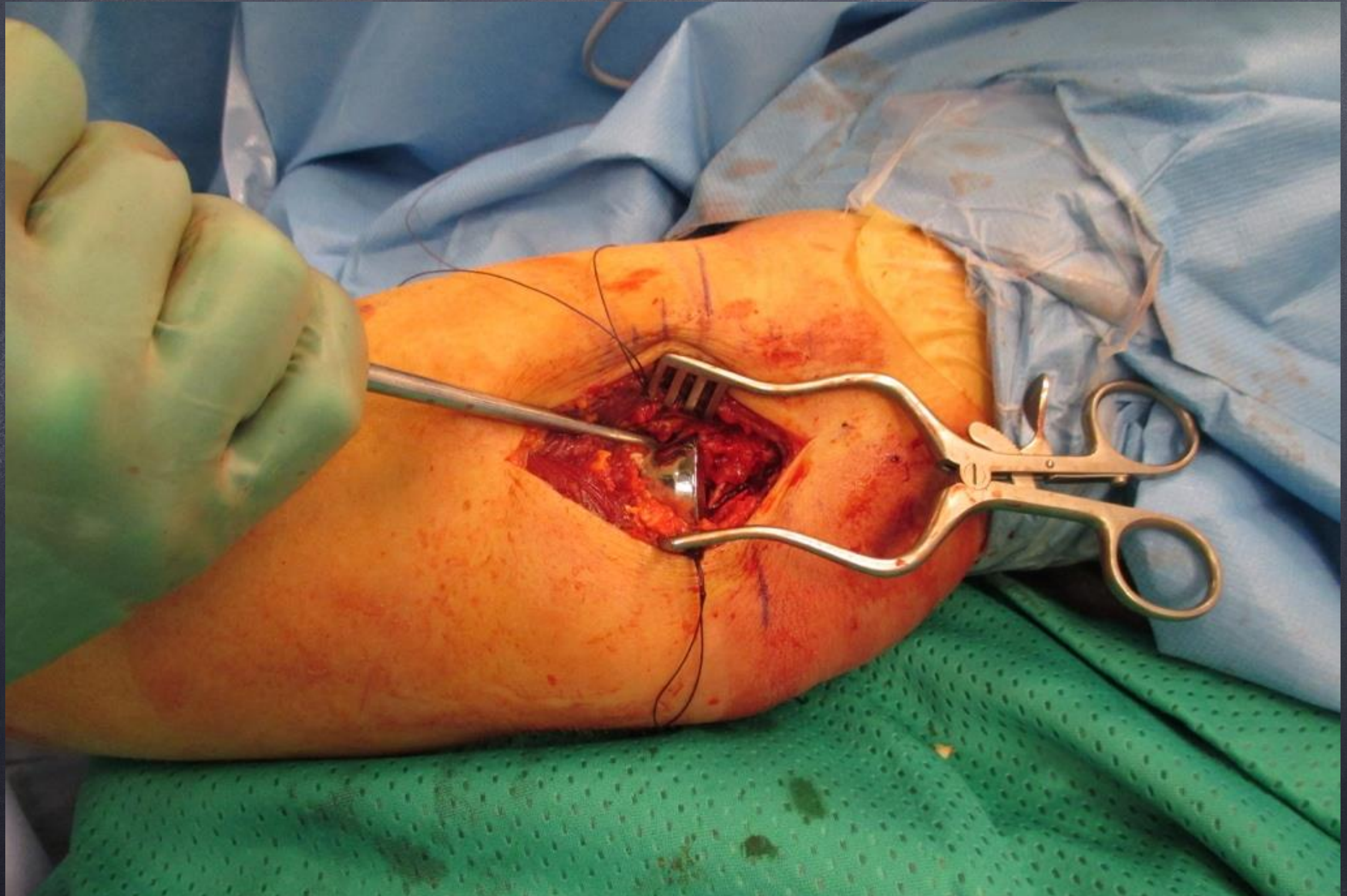
Uninjured hand for comparison

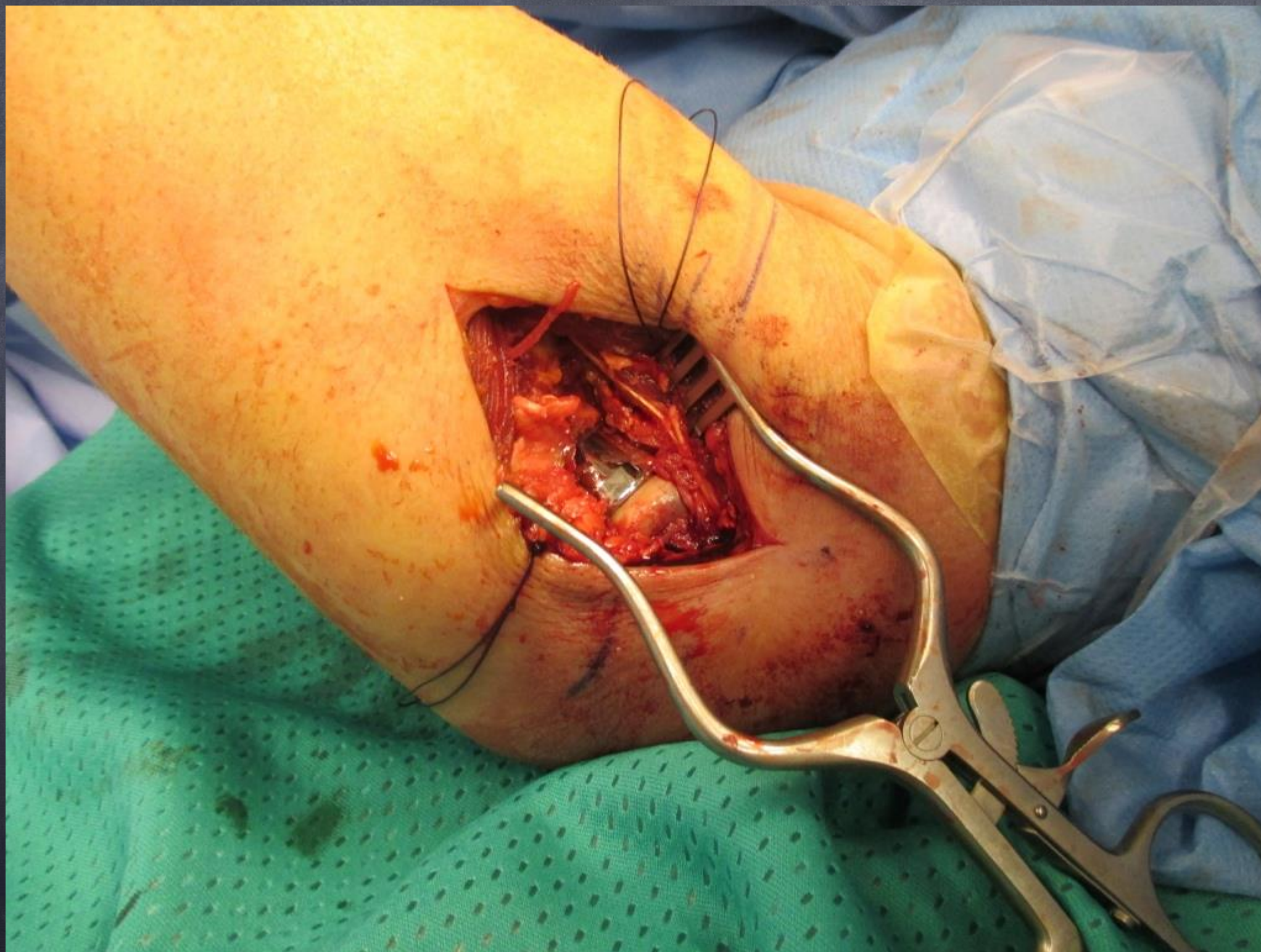


Uninjured side

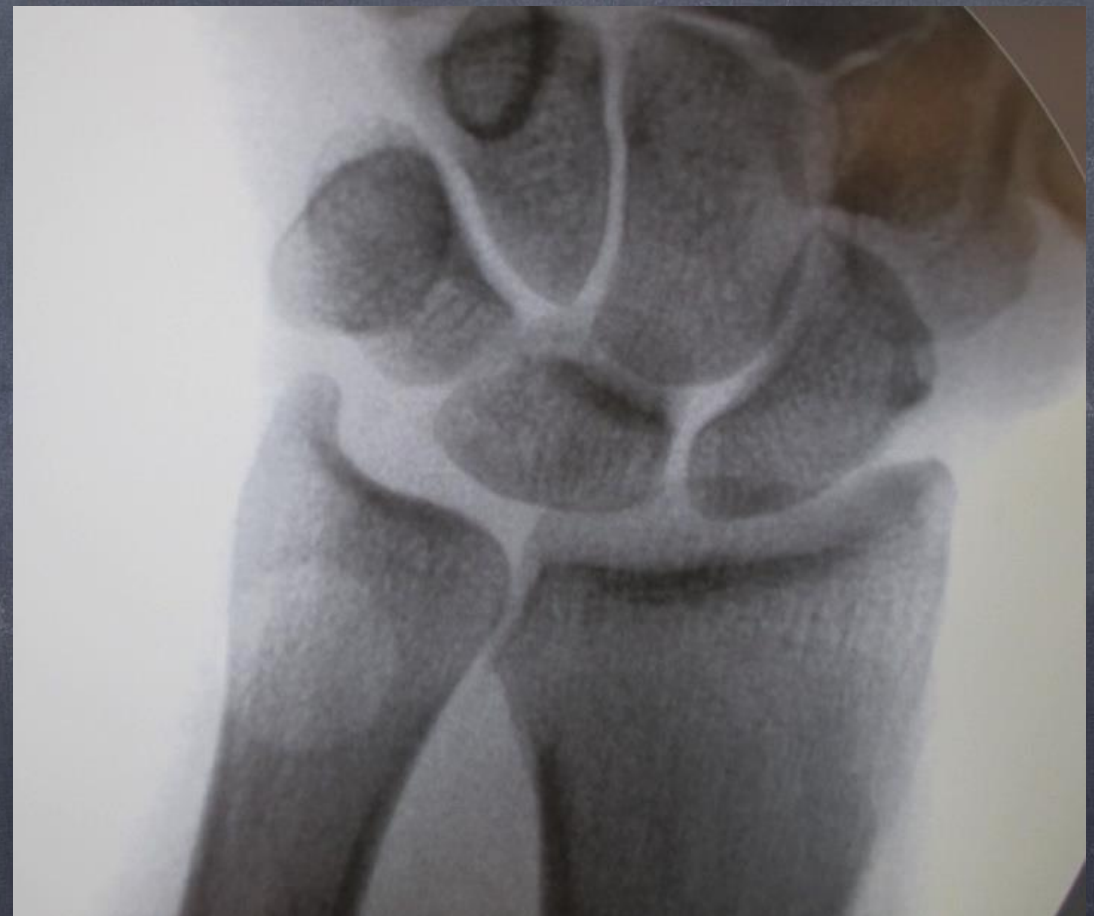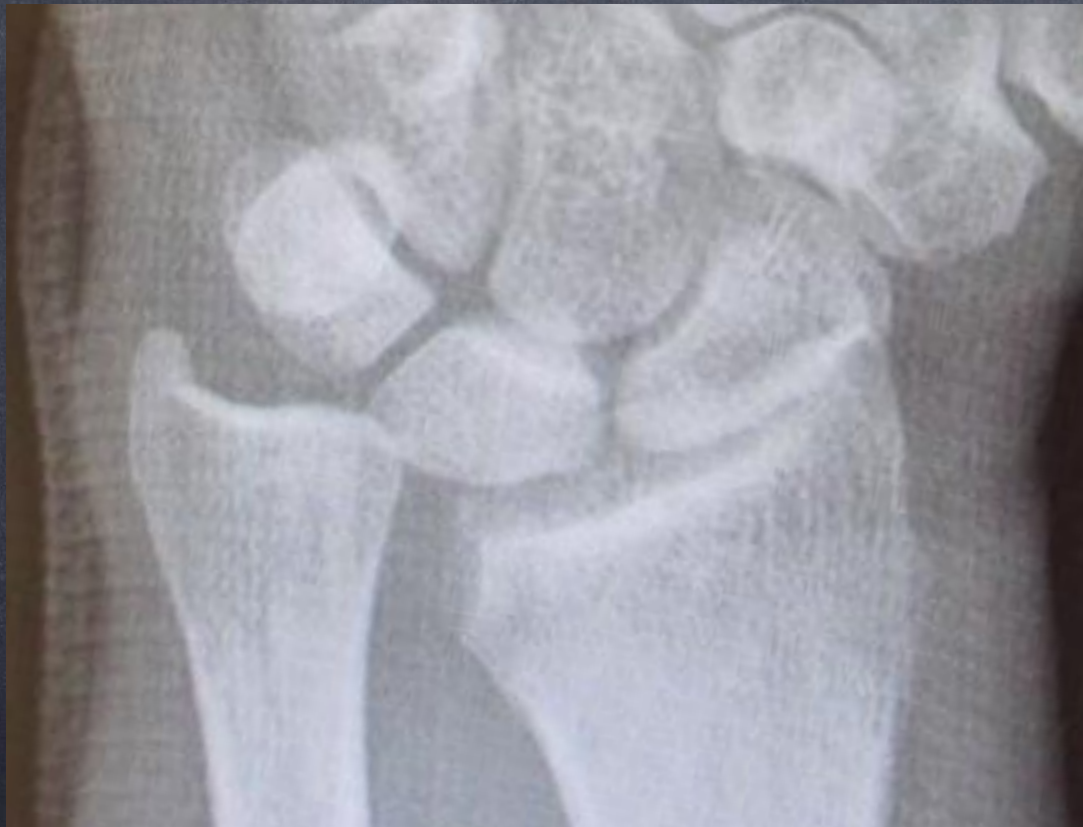Injured side

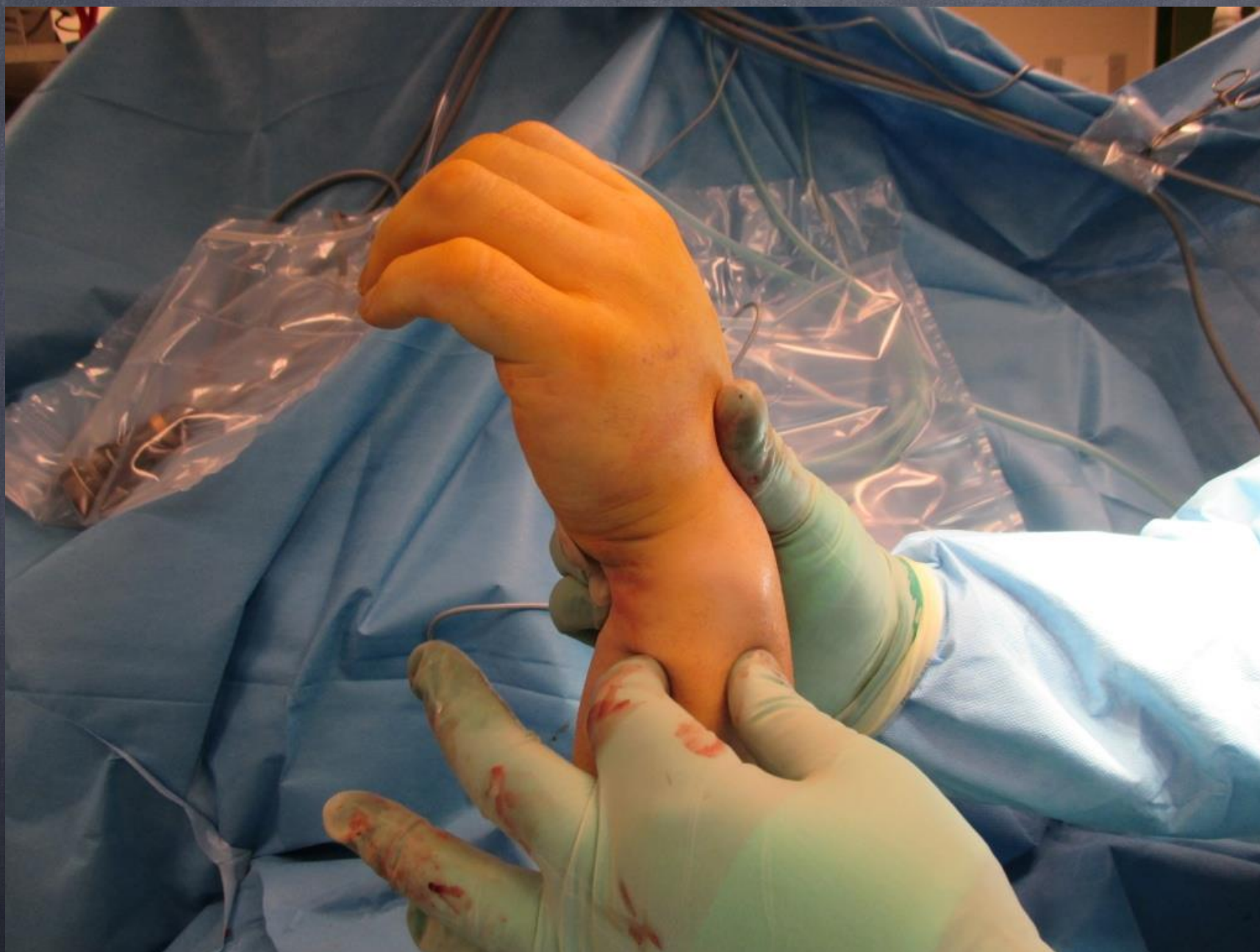


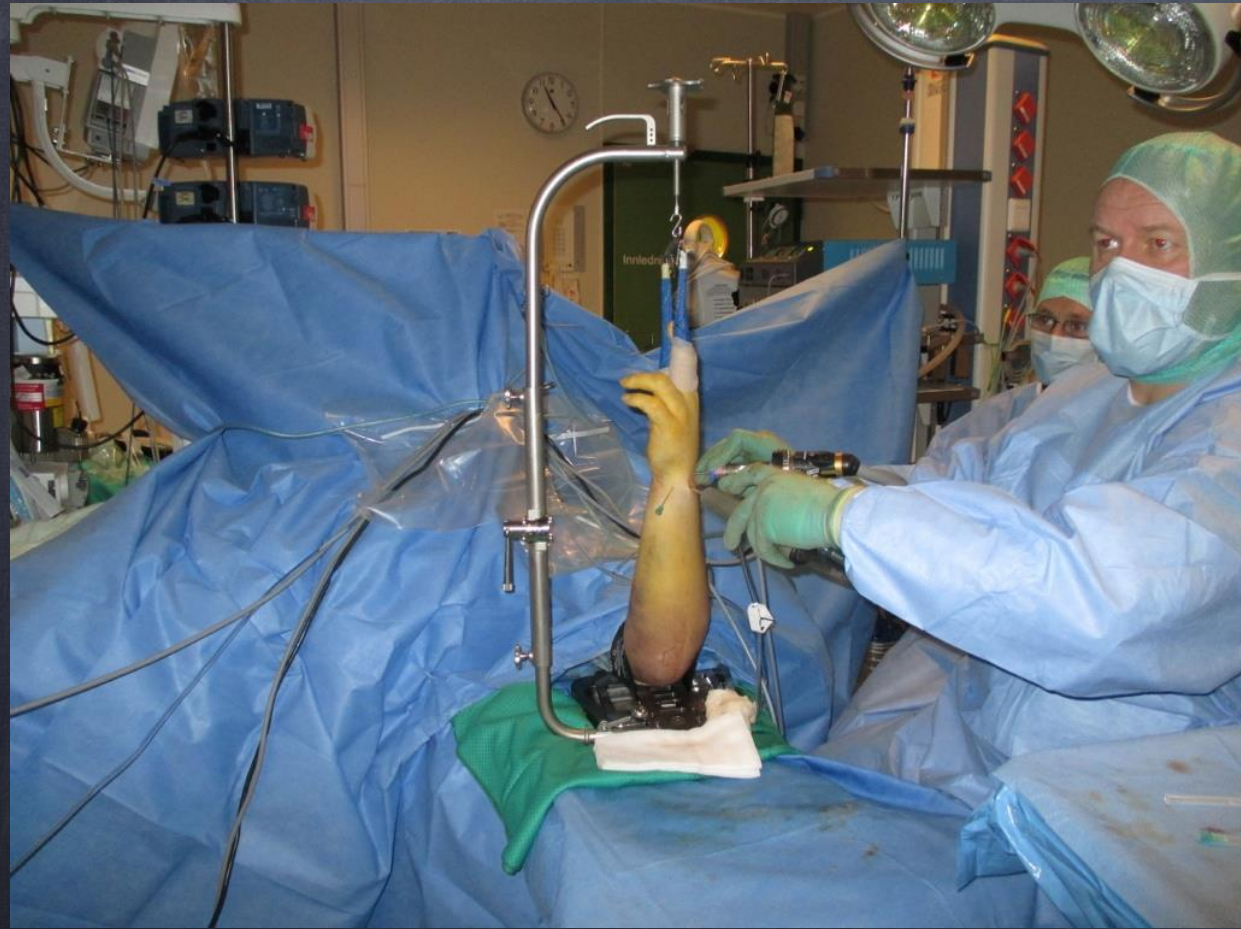


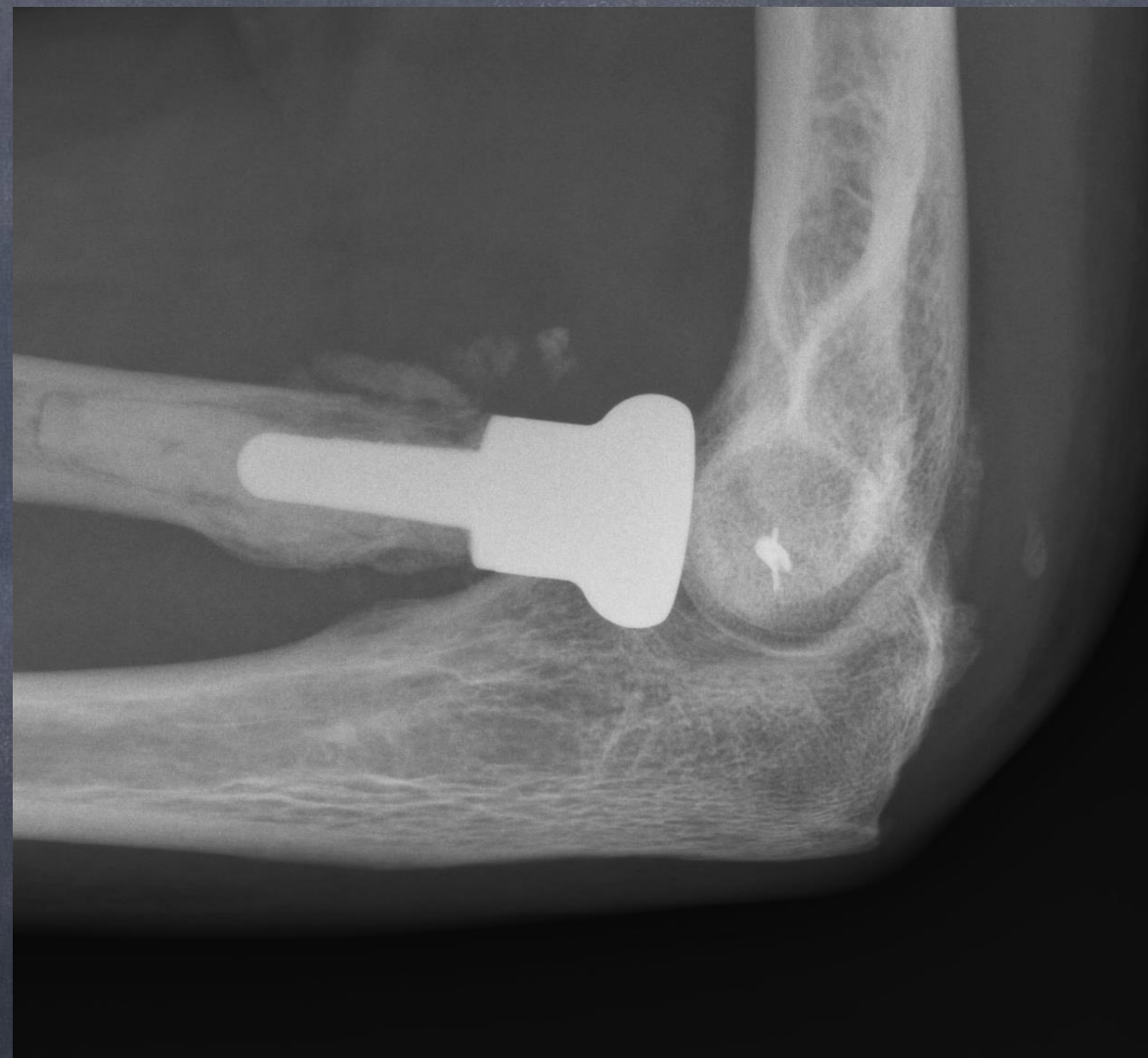
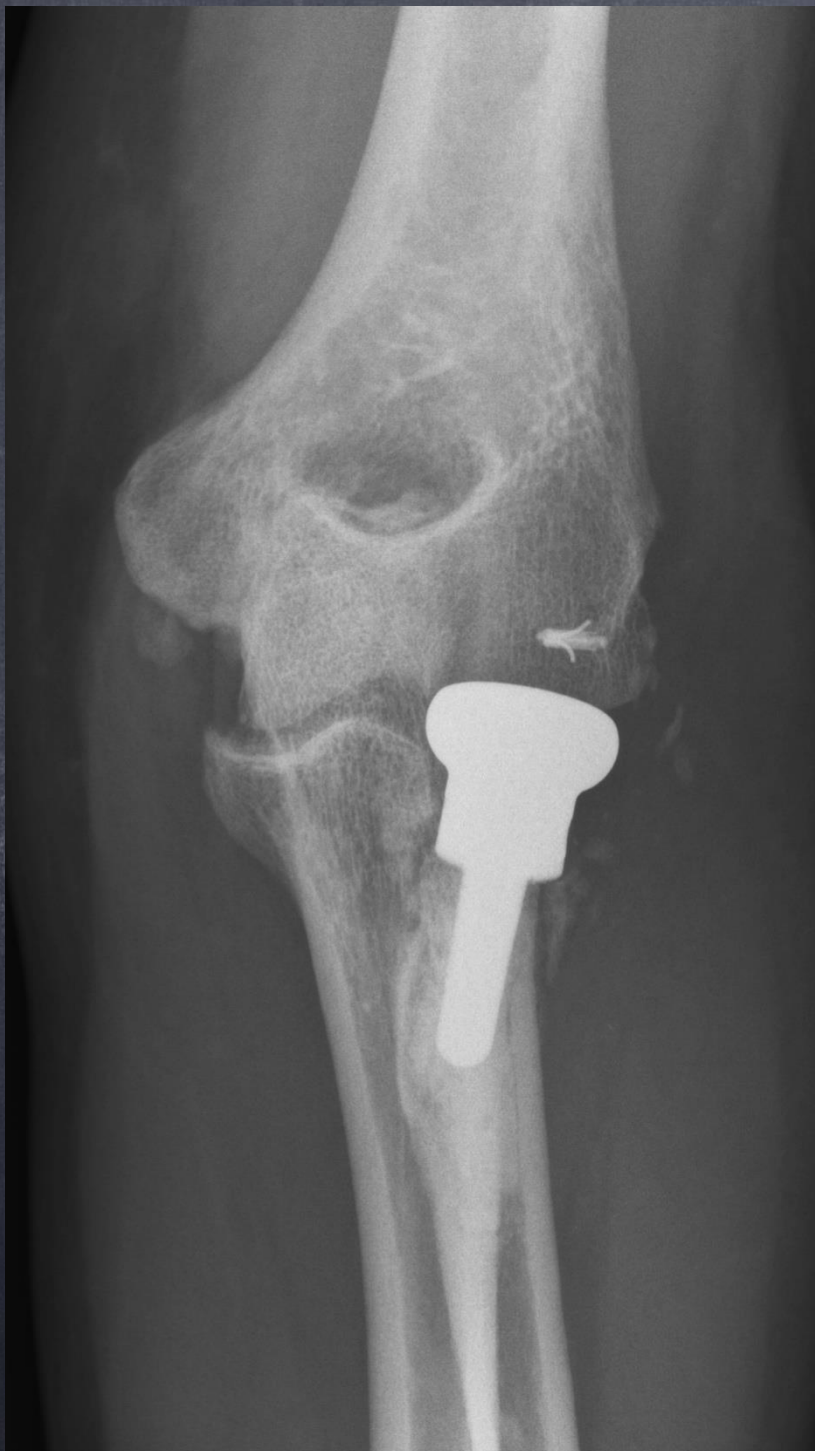Before and after prosthesis







6 month follow up



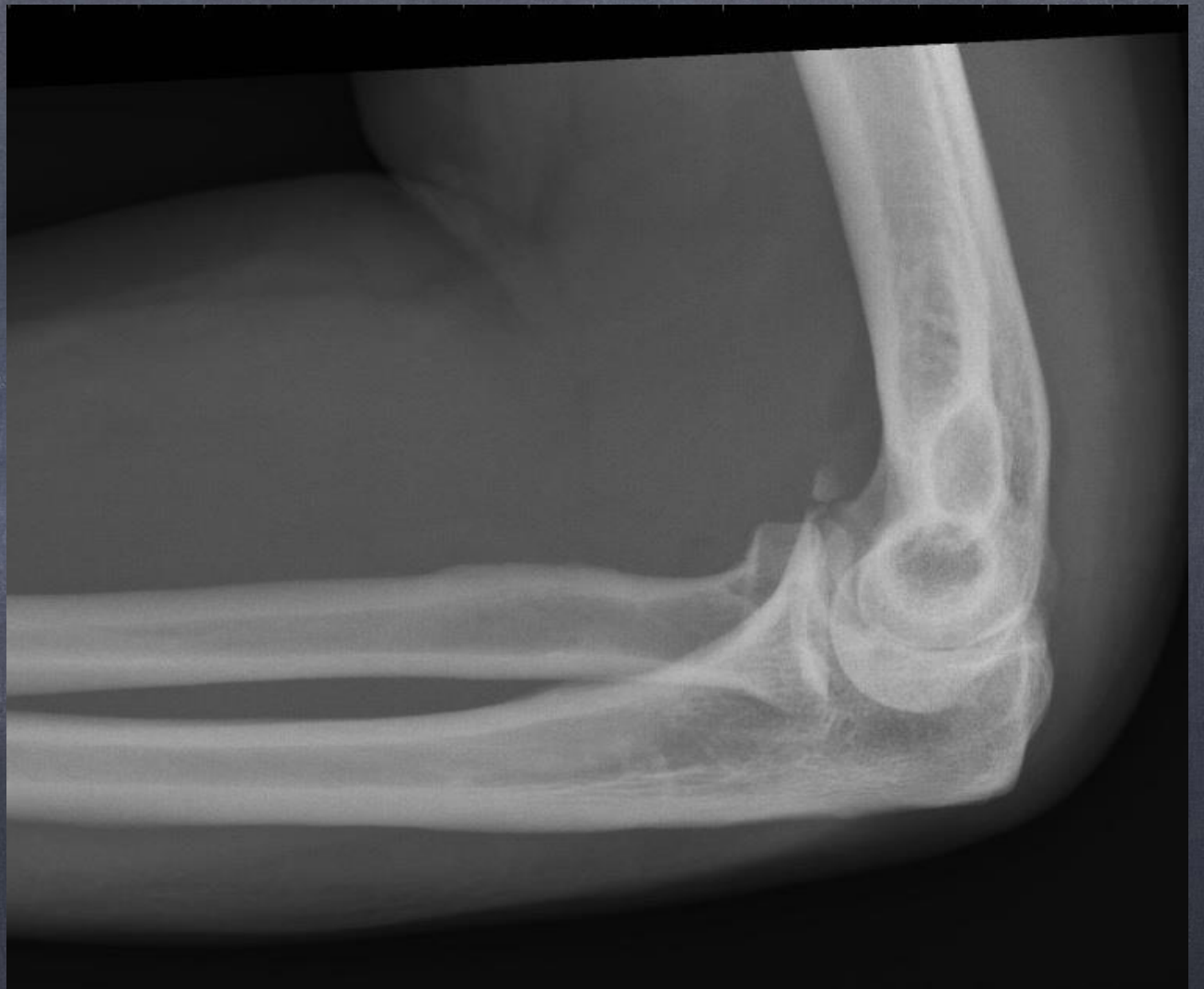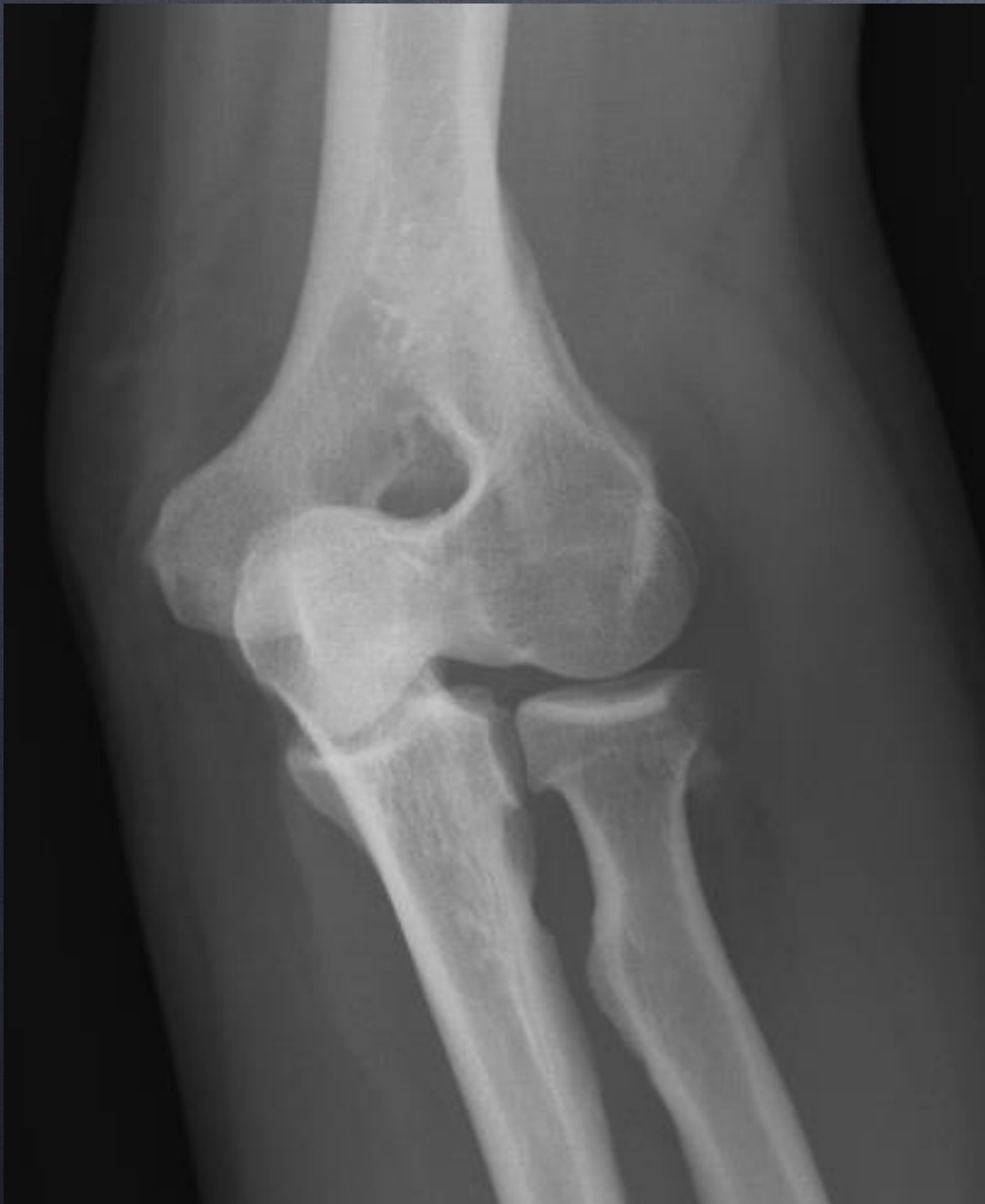Farmer

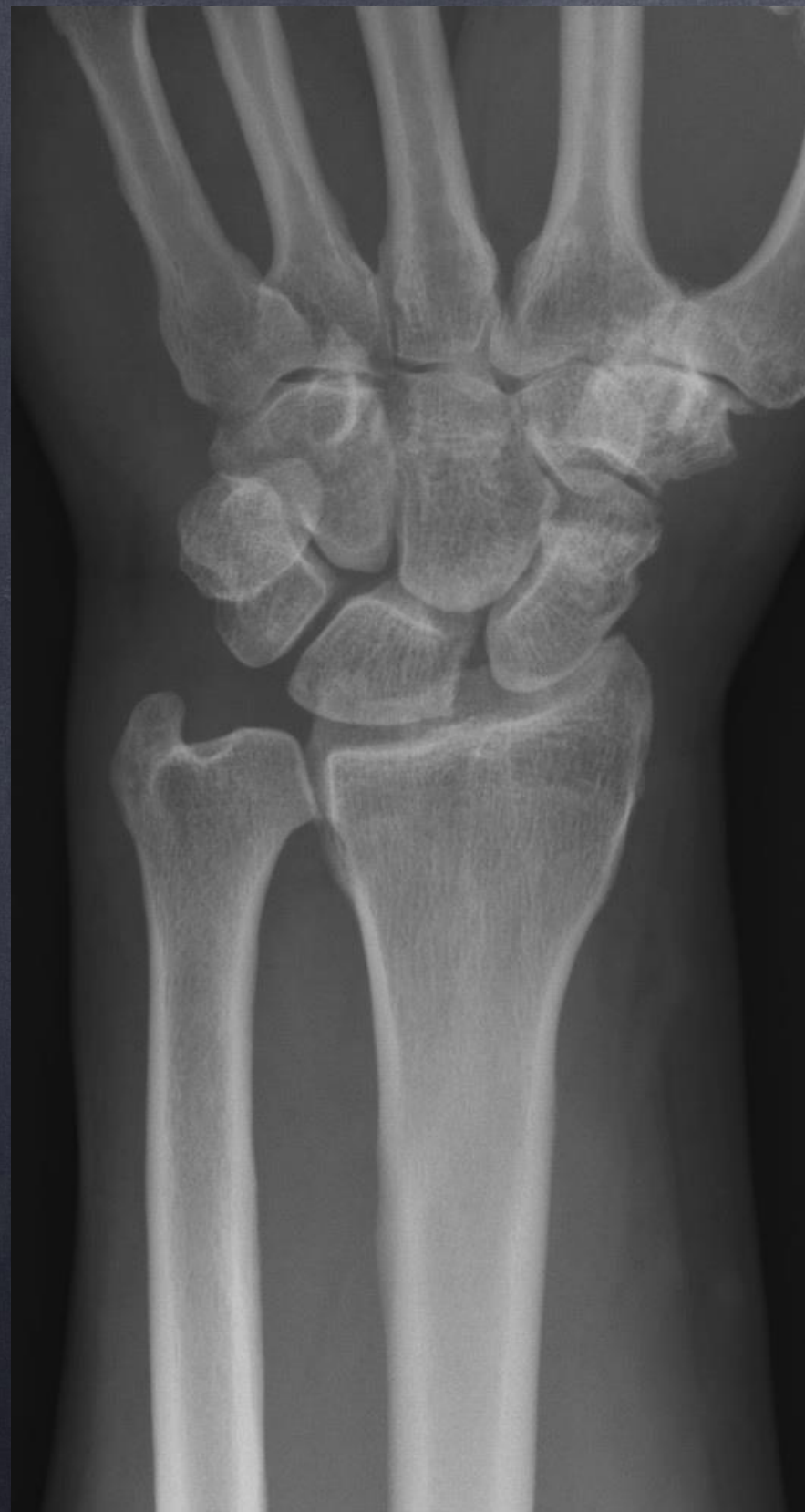Fell down 3 m

Day one

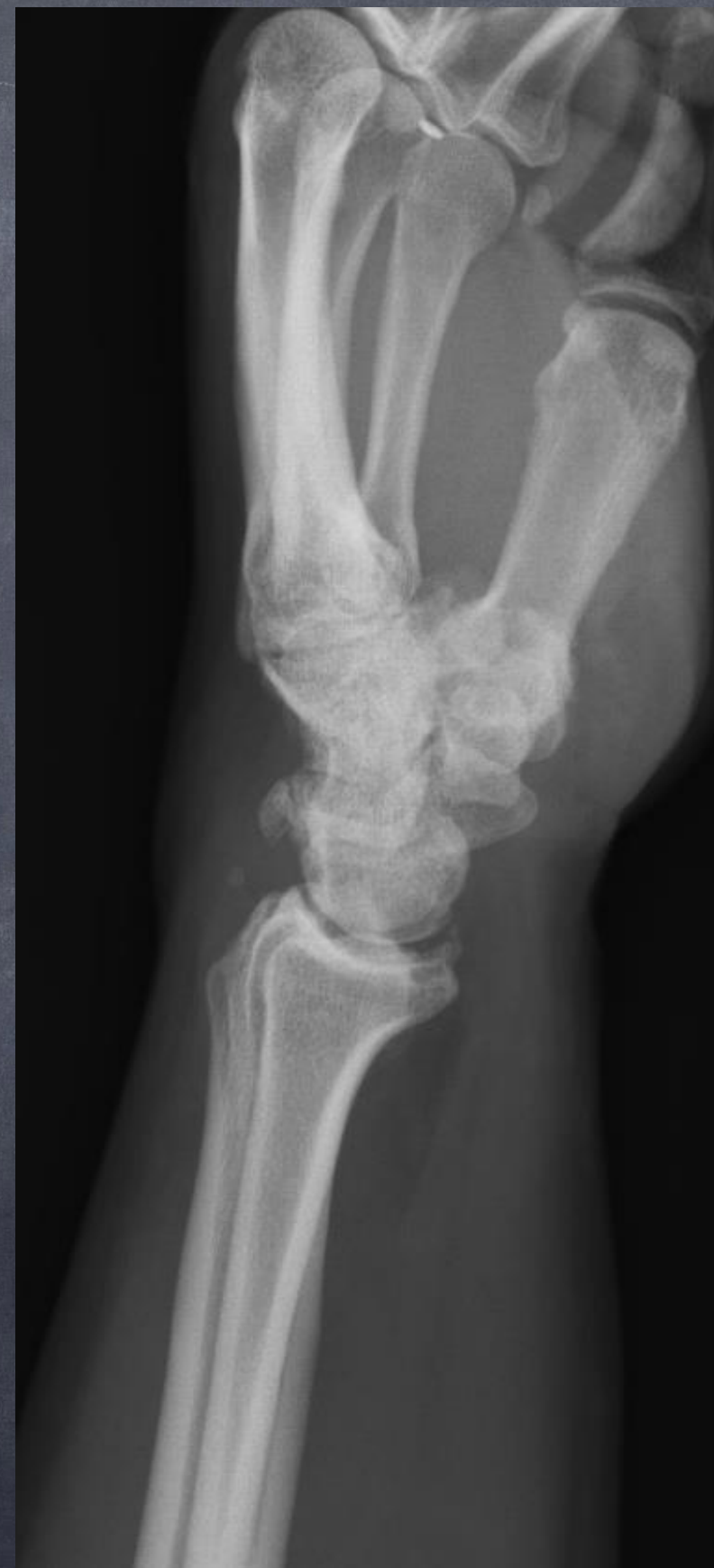Pain in elbow and wrist

Day one

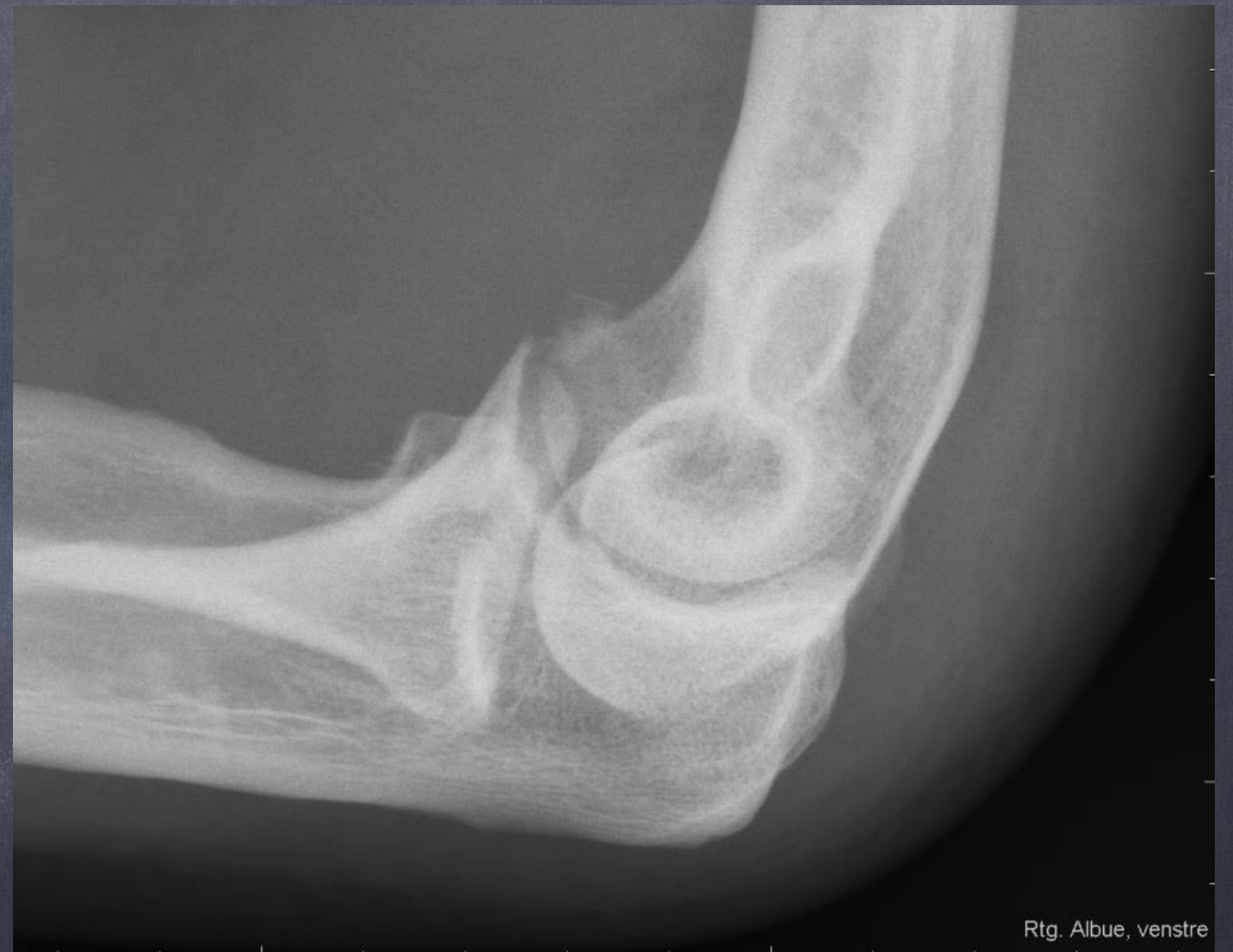
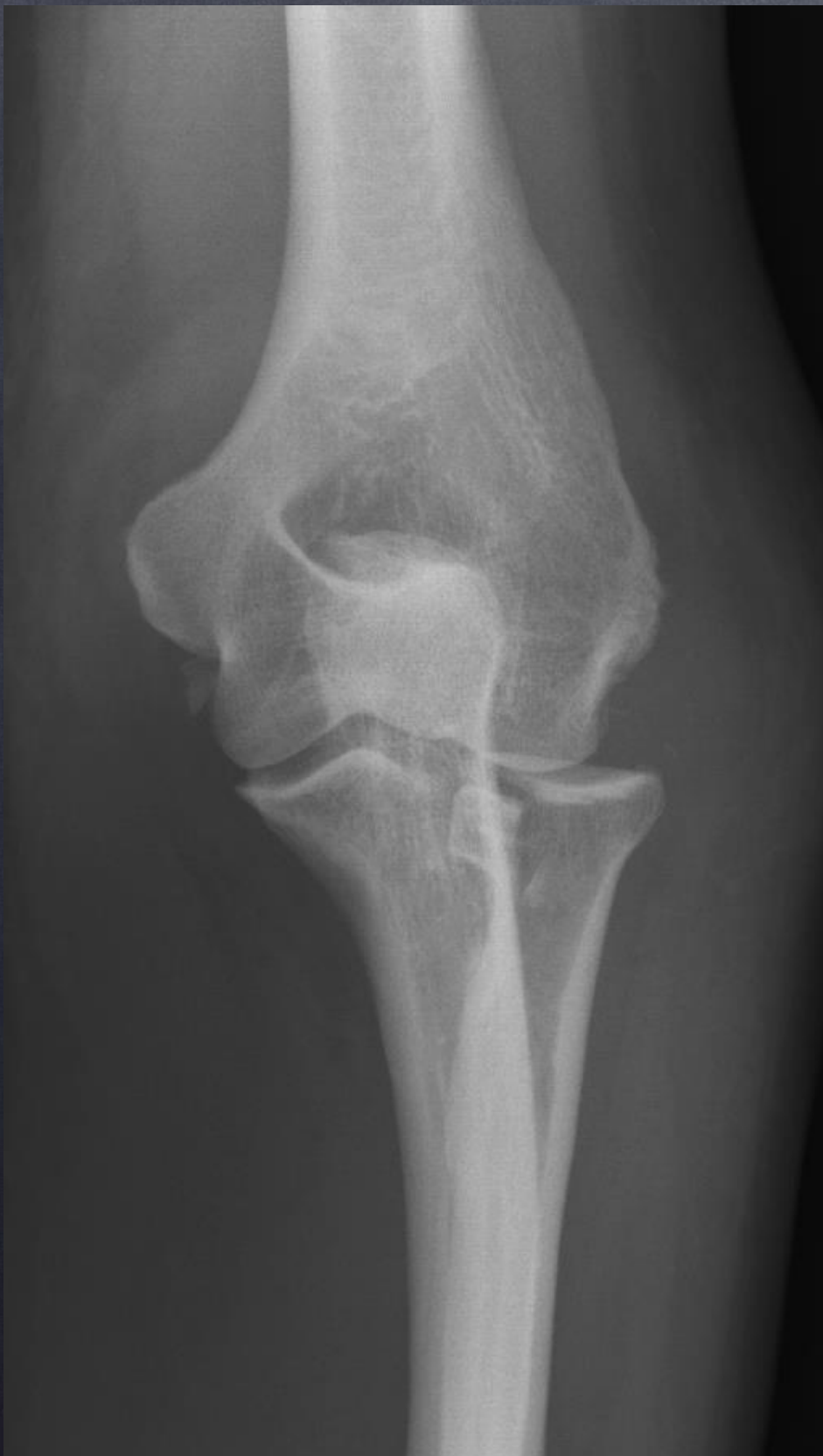


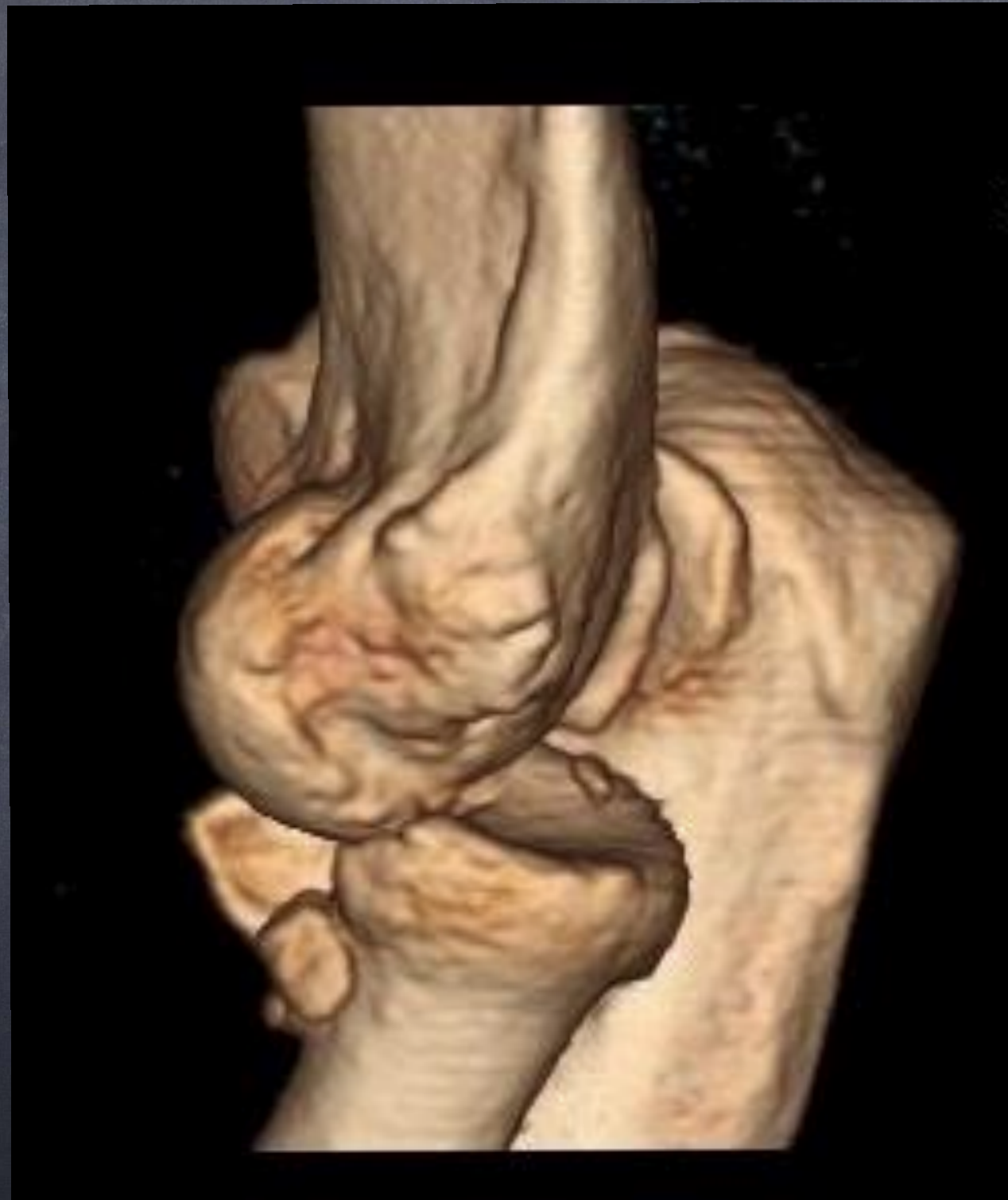Day one

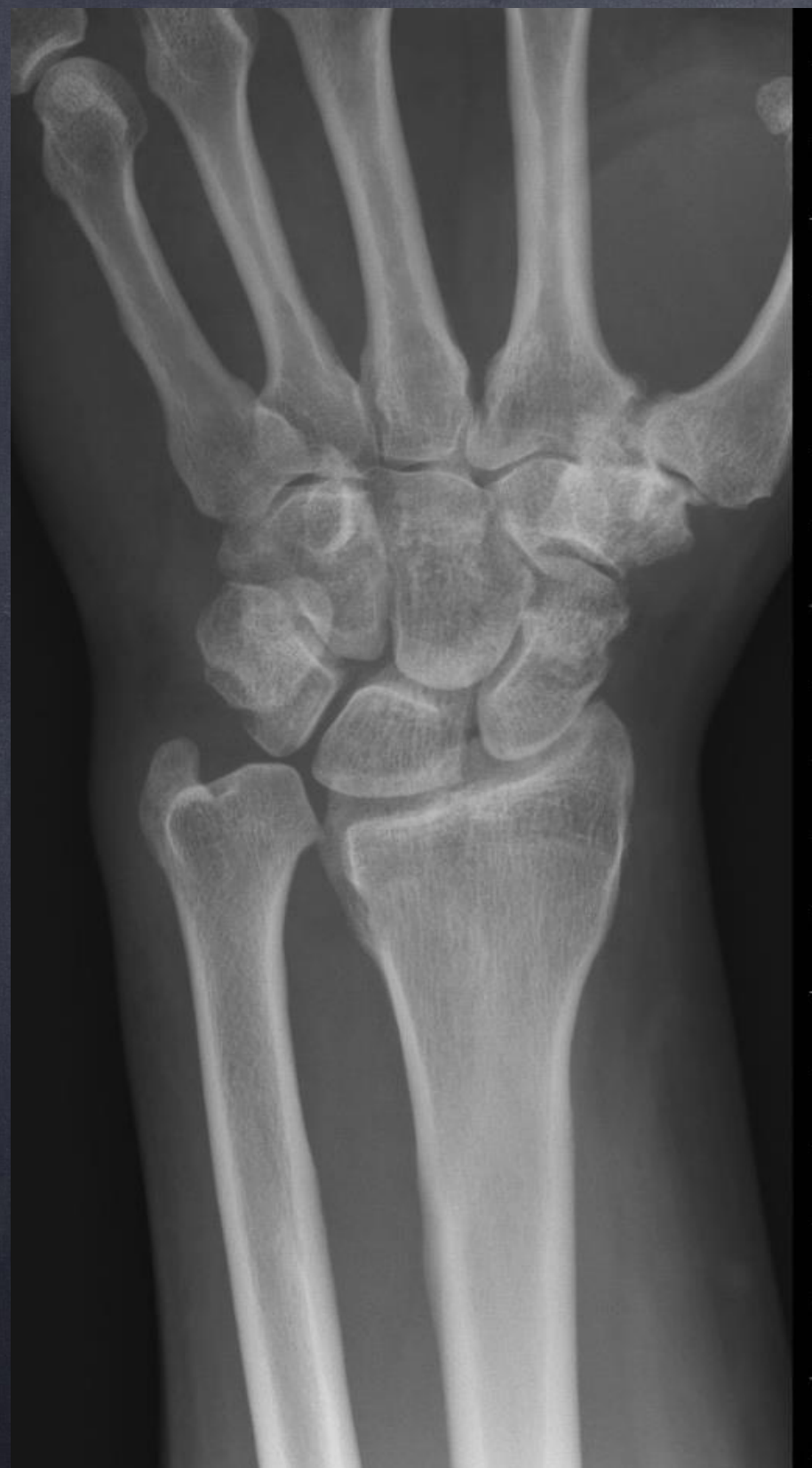

Day 30

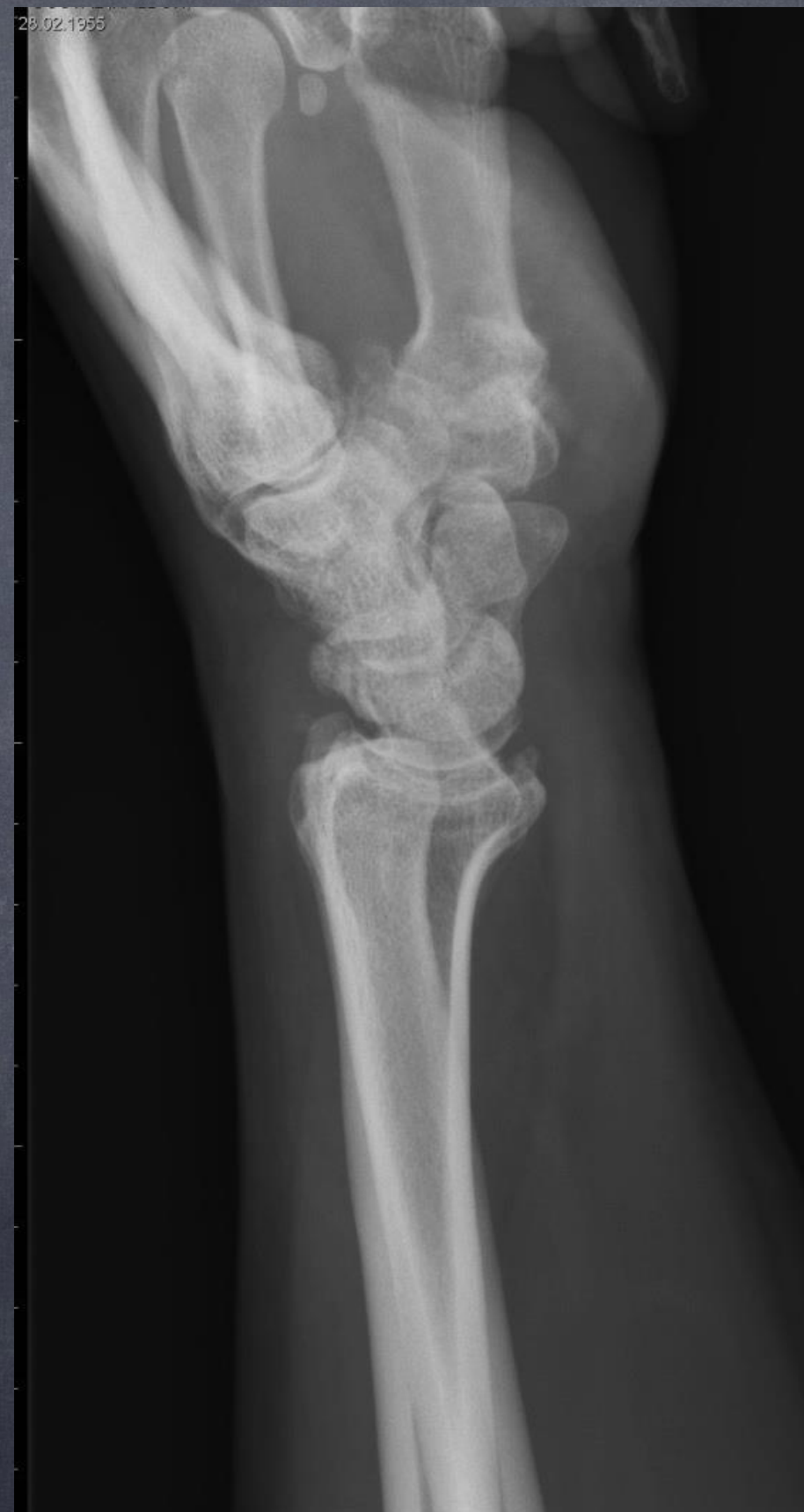

Day 31

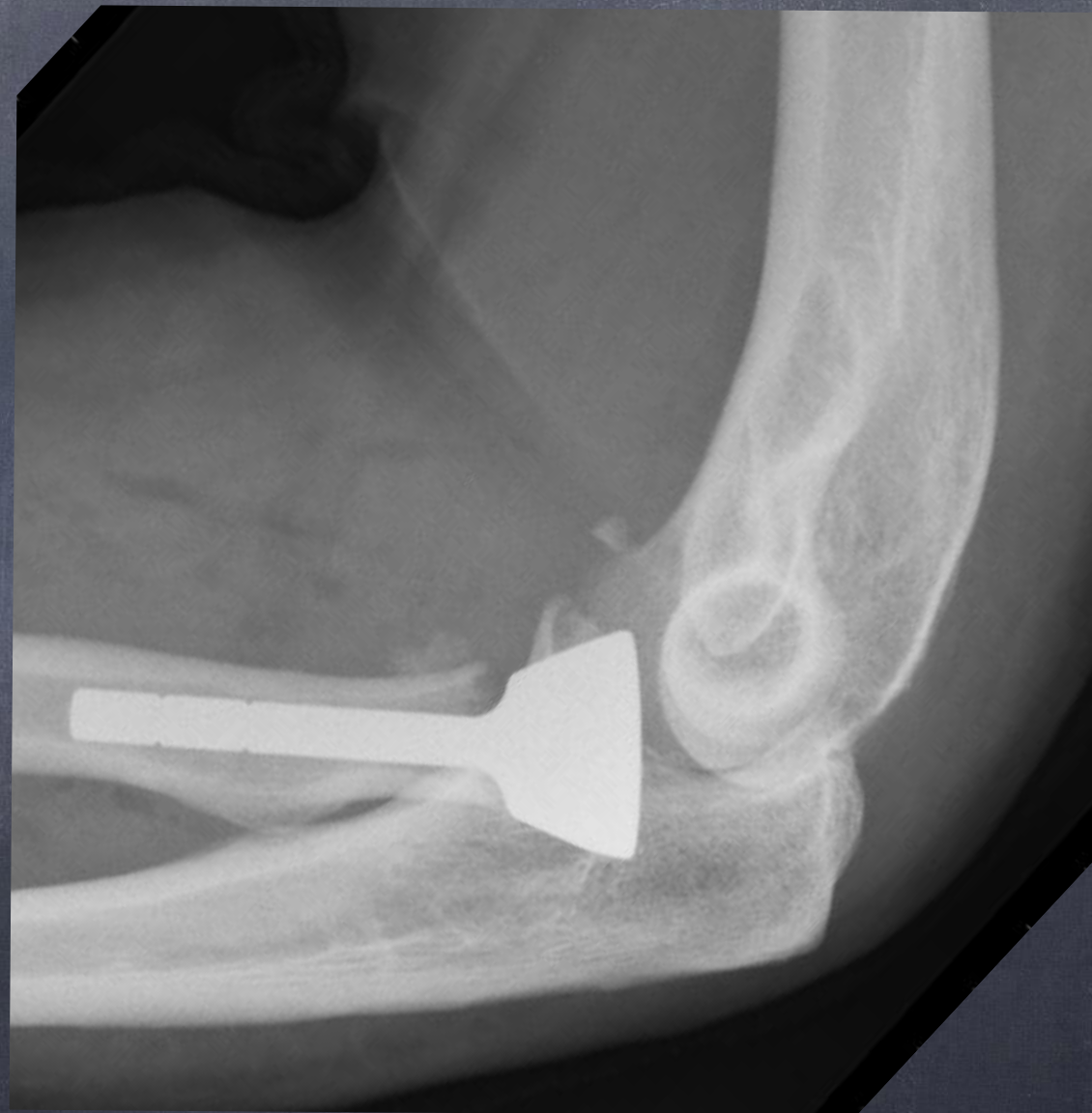
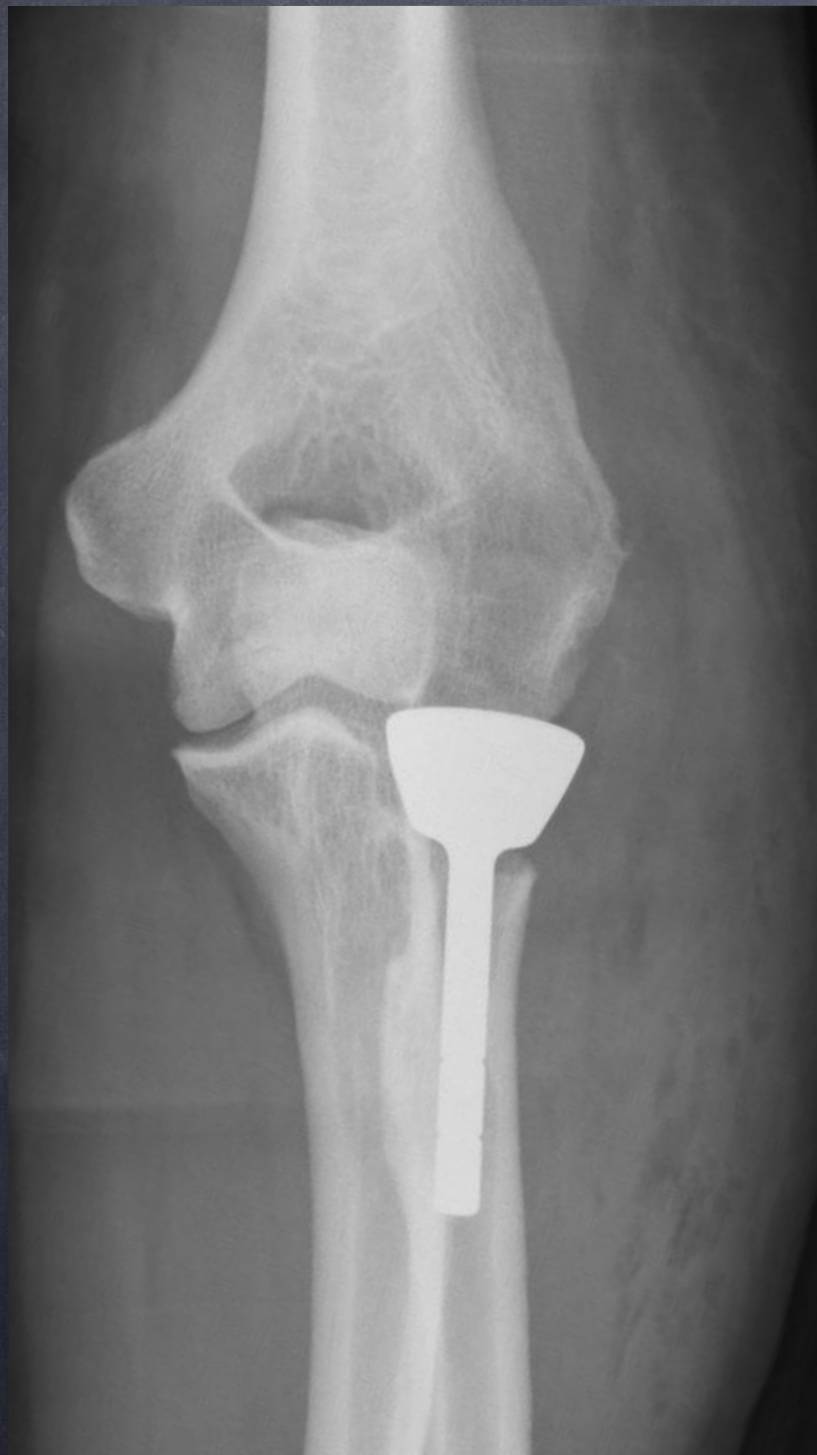



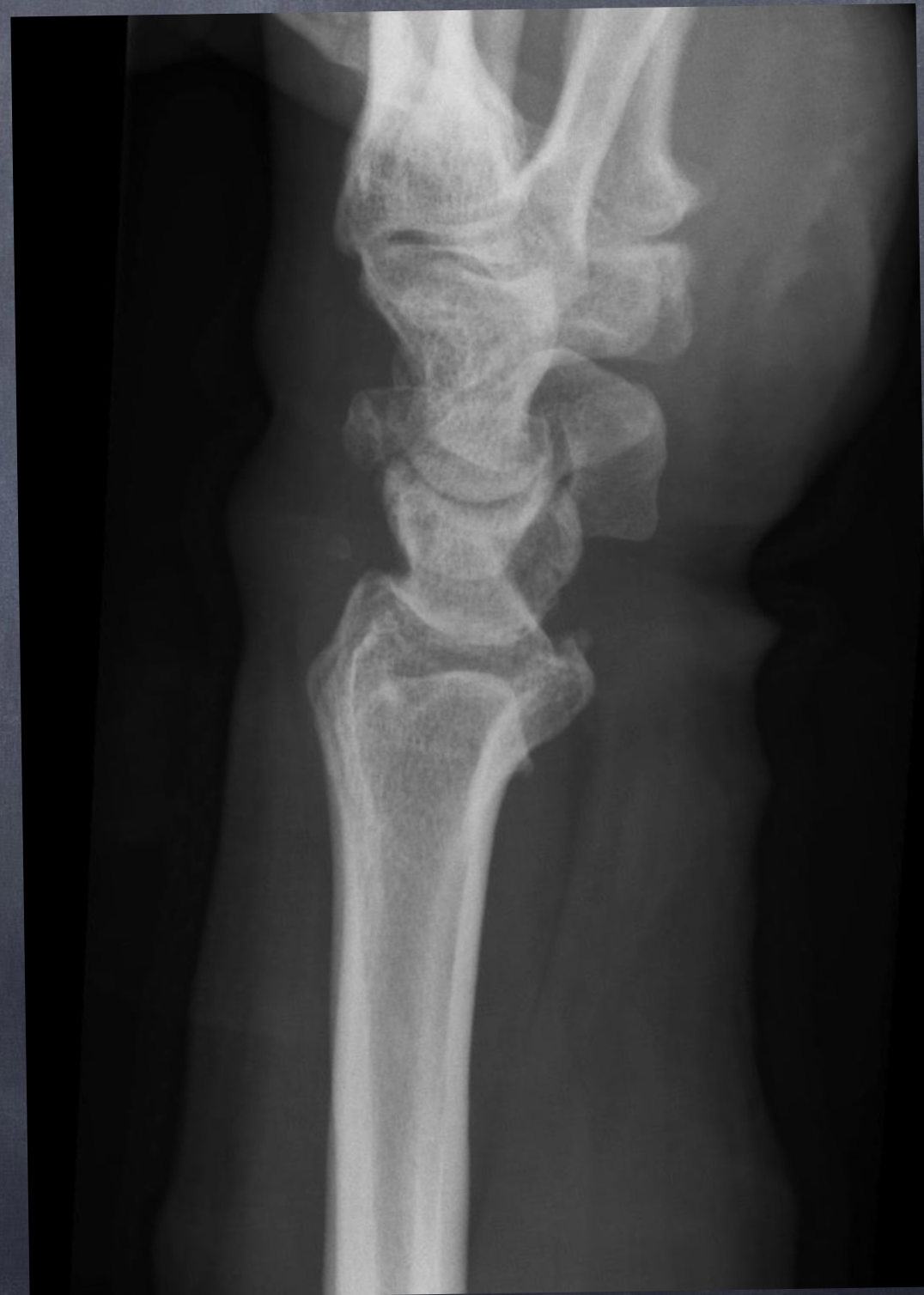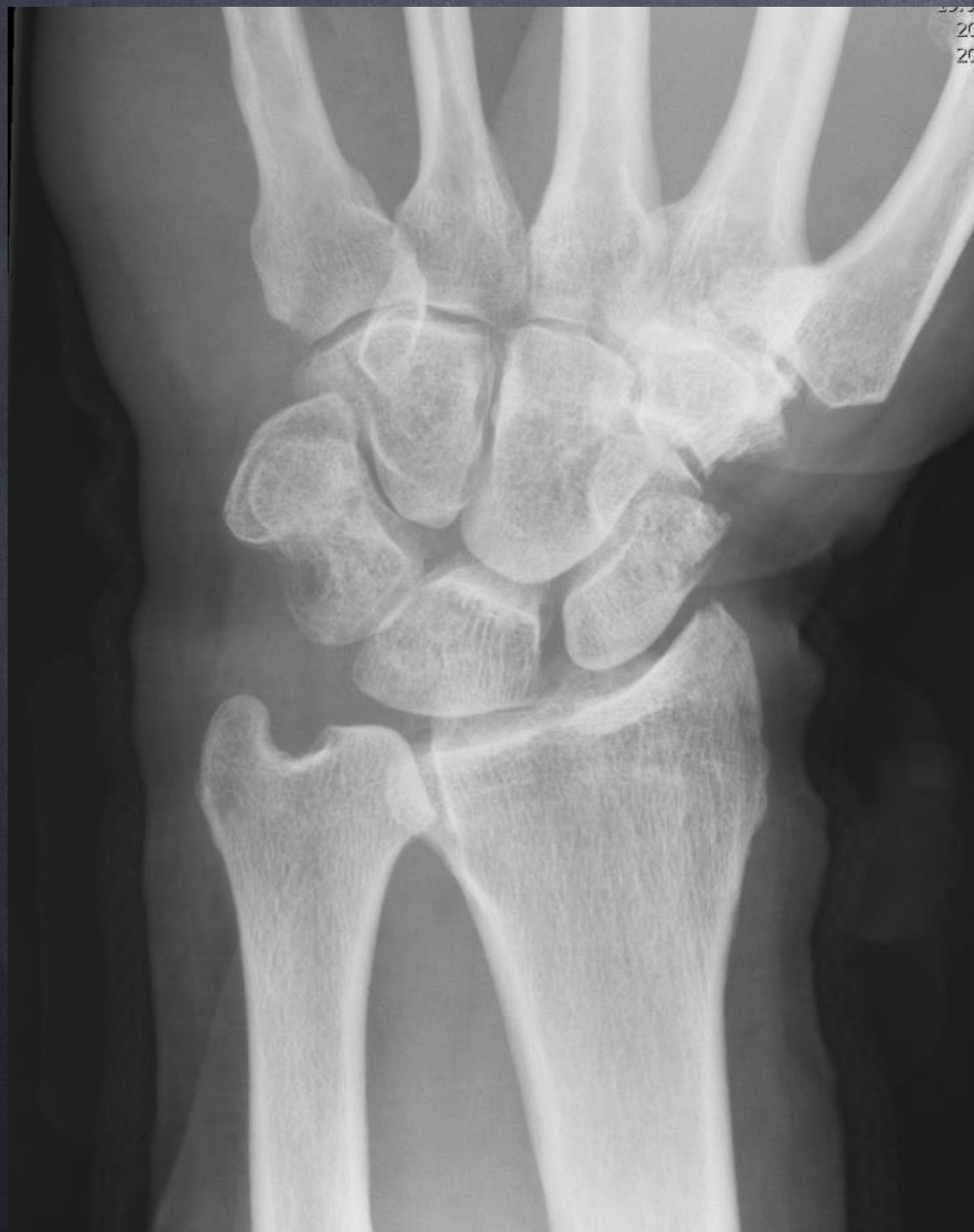Day 30



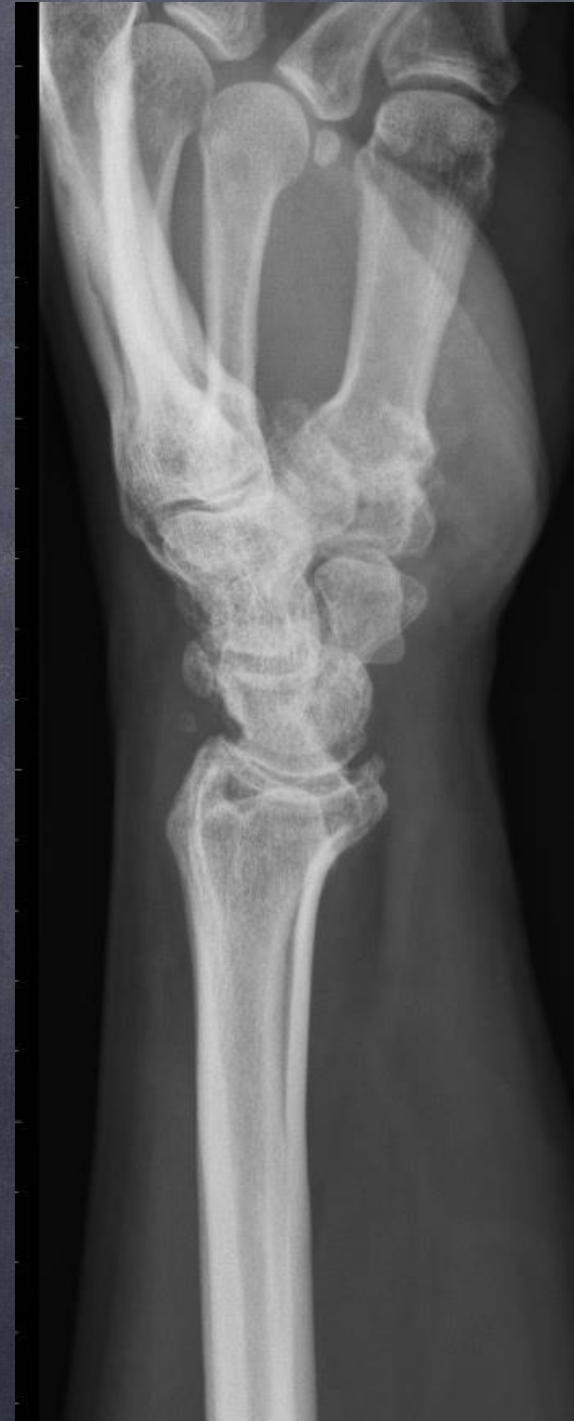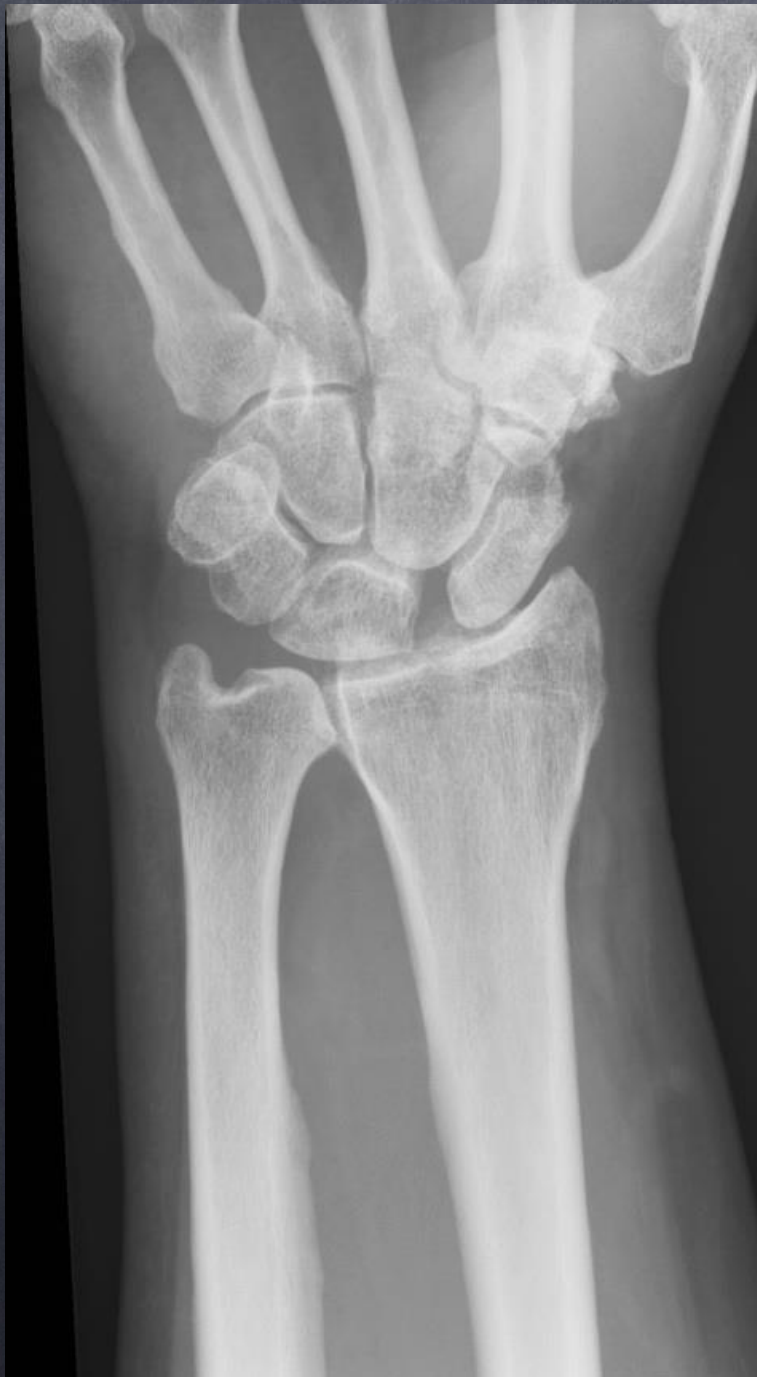Post surgery, day 40



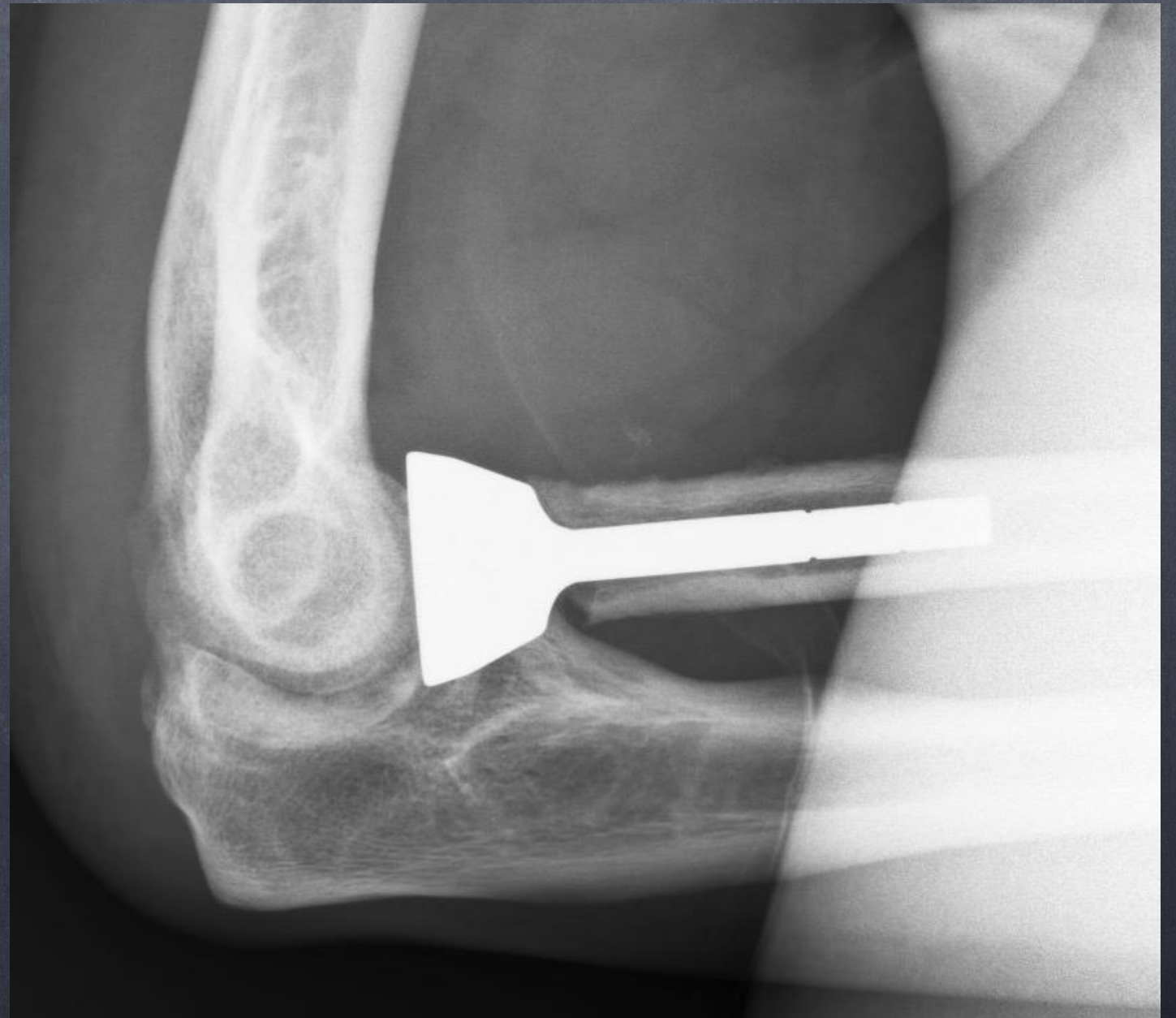
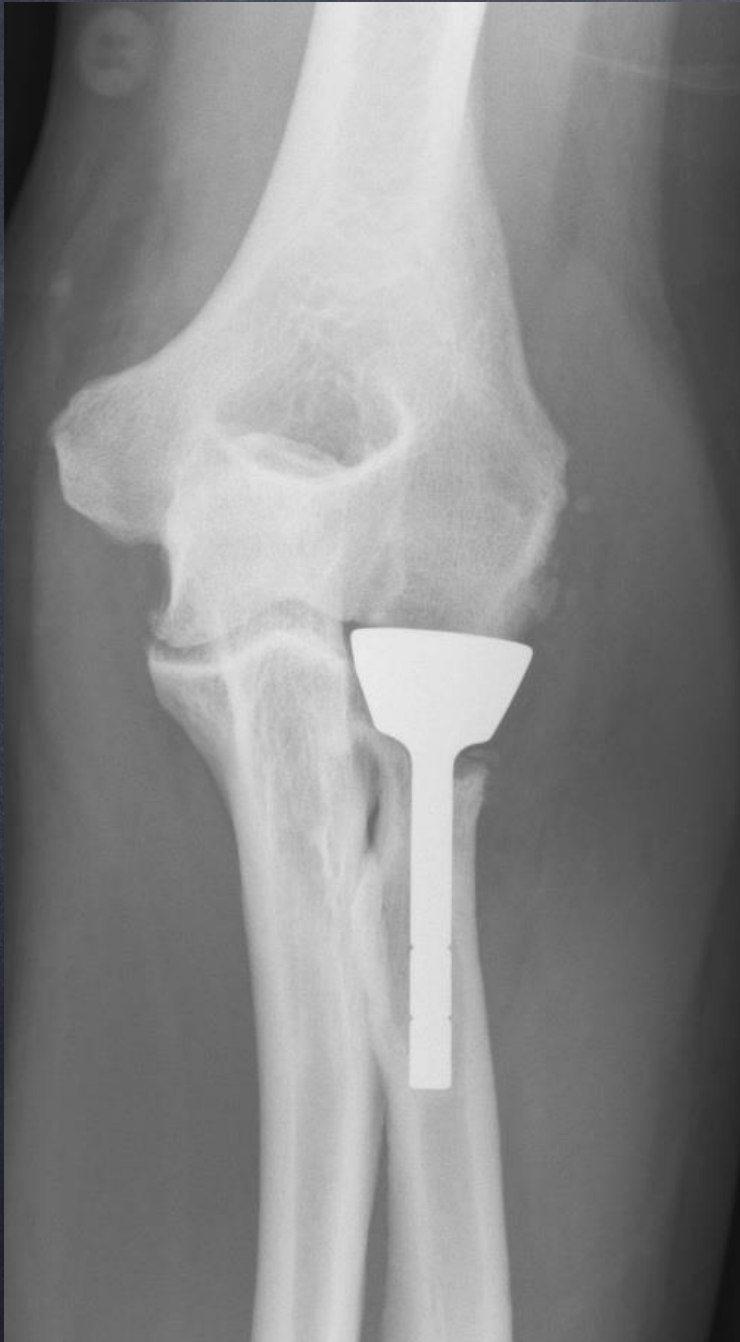Post surgery, day 40



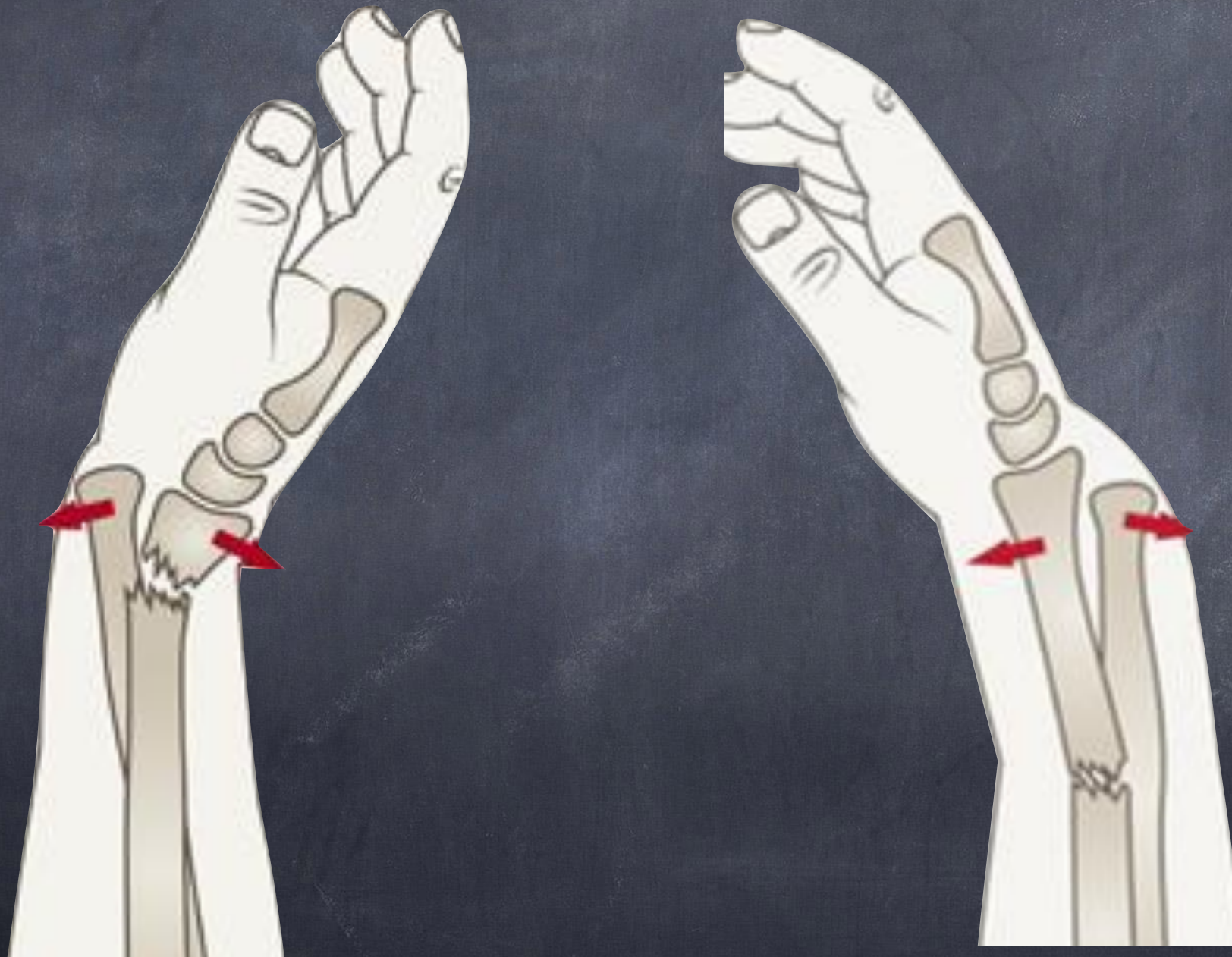
6 months post surg



6 months post surg

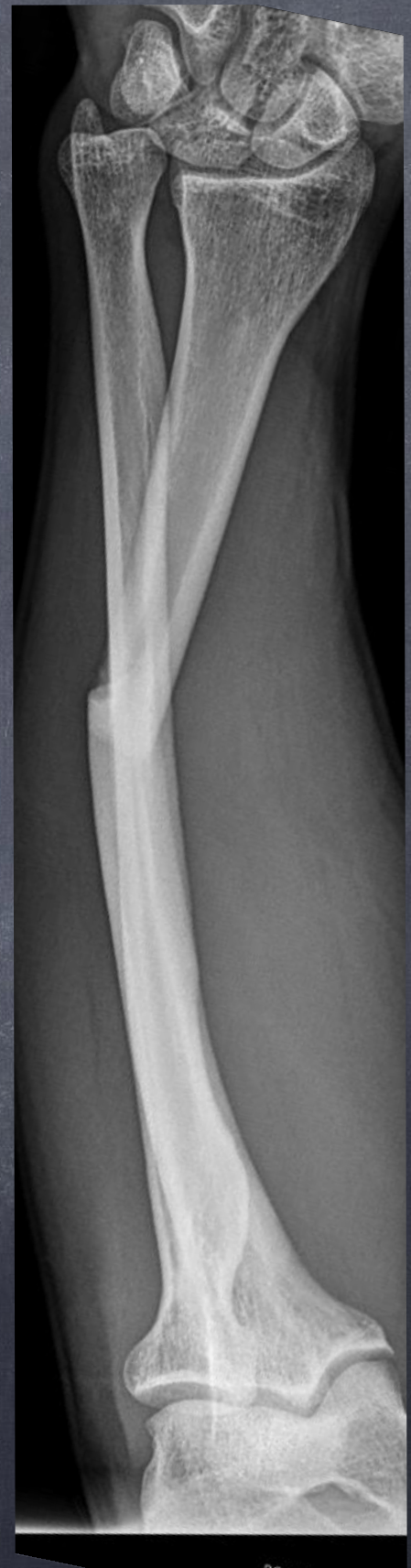
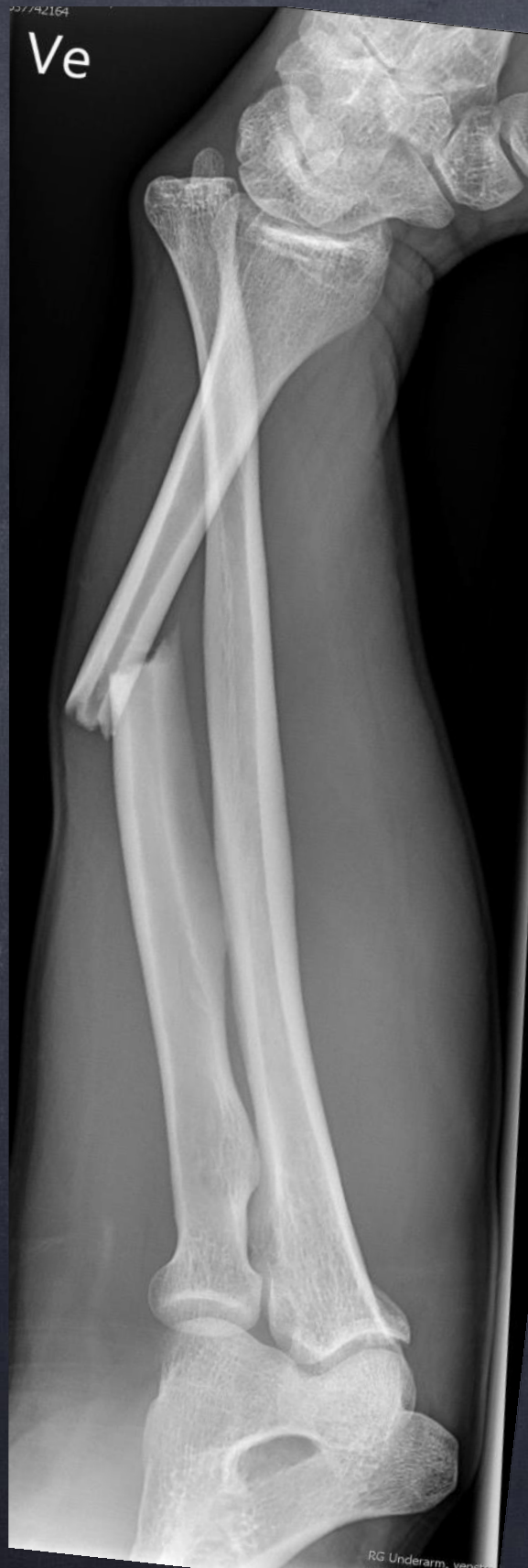
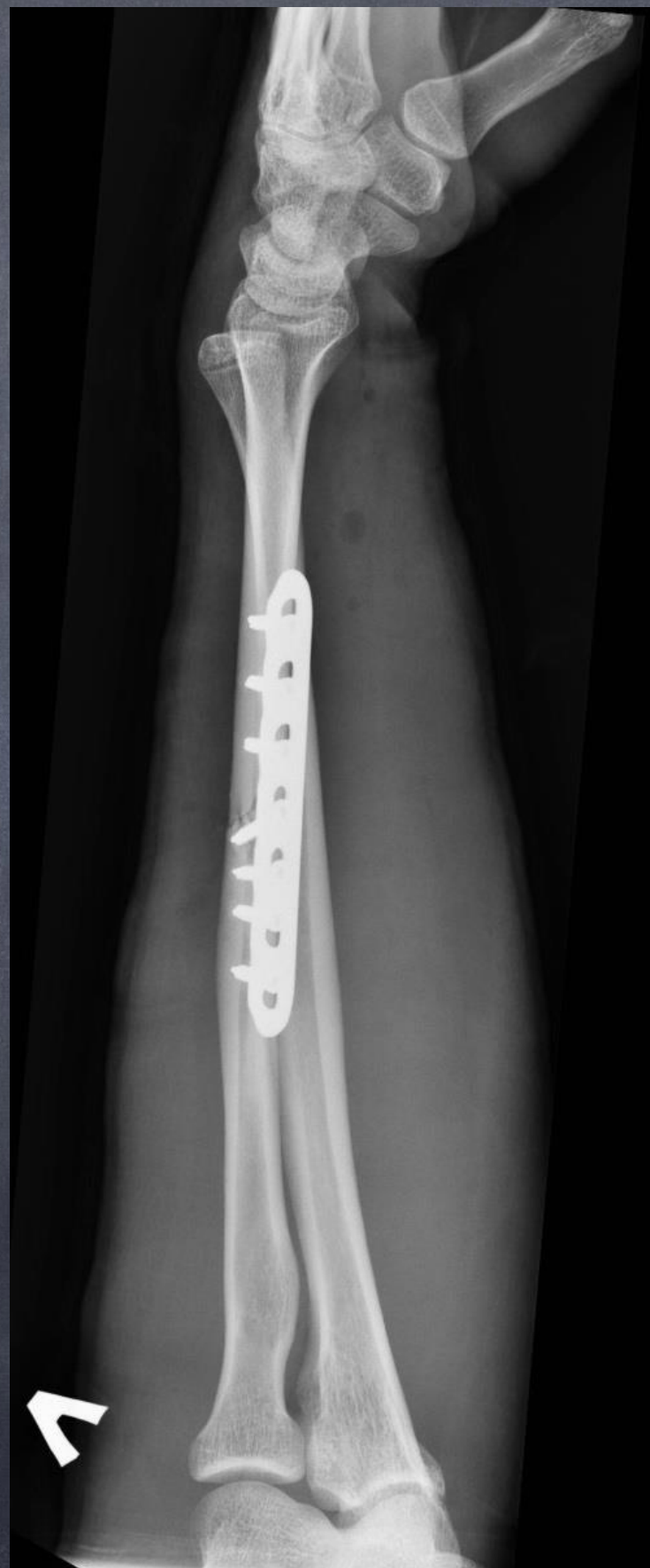
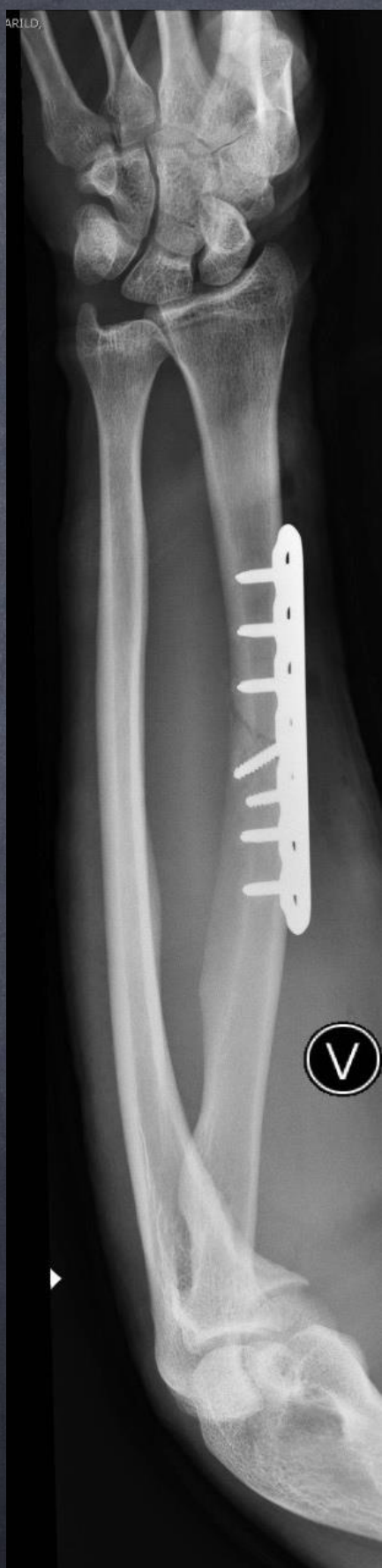Galeazzi fracture



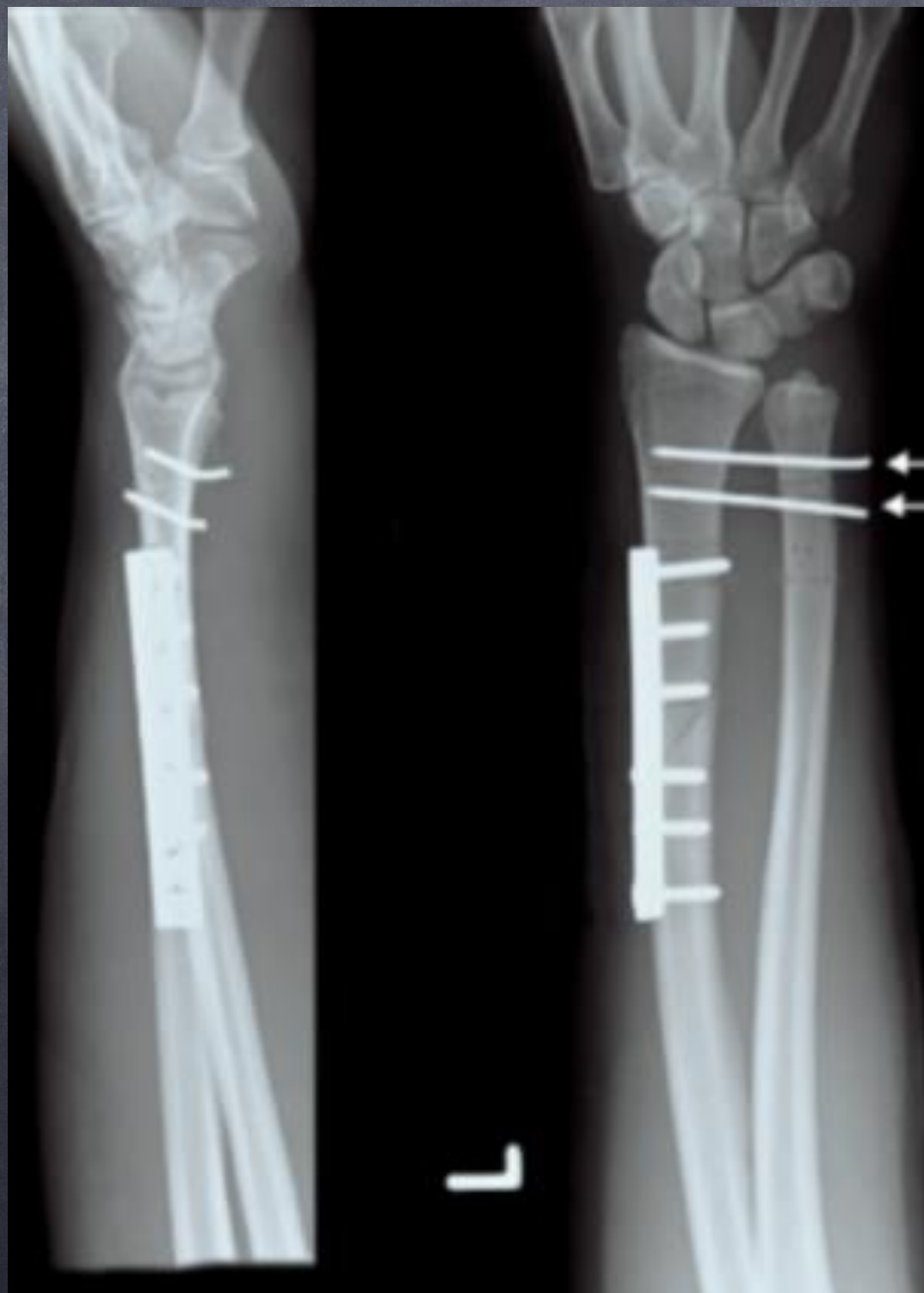Male 28

MC accident





Galiazzi



Monteggia fractures



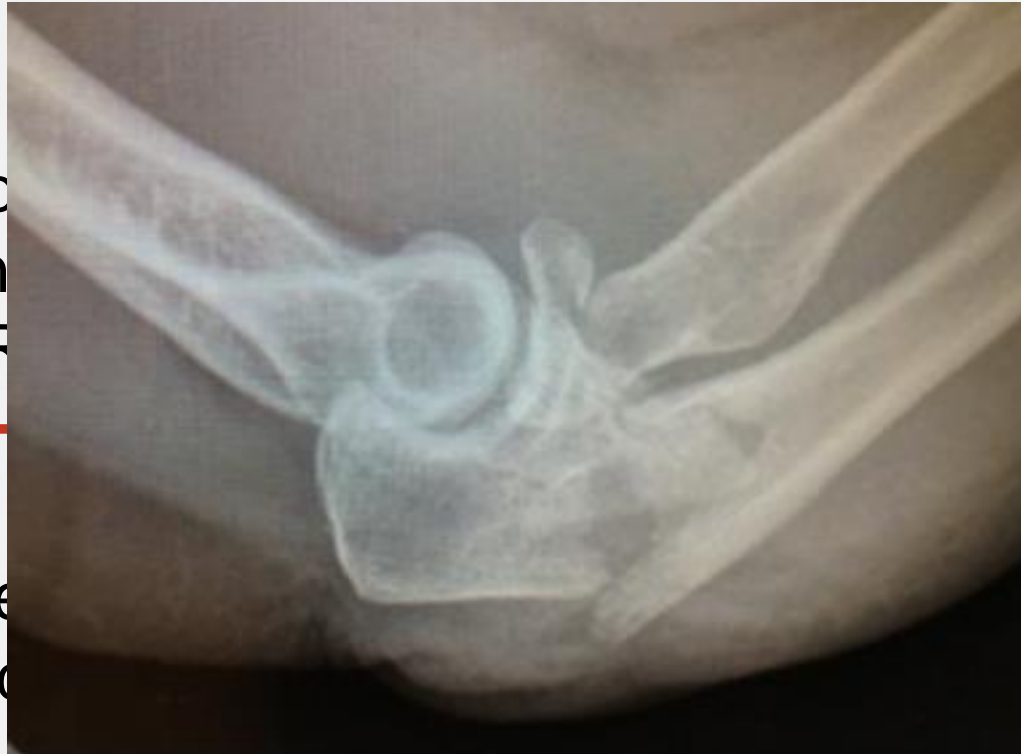Ring Classification

Ap
an
PF

Me
rac

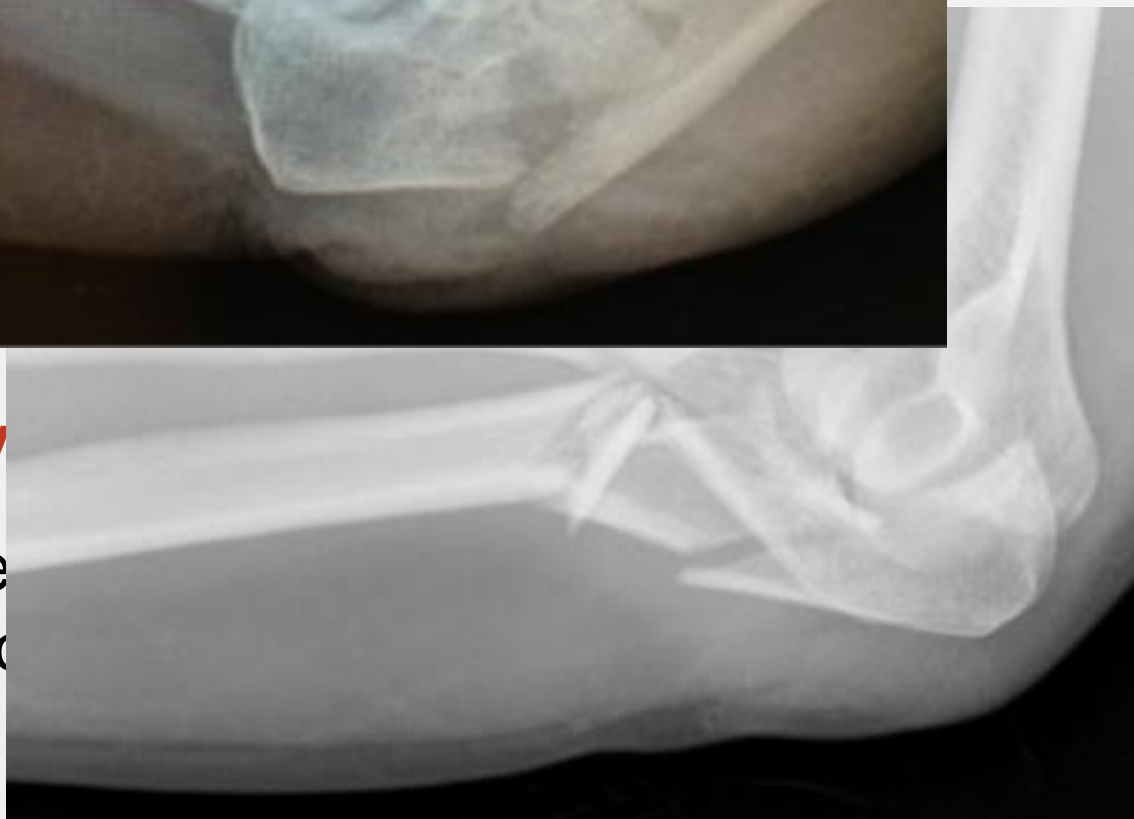Ty

Ape
disl



e with
ellar and

eral
(ren)

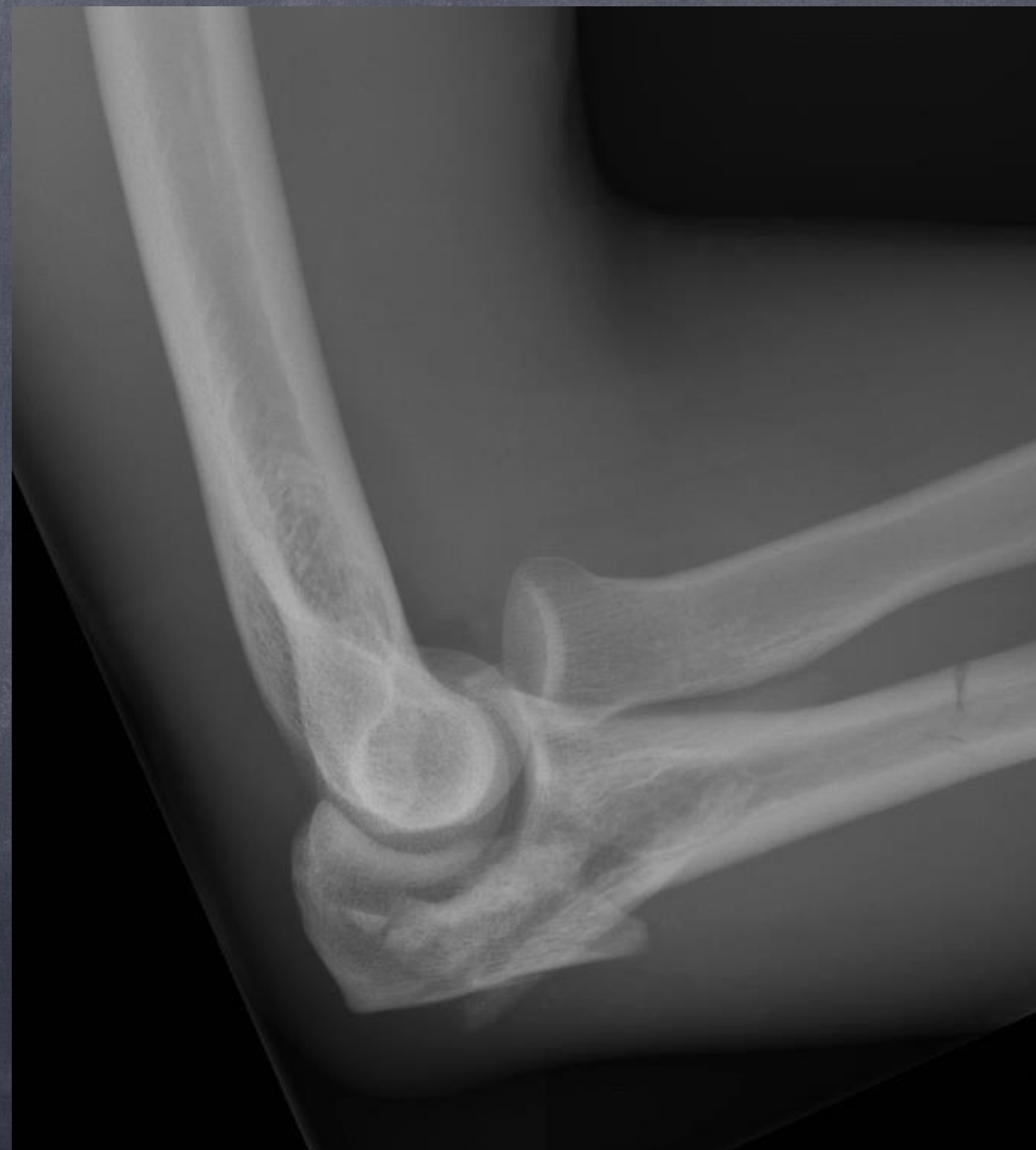
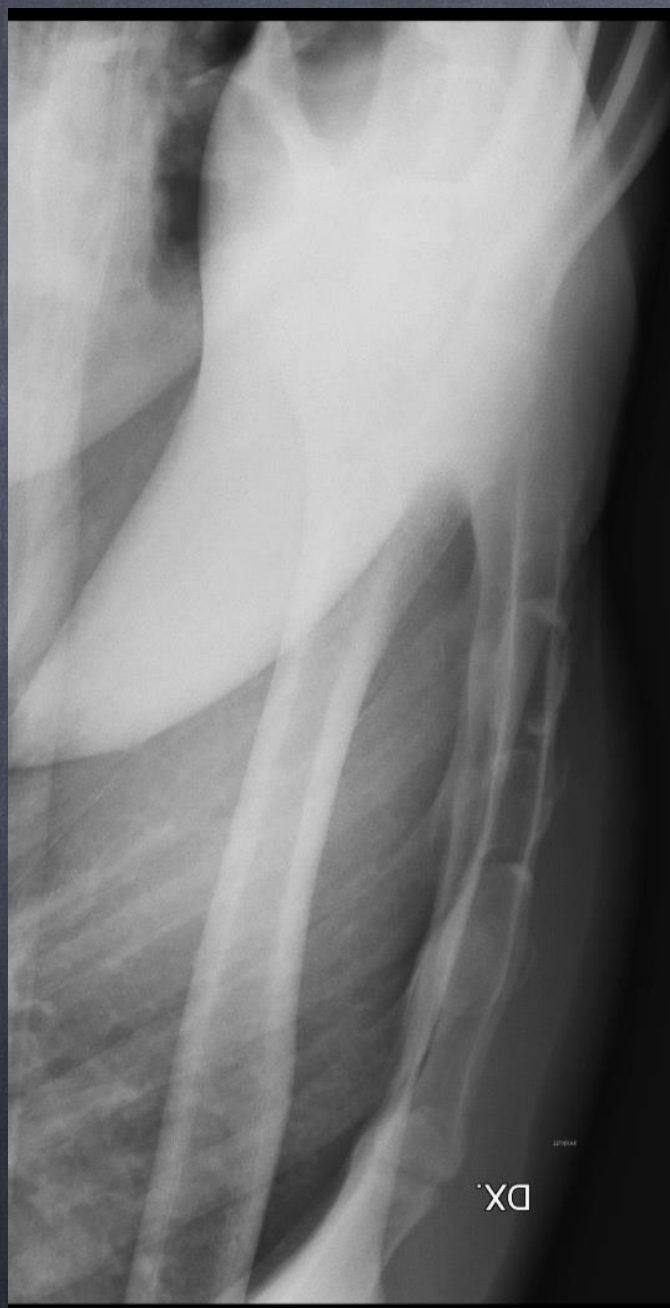
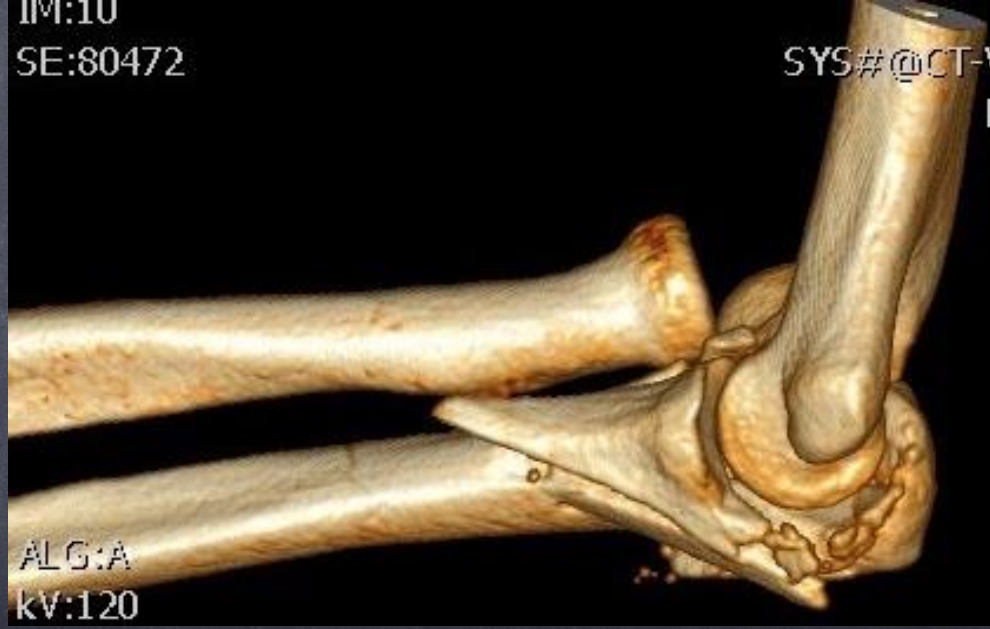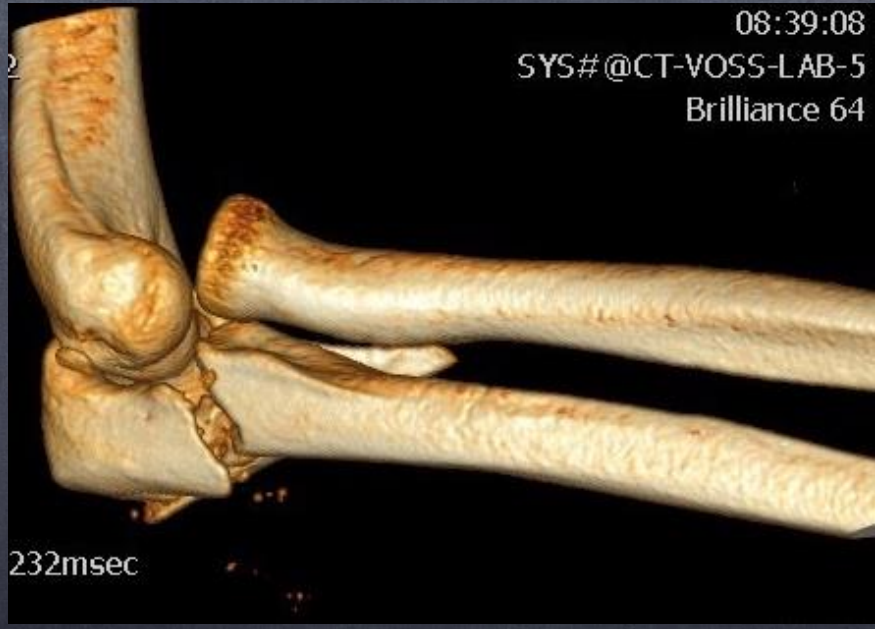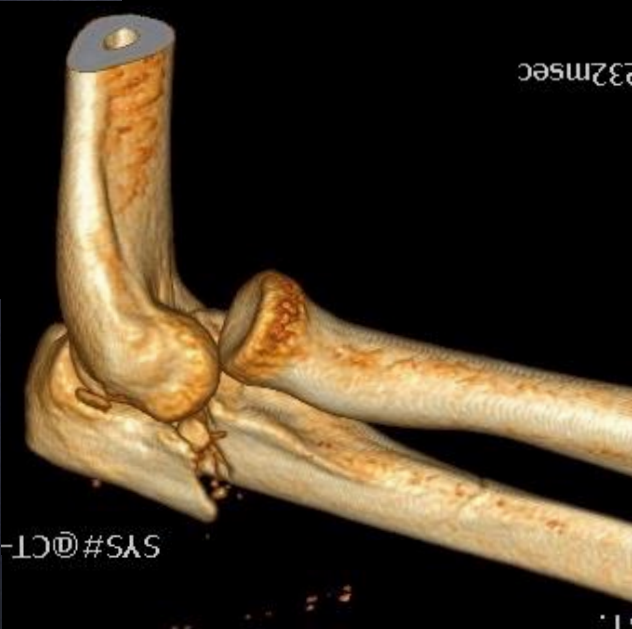Male 32

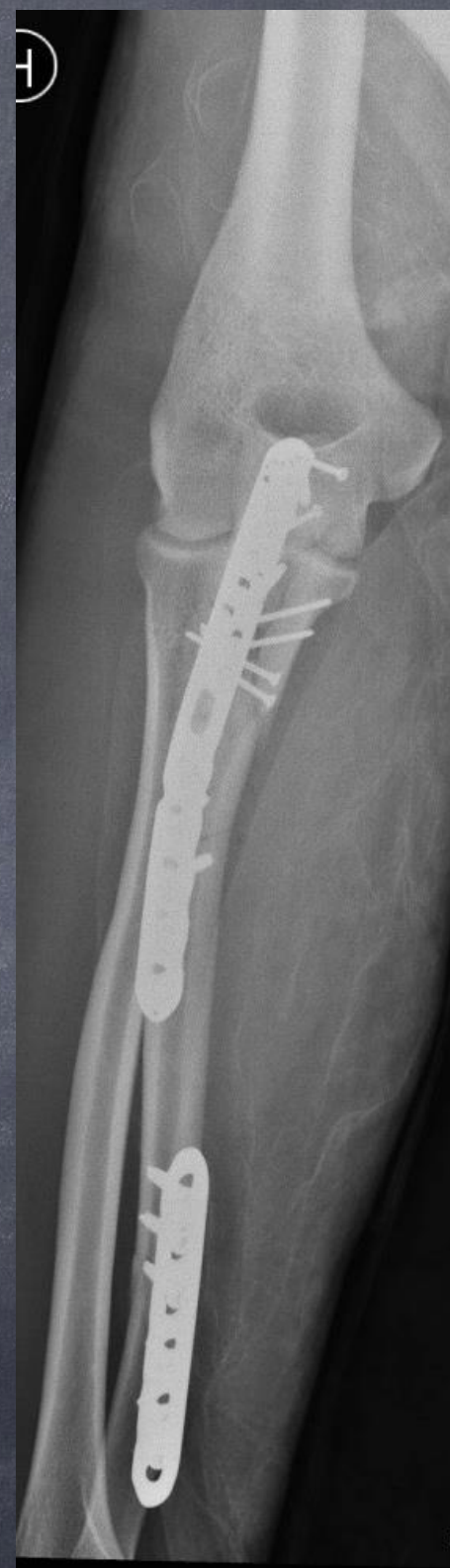
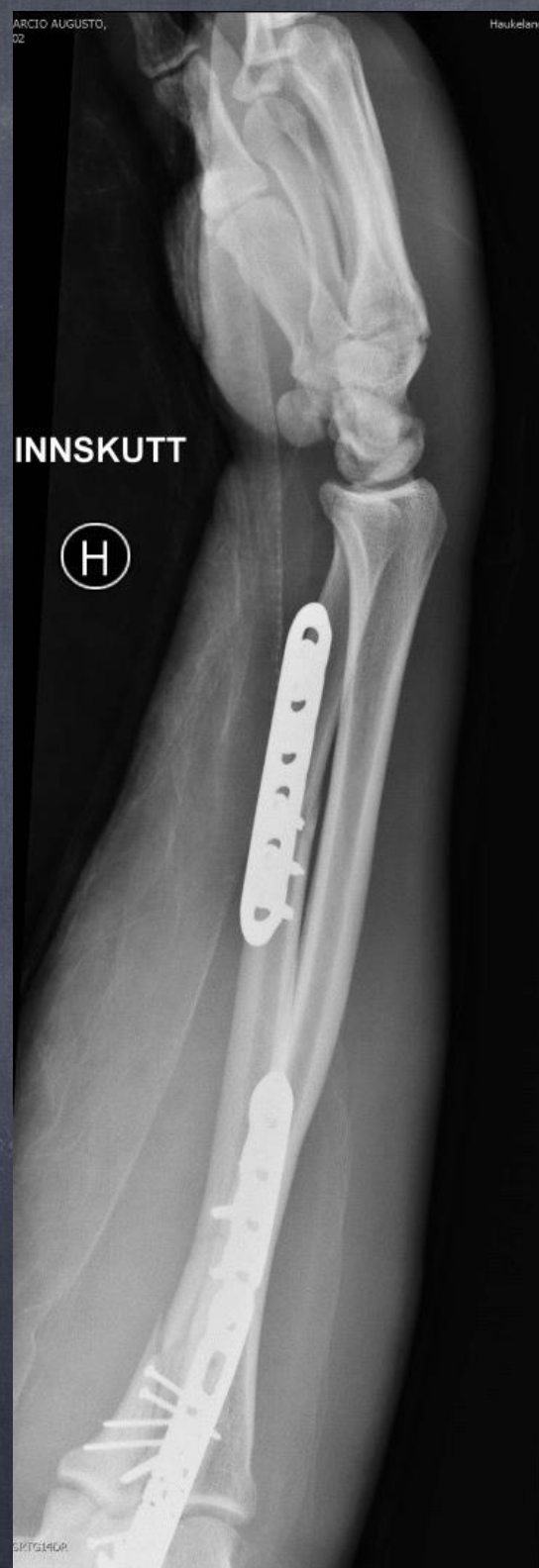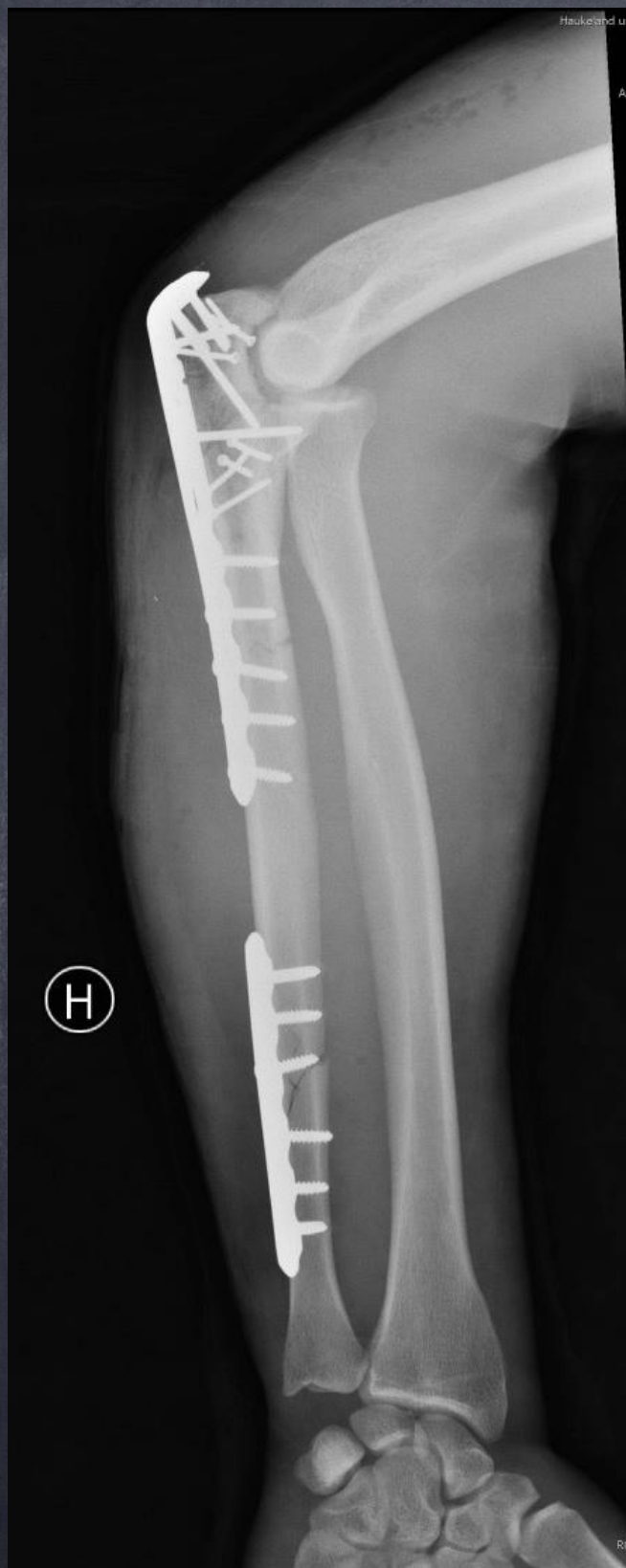Speed skiing & parachute



Monteggia







Tank You