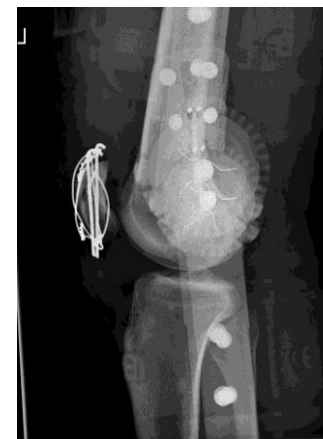
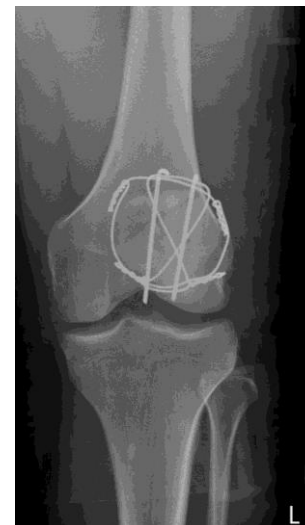
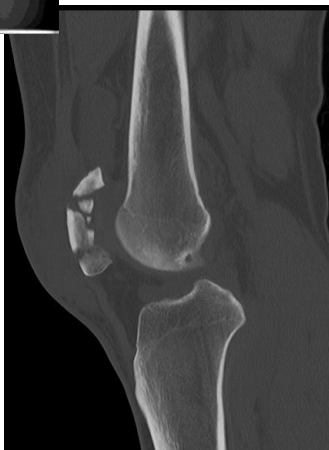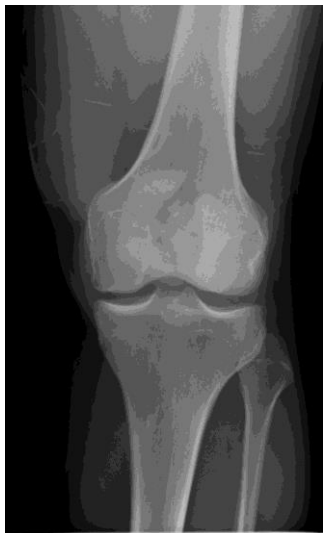Patellafrakturer

AO Basic Danmark 2019



INDHOLD (15 min.)

- Epidemiologi/traumemekanisme
- Klassifikation
- Behandling
- Komplikationer
- Fremtiden
- Take-home messages

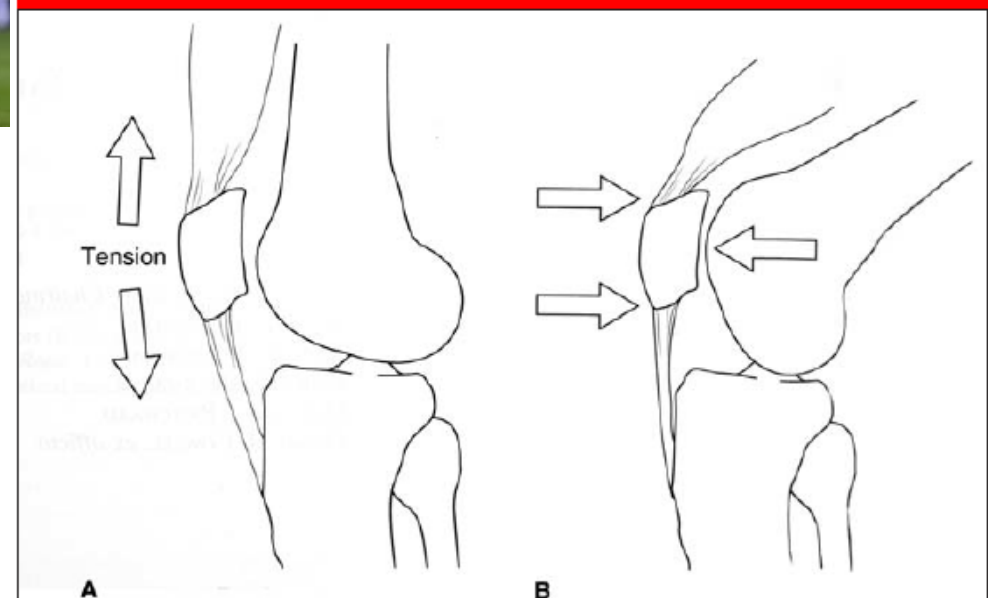


Epidemiologi

- Ca. 1% af alle frakturer
- En udsat knogle, grundet placering og biomekanik
- Direkte traume er hyppigst
- Ca. ½ er udislocerede med bevaret ekstensorapparat



Figure 3









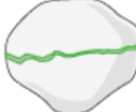

A, The patella is loaded primarily in tension with the knee in full extension. B, During flexion, the patella experiences a combination of tension, compression and three-point bending forces (arrows). (Reproduced with permission from Carpenter JE, Kasman R, Matthews LS: Fractures of the patella. *J Bone Joint Surg Am* 1993;75:1550-1561.)

Klassifikation

Tager udgangspunkt i:

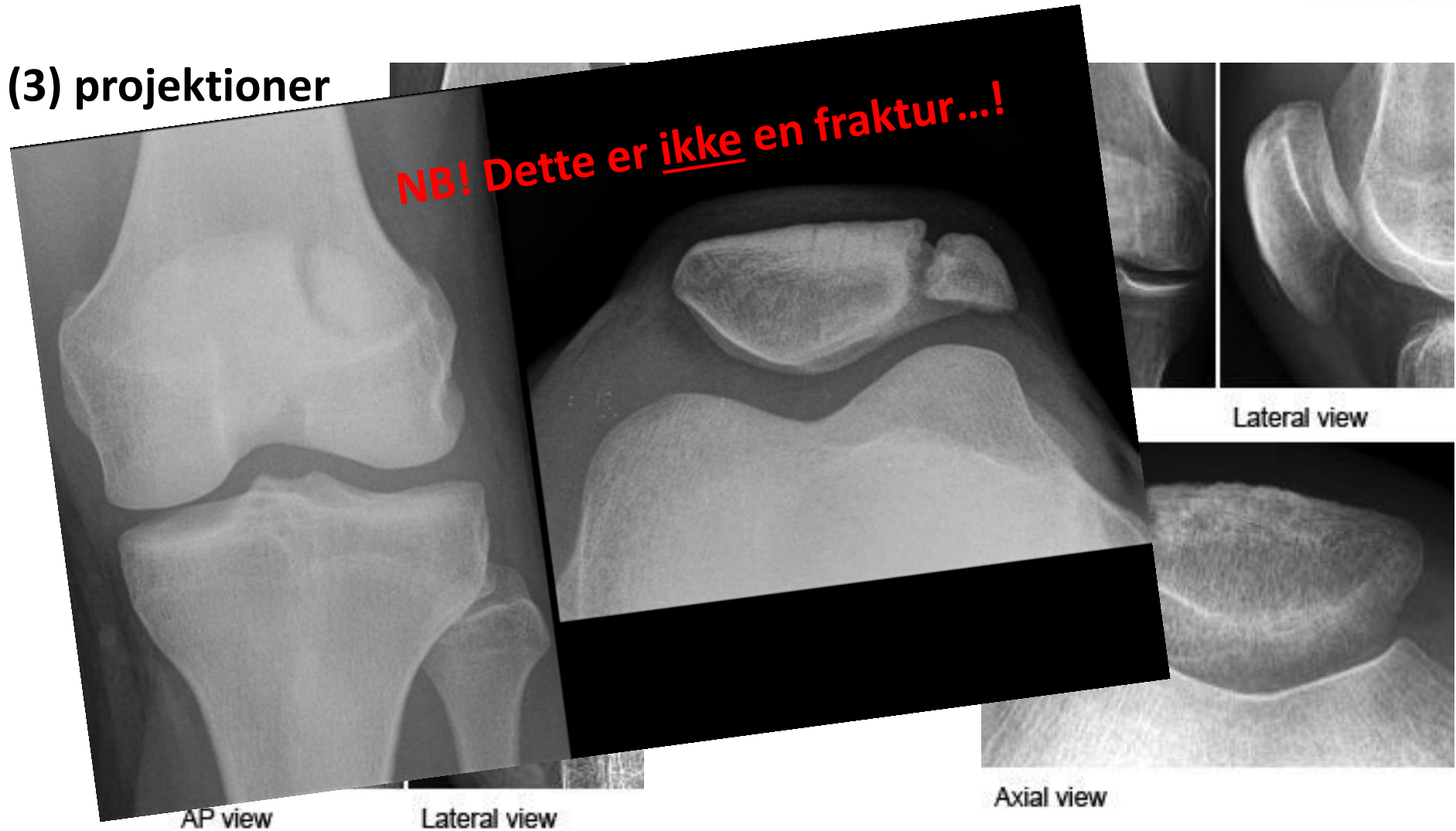- **Disloceret / ikke disloceret**
- **Type:** Transvers, vertikal, avulsjoner, komminutte, osteokondrale
- **Placering:** Centrale, proksimale, distale

AO/ OTA Classification

| | | | |
|--|--|--|--|
| Extra articular  | 34-A1 avulsion  | 34-A2 isolated body  | |
| Partial articular  | 34-B1 vertical, lateral  | 34-B2 vertical, medial  | |
| Complete articular  | 34-C1 transverse  | 34-C2 transverse plus second fragment  | 34-C3 complex  |

Diagnostik

Røntgen – 2 (3) projektioner



Behandling

Målet er at genskabe:

- Ekstension
- Ledflade

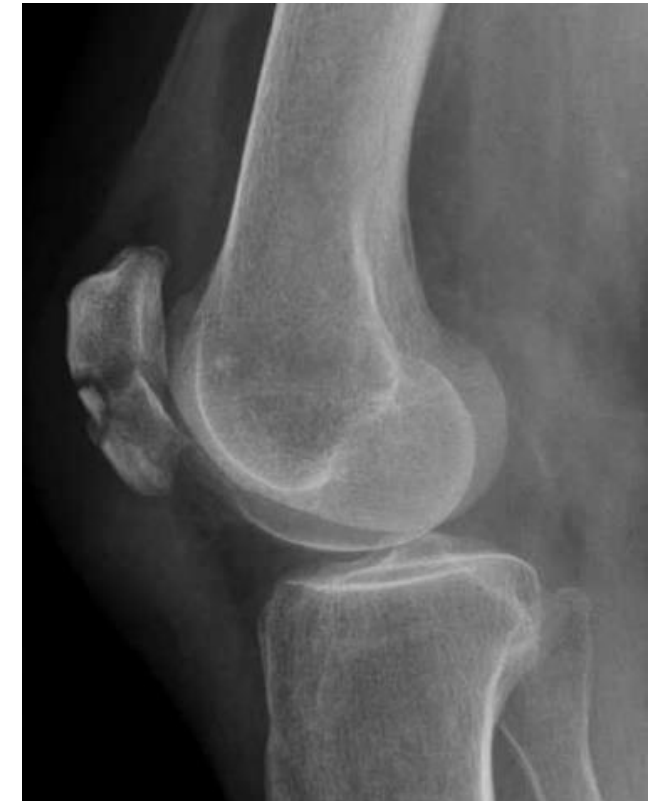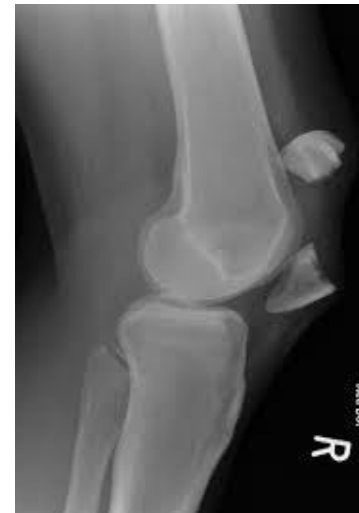Konservativt

- Fleste vertikale + udislocerede (< 2 mm)
- Hængselbandage 6-8 uger med gradvis oplåsning

Indikation for ORIF

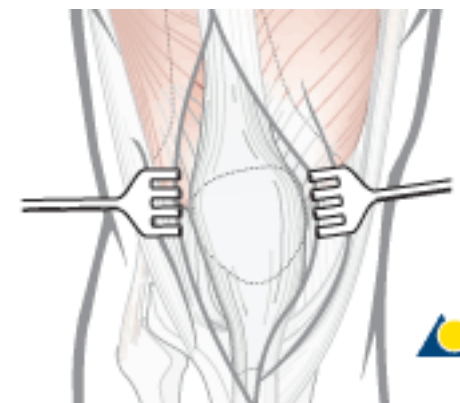
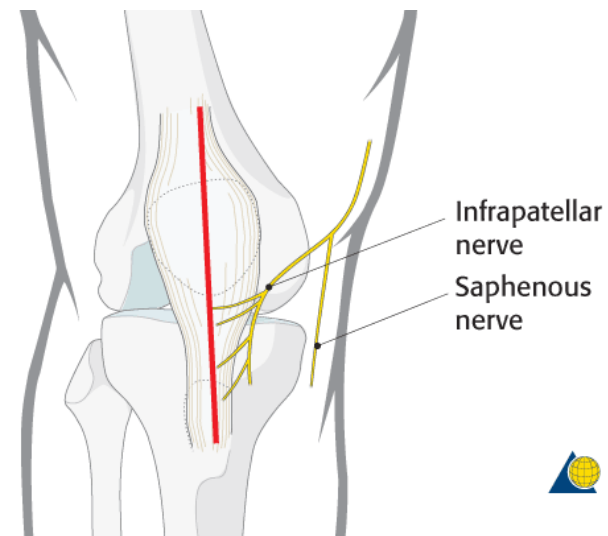
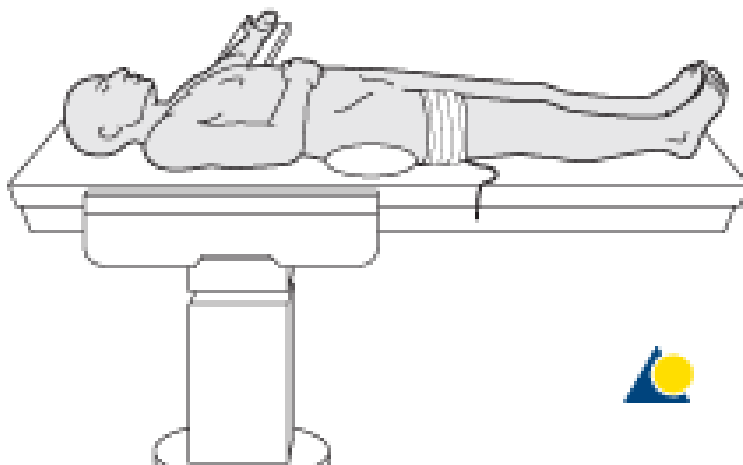
- Manglende evne til ekstension
- Dislocerede (> 2 mm)
- Inkongruens i ledfladen (> 2 mm)
- Osteokondrale frakturer med "ledmus"
- Efter OP, hængselbandage som ved kons.

Patellectomi, helt eller delvist



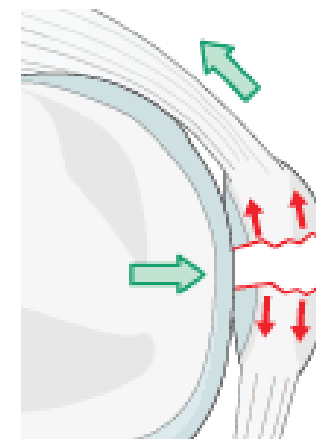
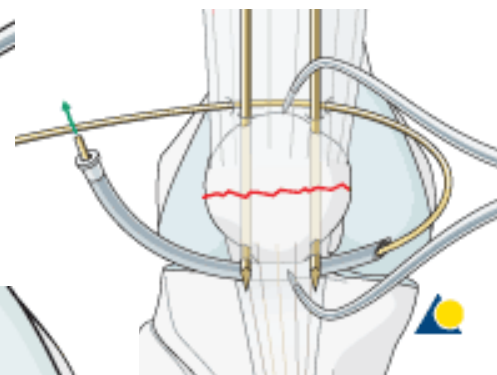
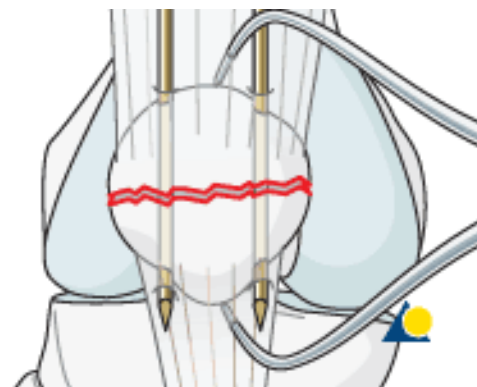
Behandling - ORIF

- K-tråde og cerclage
- Skruer
- Skinner

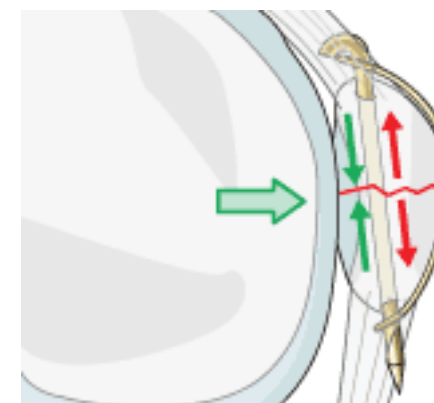
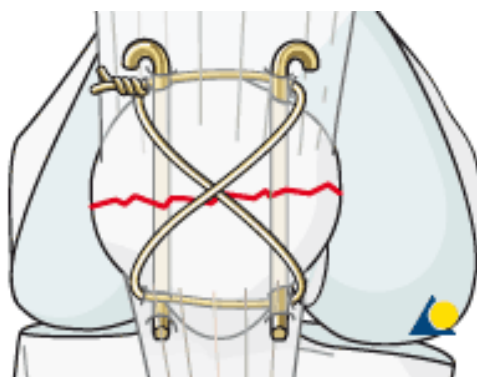
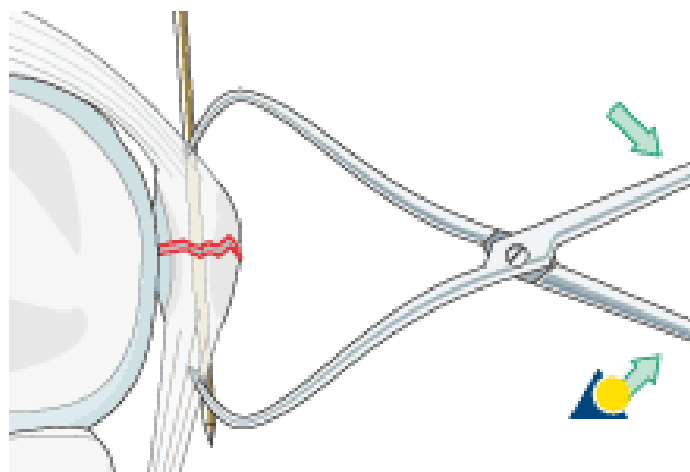


Behandling - ORIF

- K-tråde og cerclage
- Skruer
- Skinner

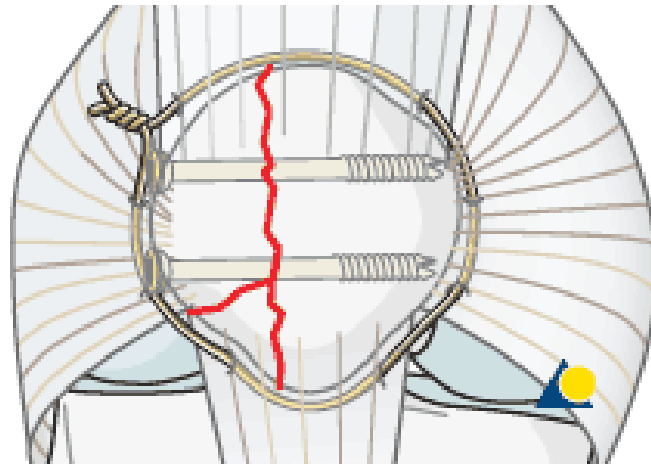


Tensile force

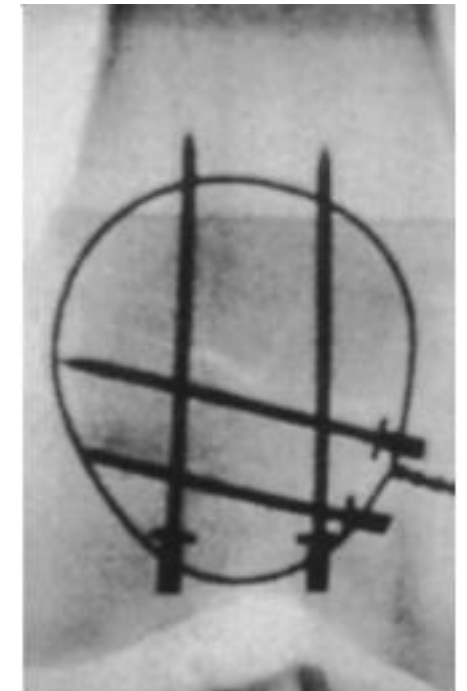

Behandling - ORIF

- K-tråde og cerclage
- **Skruer**
- Skinner

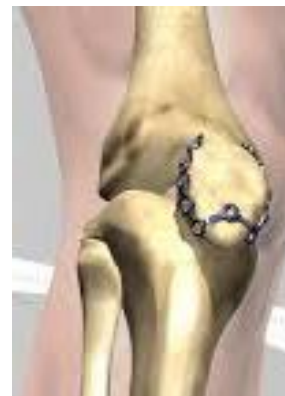

FRAGMENT FIXATION SYSTEM



Behandling - ORIF

- K-tråde og cerclage
- Skruer
- **Skinner**



Behandling – hvad skal man vælge



J Orthop Surg Res. 2018 Sep 5;13(1):226. doi: 10.1186/s13018-018-0919-6.

Efficacy of K-wire tension band fixation compared with other alternatives for patella fractures: a meta-analysis.

Zhang Y¹, Xu Z¹, Zhong W¹, Liu F¹, Tang J².

- 9 studier
- I alt 949 pt'er (TB 581, Kontrol/andre 368)
- **Konklusion**, ingen forskel i:
Tid til heling, infektion, OP-tid, pt tilfredshed...
- Færre komplikationer hos de kanylerede skruer ift. TB...



Behandling



- TB vs. skruer?

BMC Musculoskelet Disord. 2015 Oct 6;16:282. doi: 10.1186/s12891-015-0719-7.

Comparison of the outcomes of cannulated screws vs. modified tension band wiring fixation techniques in the management of mildly displaced patellar fractures.

Lin T^{1,2}, Liu J³, Xiao B⁴, Fu D⁵, Yang S⁶.

RCT, Prospektivt, kontrolleret, randomiseret studie

Tværfrakturer disloceret < 8 mm.

52 pt'er 32: 2-3 kanylerede skruer
 31 TB

Konklusion:

Færre smerter og bedre styrke efter 3 + 6 mdr. hos de skruede
Udlignet efter 12 mdr...

Behandling

- TB vs. skinner?

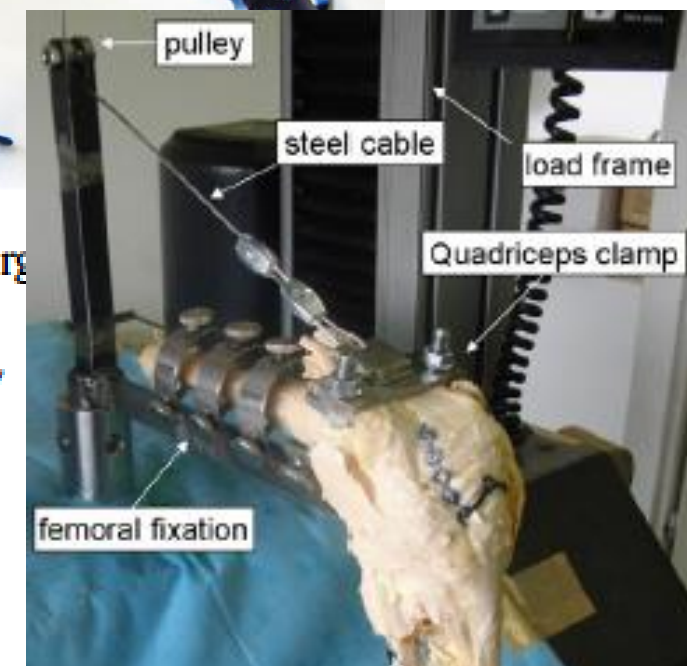
Biomechanical cadaver testing of a fixed-angle plate in tension wiring and screw fixation in transverse patella fracture

Simon Thelen^a, Johannes Schnependahl^{a,*}, Eva Jopen^b, Christian Eichler^b, Jürg Eckhard Schönau^c, Mohssen Hakimi^a, Joachim Windolf^a, Michael Wild^a

^a Heinrich Heine University Hospital Düsseldorf, Department of Trauma and Hand Surgery, Moorenstr. 5, D-40225 Düsseldorf, Germany

^b University of Cologne, Department of Anatomy II, Joseph-Stelzmann Str. 9, D-50931 Cologne, Germany

^c University of Cologne, Children's Hospital, Joseph-Stelzmann Str. 9, D-50924 Cologne, Germany



| Osteosynthesis | Mean tensile load (N) | Fracture gap before 1st cycle (mm) | Fracture gap after 1st cycle (mm) | Fracture gap after 100 cycles (mm) |
|----------------------------------|---------------------------|------------------------------------|-----------------------------------|------------------------------------|
| Modified anterior tension wiring | 223.3 ± 33.3 [*] | 0.0 | 6.1 ± 3.0 ^{**} | 7.1 ± 2.2 ^{***} |
| Lag screws + tension wiring | 219.2 ± 95.0 [*] | 0.0 | 1.6 ± 1.4 ^{**} | 3.7 ± 2.7 ^{***} |
| Fixed-angle plate | 179.3 ± 58.8 [*] | 0.0 | 0.3 ± 0.4 ^{**} | 0.7 ± 0.5 ^{***} |

Behandling

- TB vs. skinner?

Fixed angle plate fixation of comminuted fractures

Tyler B. Moore^c, Bharat R. Sampathi^a, David J. Lynan^a,
John A. Scolaro^{a,*}

^aUniversity of California, Irvine, Orange, CA, USA

^bSt. Alphonsus Medical Center, Boise, ID, USA

^cAshley Regional Medical Center, Vernal, Utah, USA

Retrospektivt, 36 pt'er, kominutte frakturer

Follow up 154 uger (12-297)

Resultater

AA 0/36

Non-union 0/36

Frakturskred 1/36

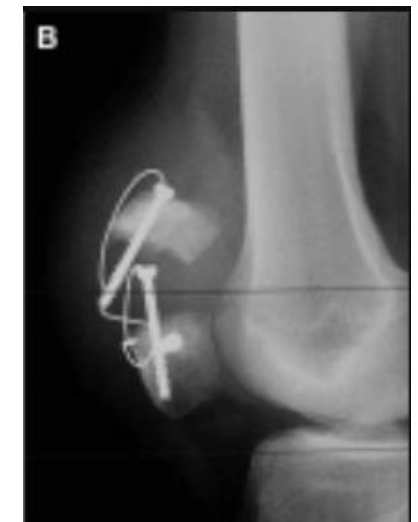
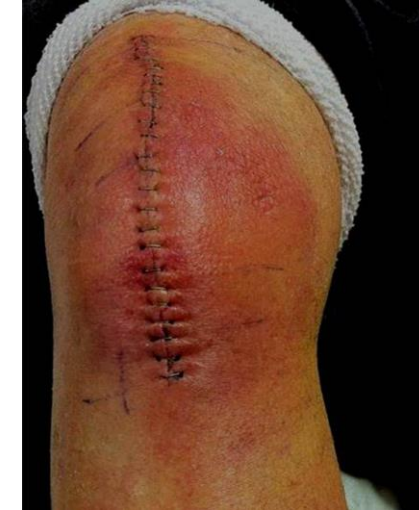
le skruer 17/36

le cerclage 2/36

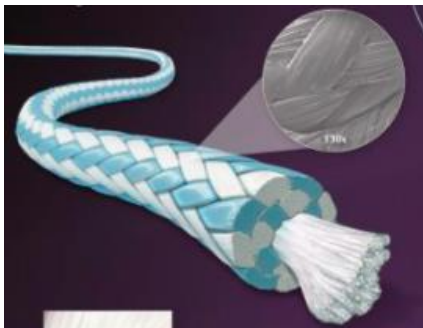
Komplikationer

- Smerter og nedsat bevægelse/kraft (40-80%)
- Infektion (3-10%)
- Osteosyntesesvigt (-> 20%)
- Gener fra hardware => AA (-> 37%)
- Posttraumatisk artrose (8,5%)



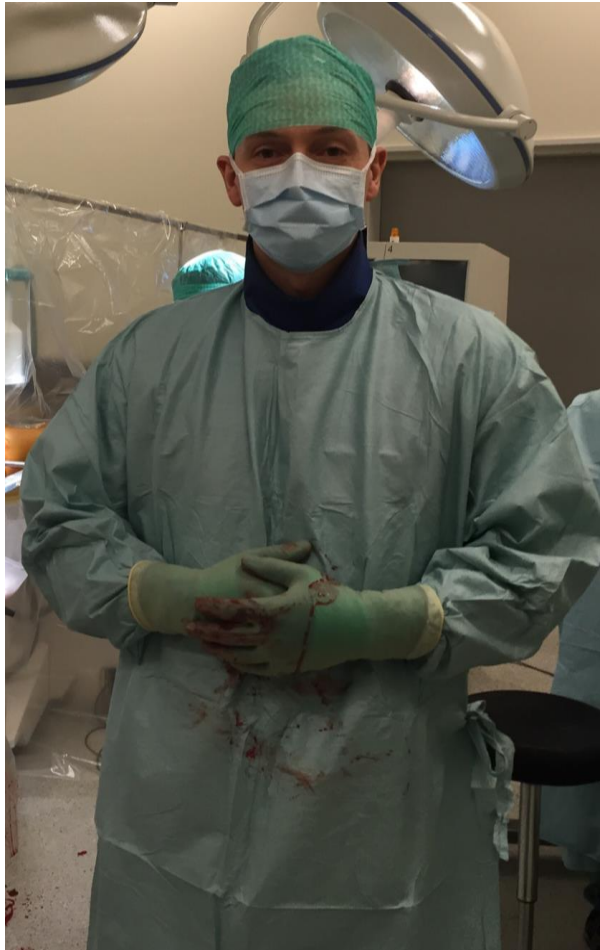Fremtiden...?

- Pilotstudie vedr. suturering med fiberwire...

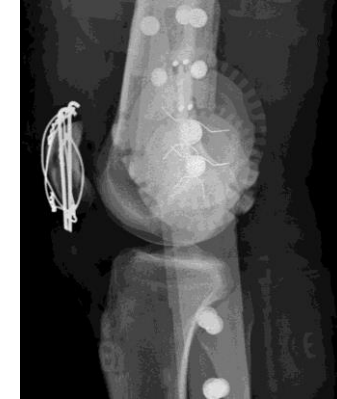
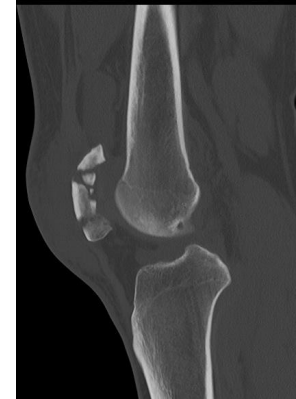
?

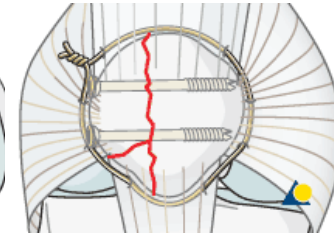
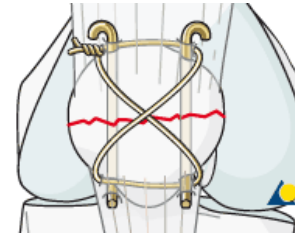
Take-Home messages...



ension og ledflade via



DRIF, måske vi skruer for
utureres...?



on med høj

