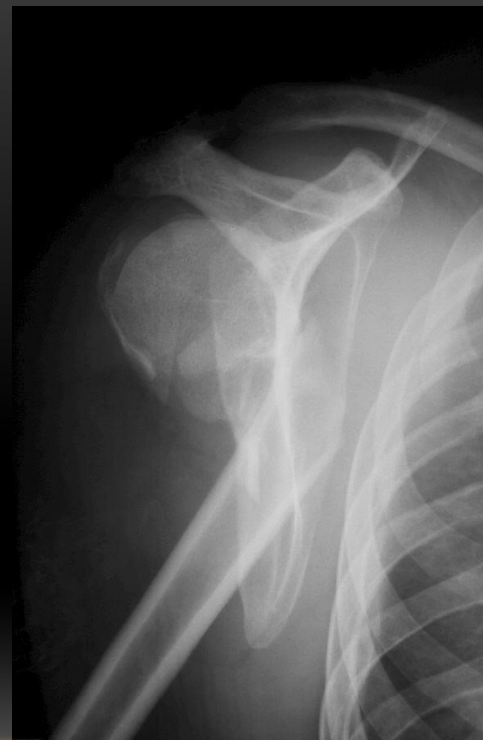
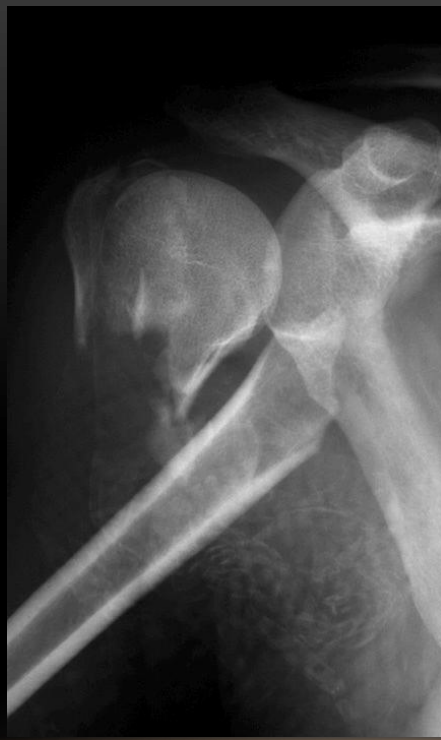


PROXIMAL HUMERUSFRAKTURER

Morten Schultz Larsen

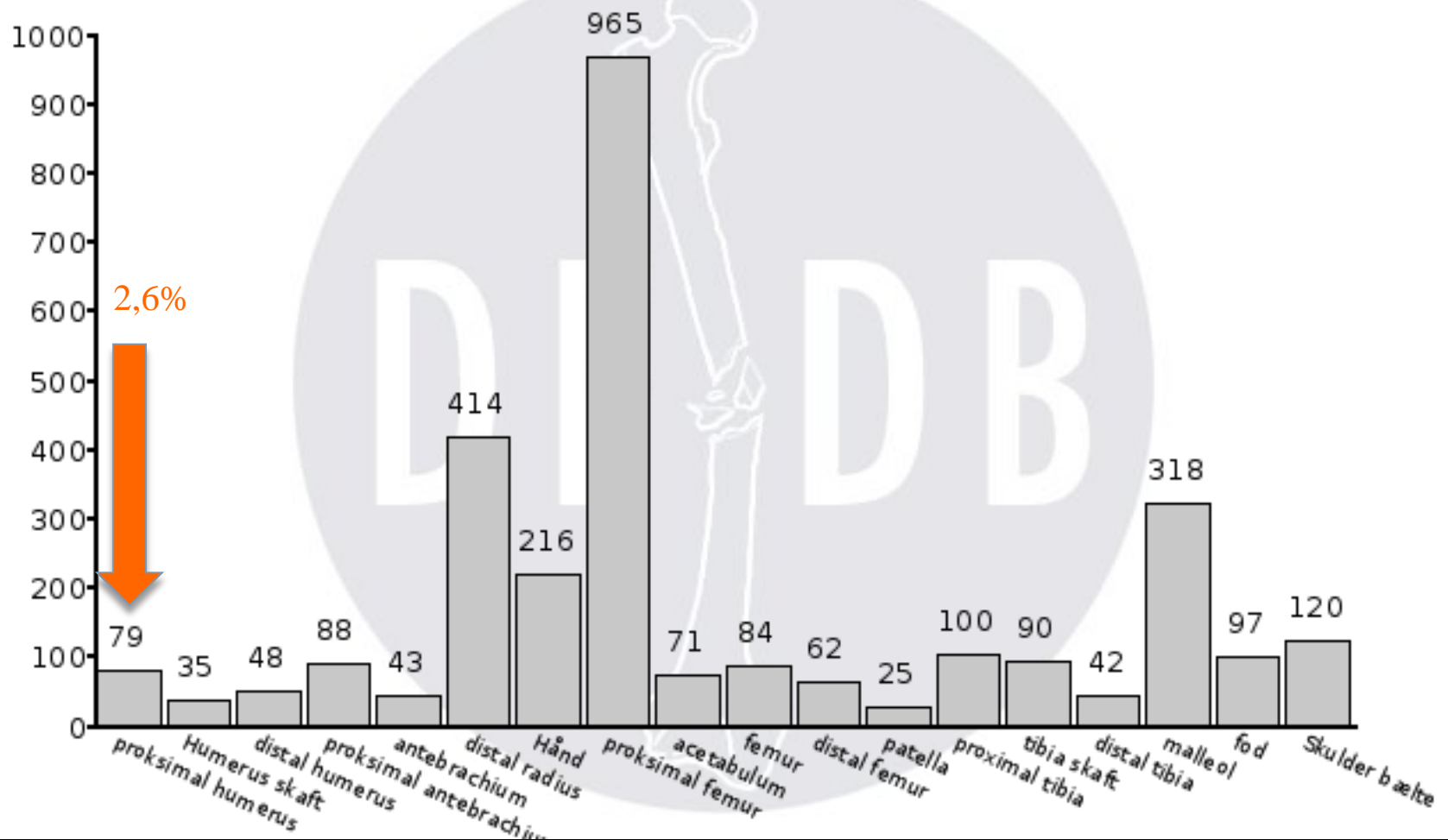
Odense Universitetshospital

Ortopædkirurgisk afd.



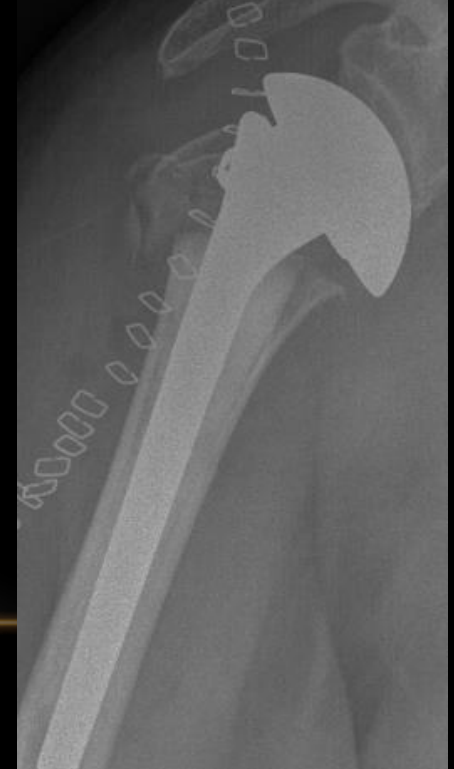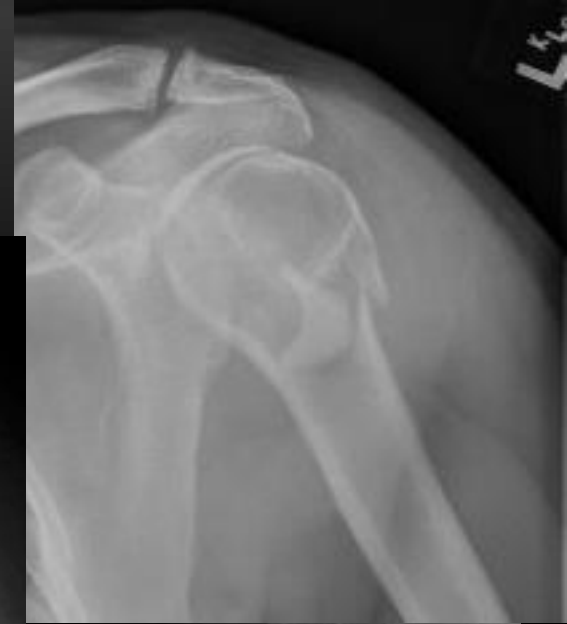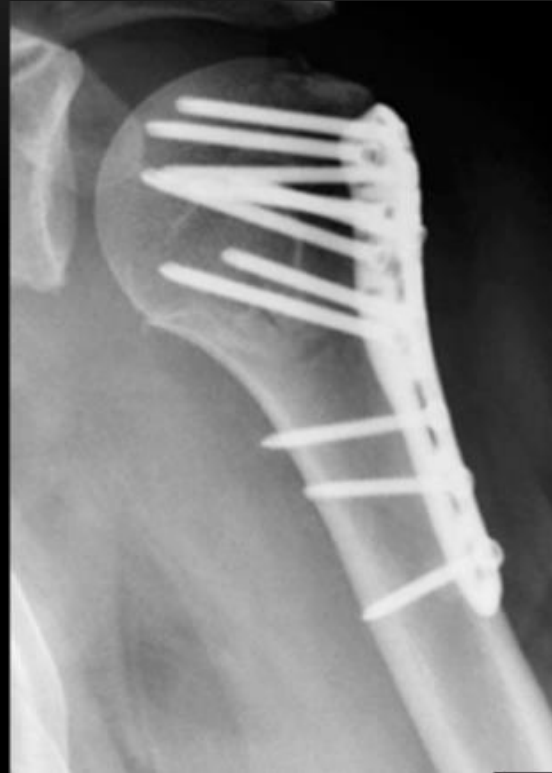HVOR MANGE OPERERES

AO klassifikation, voksne



BEHANDLING

- Konservativ
 - Minimalt displaceret
 - Lavt funktionsniveau
- Osteosyntese
 - Displaceret
 - Bevaret blodforsyning
 - Kan fikseres STABILT
- Protese
 - Kan ikke osteosynteres
 - Kan ikke behandles konservativt

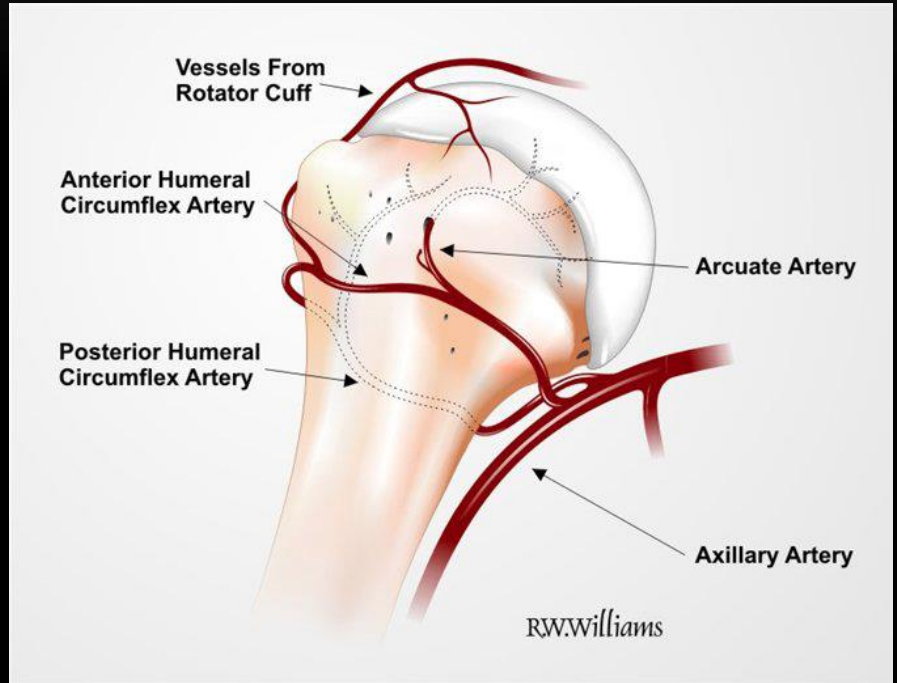


KORT KLINISK RETNINGSLINIE (DOS)

- Alder > 60 år
- Displacerede frakturer efter Neers klassifikation (2-, 3-, og 4-part frakturer)
- Ingen studier af moderat eller høj kvalitet har fundet nogen klinisk eller statistisk relevant forskel mellem kirurgisk og ikke-kirurgisk behandling af displacerede proximale humerusfrakturer hos ældre.
- Vi anbefaler derfor at behandlingen af disse frakturer som udgangspunkt bør være ikke-kirurgisk
- Det er muligt at andre frakturtyper samt yngre patienter kan have gavn af operativ behandling

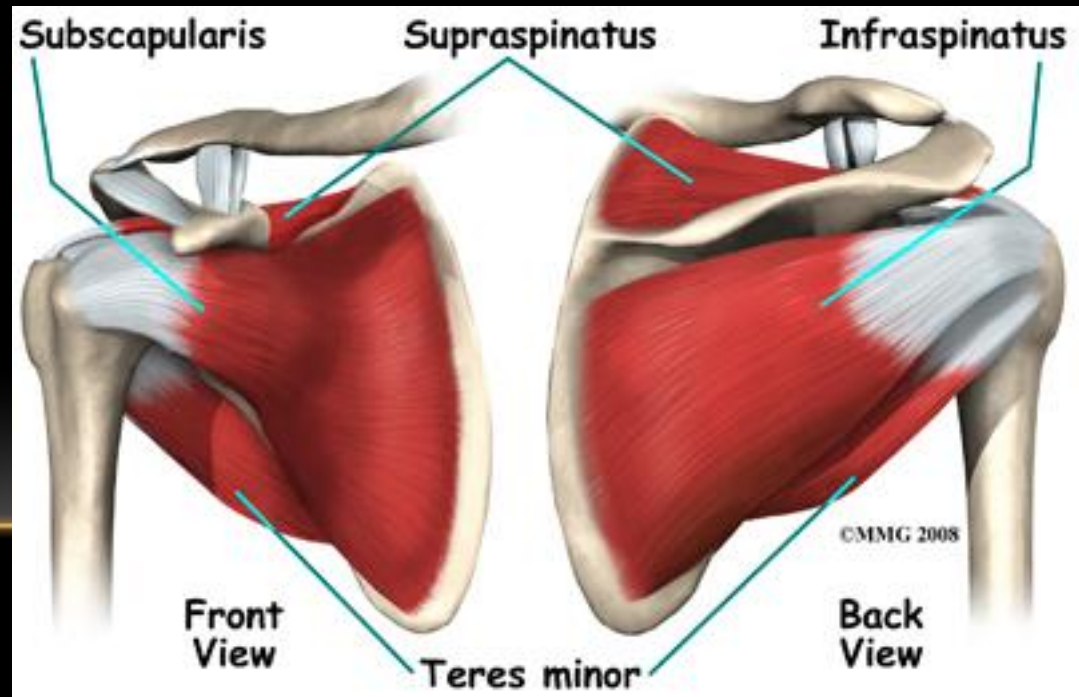
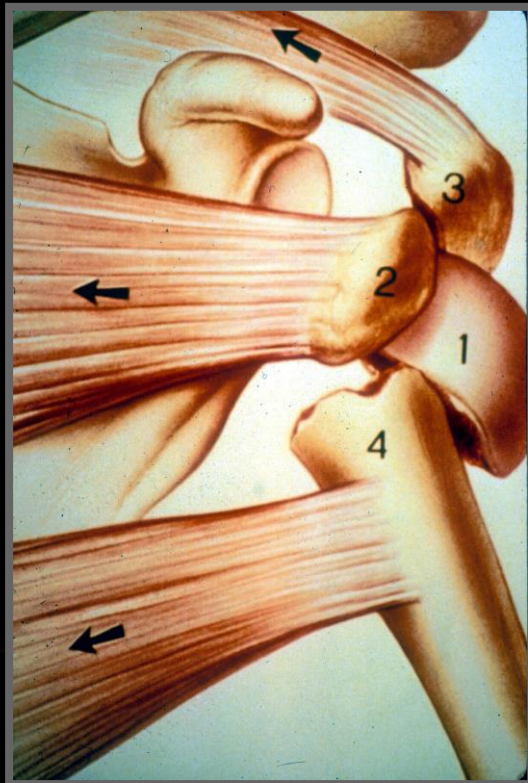
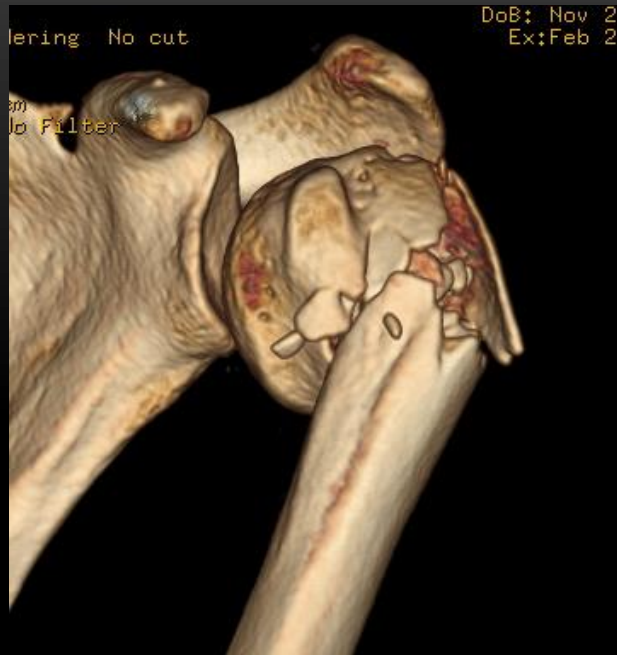ANATOMI

- Humerus
 - Retroverteret caput (40 gr)
 - Tuberculum majoris
 - Tuberculum minus
- Bløddele
 - Blodforsyning
 - Rotatorcuff
















ROTATORCUFF

- Hvilke sener?
- Planlæg reposition



CLASSIFICATION - NEER

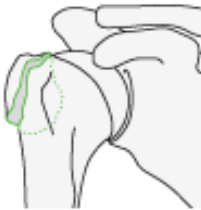	2 part	3 part	4 part
Anatomical neck			
Surgical neck			
Greater tuberosity			
Lesser tuberosity			
Fracture dislocation anterior			
Fracture dislocation posterior			

CLASSIFICATION

Unifocal
extra-articular

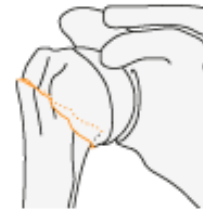

11-A1
tuberosity



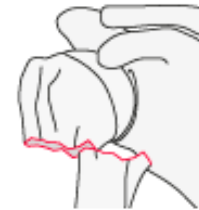Please select

11-A2
impacted
metaphyseal



select

11-A3
non-impacted
metaphyseal

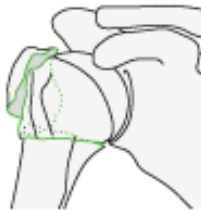

select

Bifocal
extra-articular

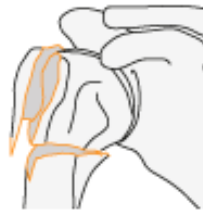

11-B1
with metaphyseal
impaction



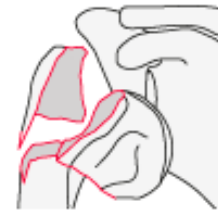
Please select

11-B2
without
metaphyseal
impaction



select

11-B3
with glenohumeral
dislocation

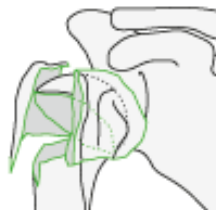


select

Articular

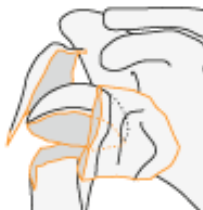

11-C1
with slight
displacement



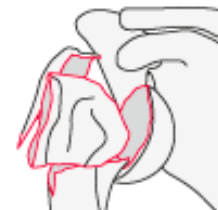Please select

11-C2
impacted with
marked
displacement



Please select

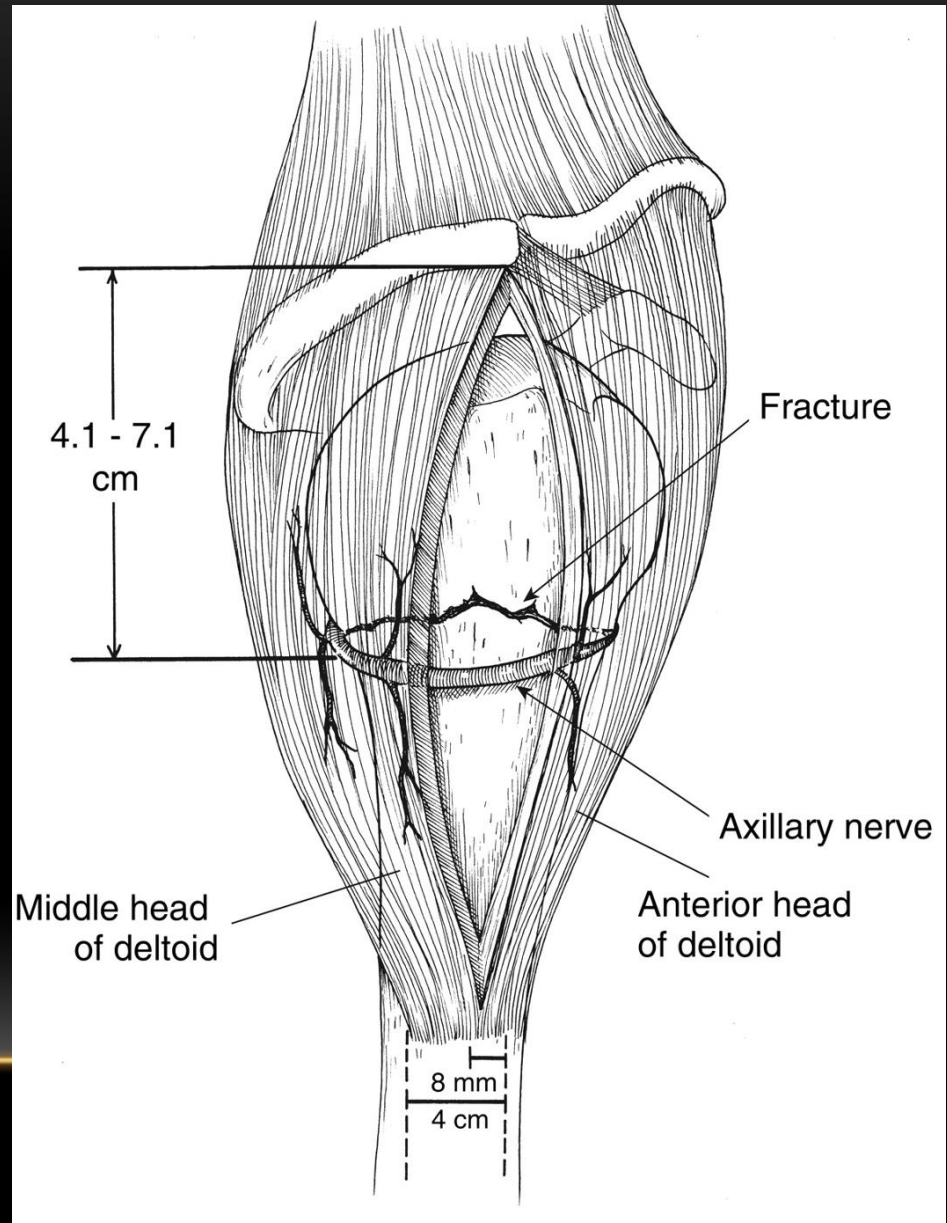
11-C3
dislocated



Please select

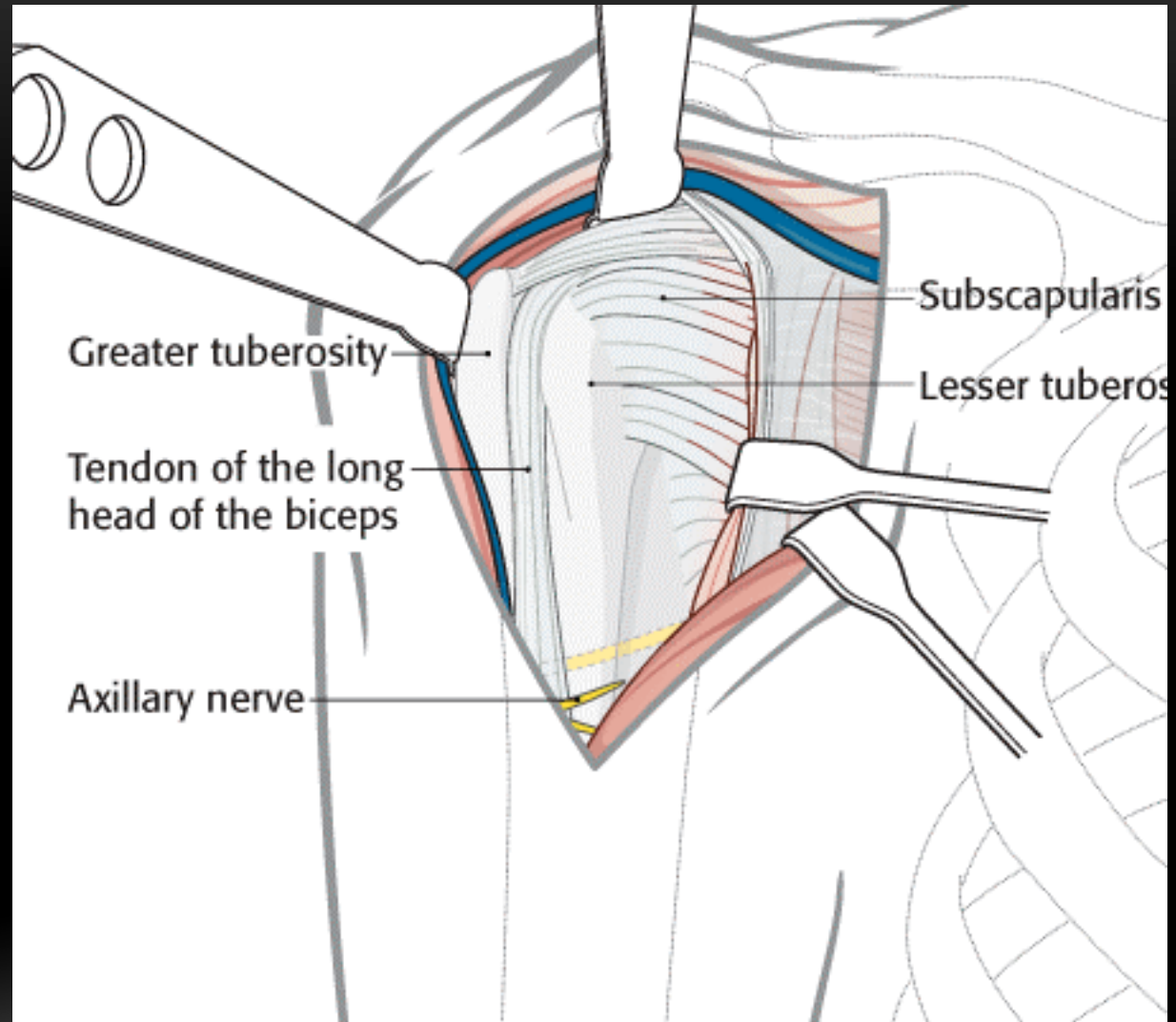
ADGANGE

- Transdeltoid
 - OBS n. axillaris



ADGANGE

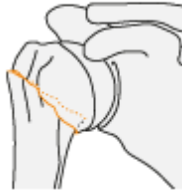- Transdeltoid
 - OBS n. axillaris
- Deltopectoral



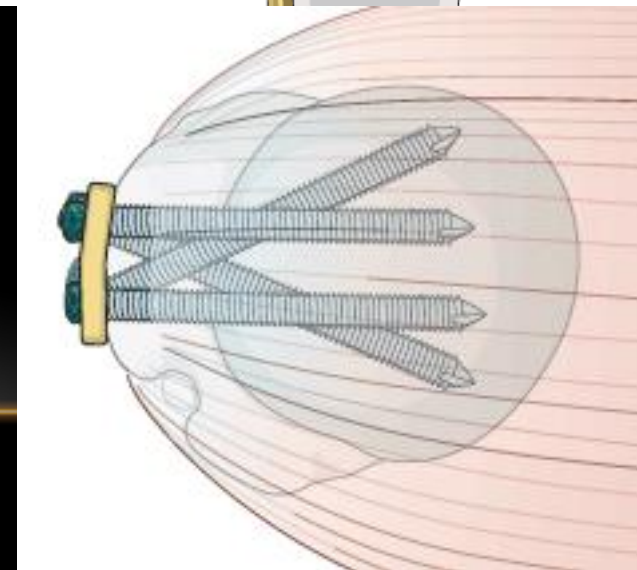
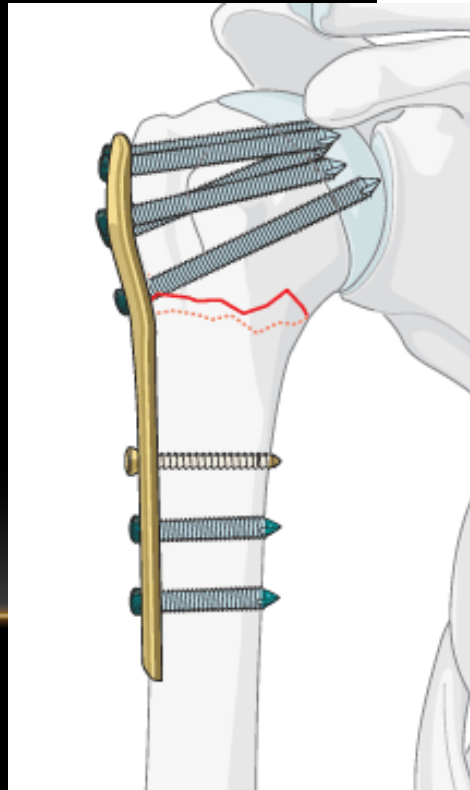
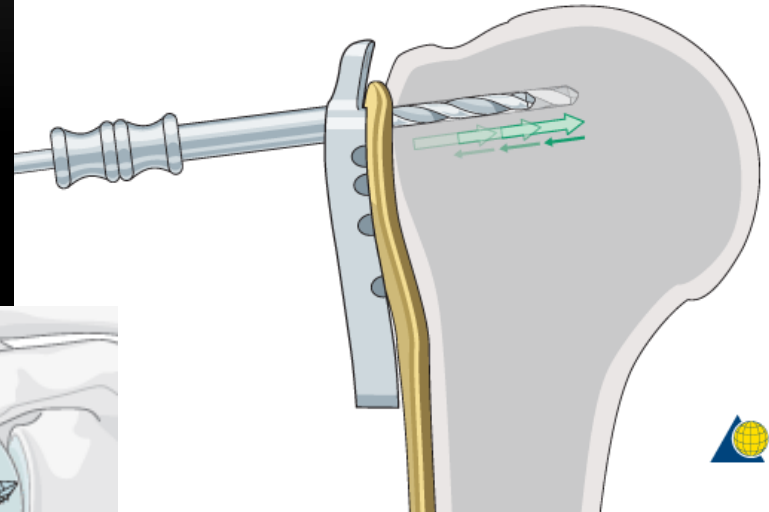
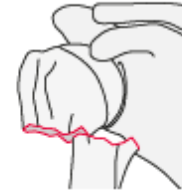OSTEOSYNTESE MED LÅSESKINNE

- Åben reposition
- Placering af skinne
- Kun låseskruer i caput
 - Woodpecker teknik
 - Mindst 6 skruer
 - Spredning

11-A2
impacted
metaphyseal



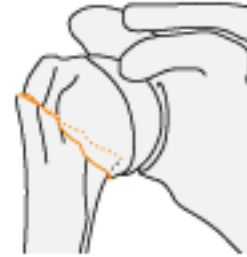11-A3
non-impacted
metaphyseal



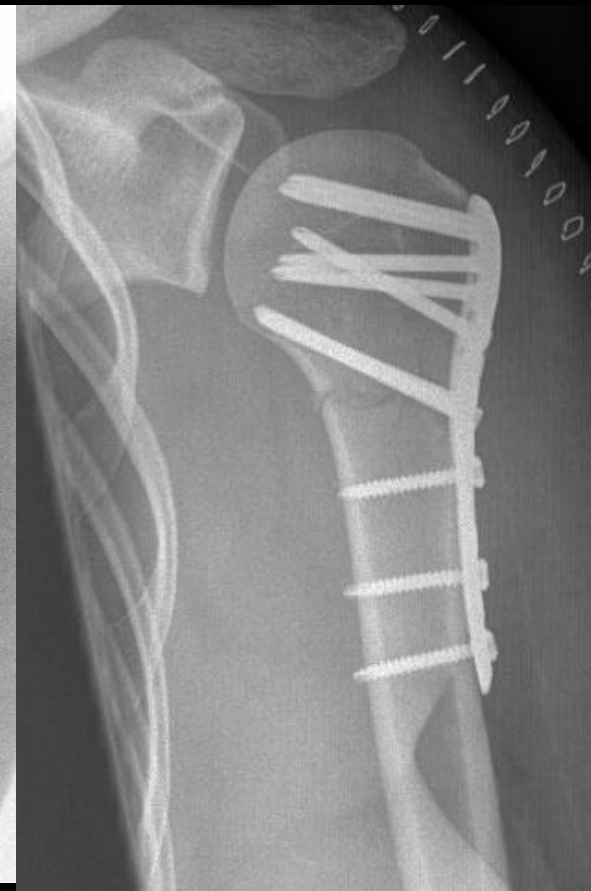
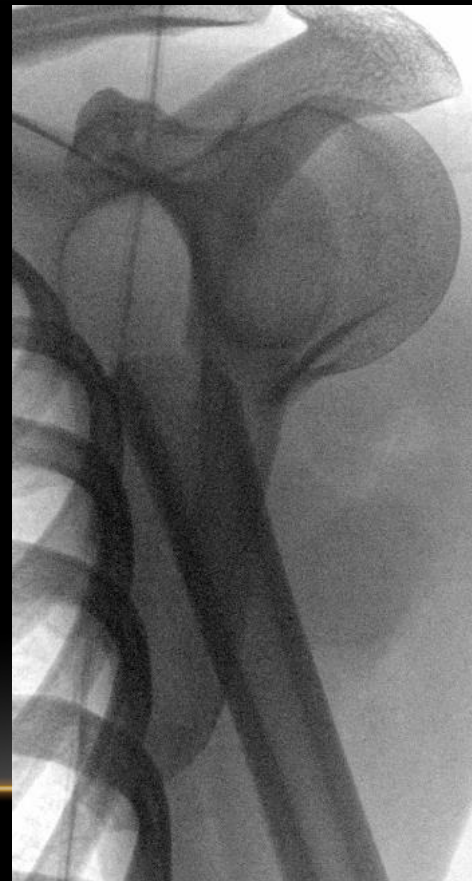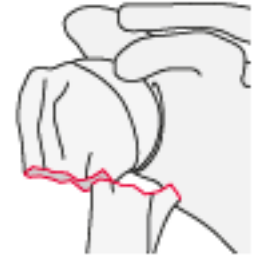
TO PARTS FRAKTURER

- Indikation for osteosyntese
 - Displaceret
 - Højt funktionsniveau
- Pitfalls
 - Rotation af caput
 - Placering af skinne

11-A2
impacted
metaphyseal

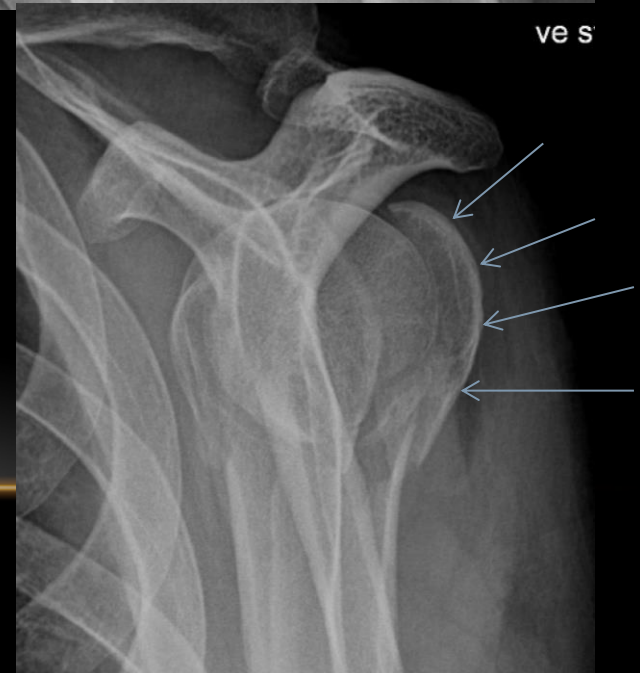
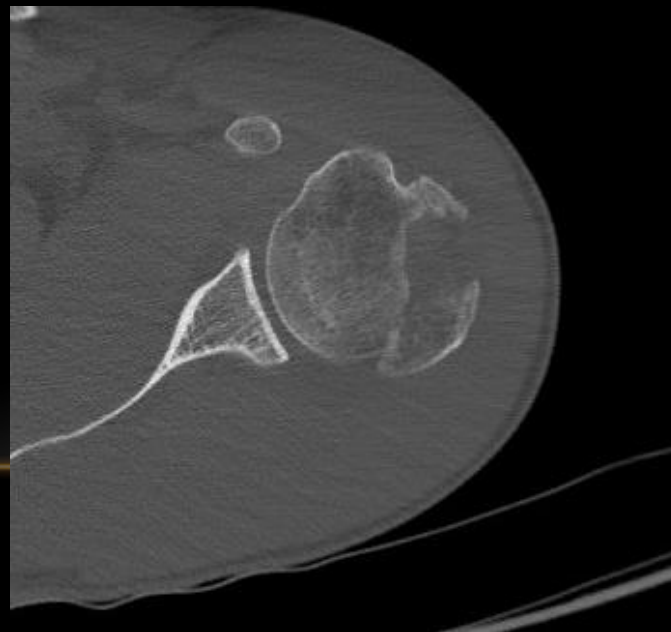
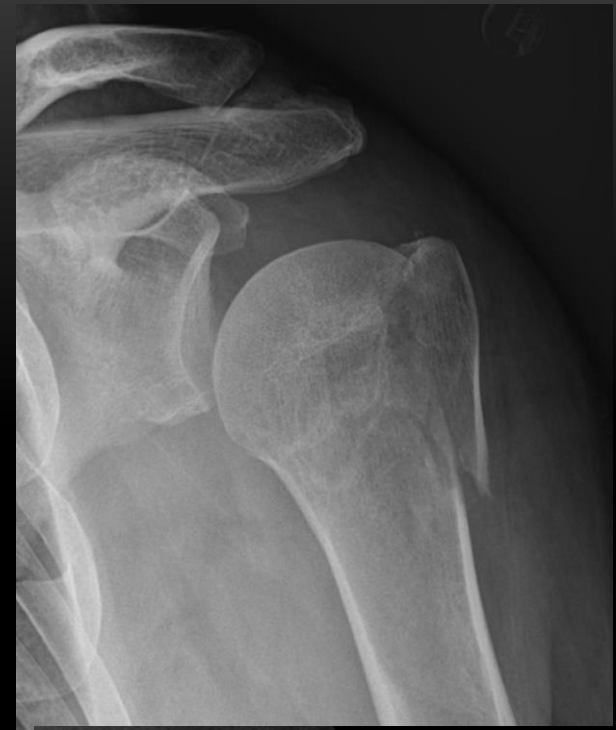
11-A3
non-impacted
metaphyseal



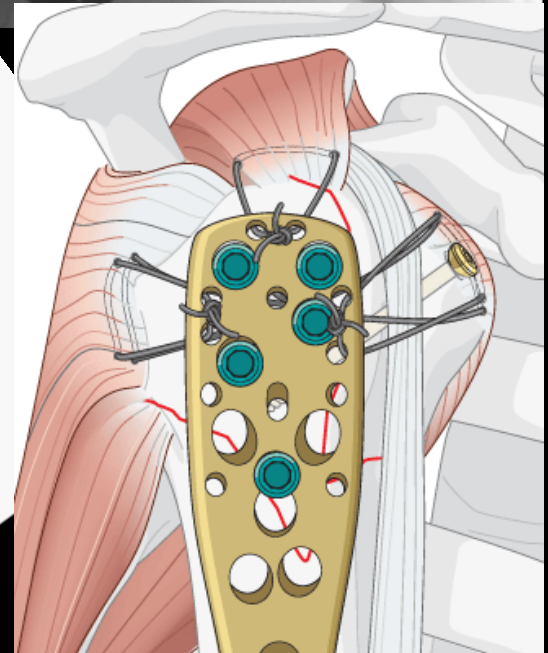
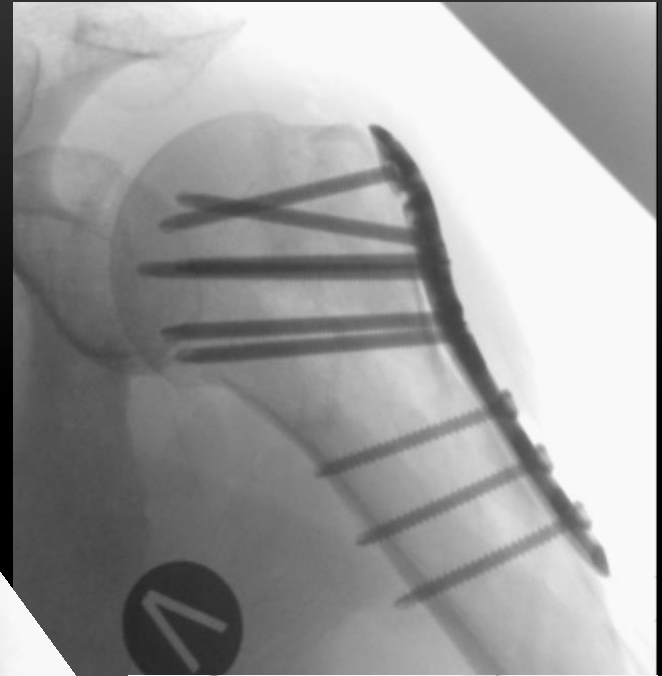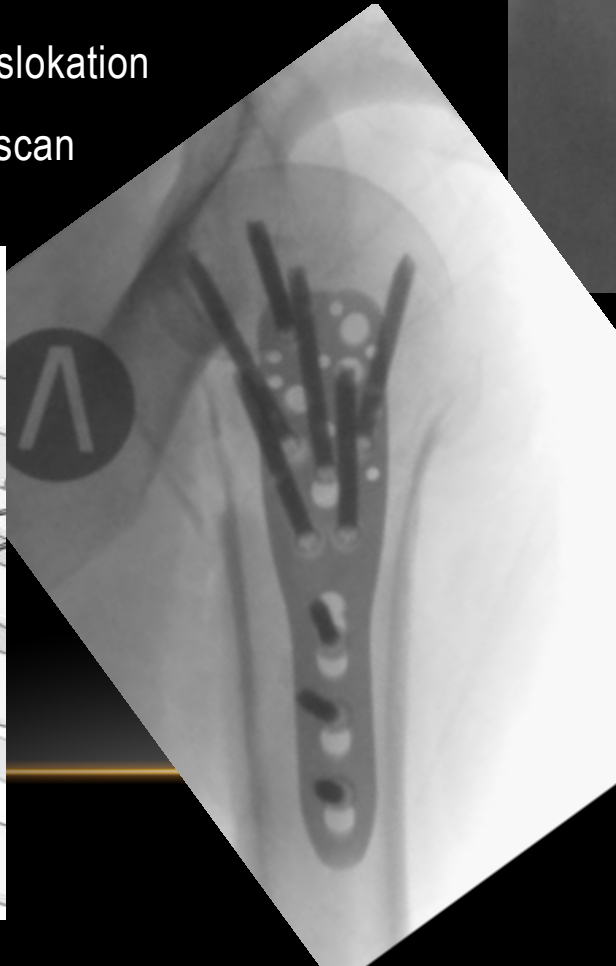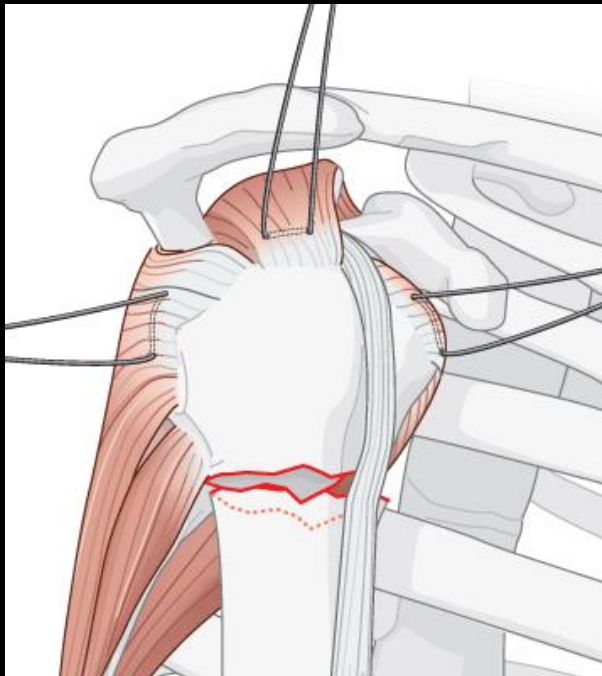
TUBERCULUM MAJUS

- Isoleret eller del af 3-4 parts
 - Efter luksation
 - Operation > 1 cm dislokation
 - Obs sidebillede/CT scan



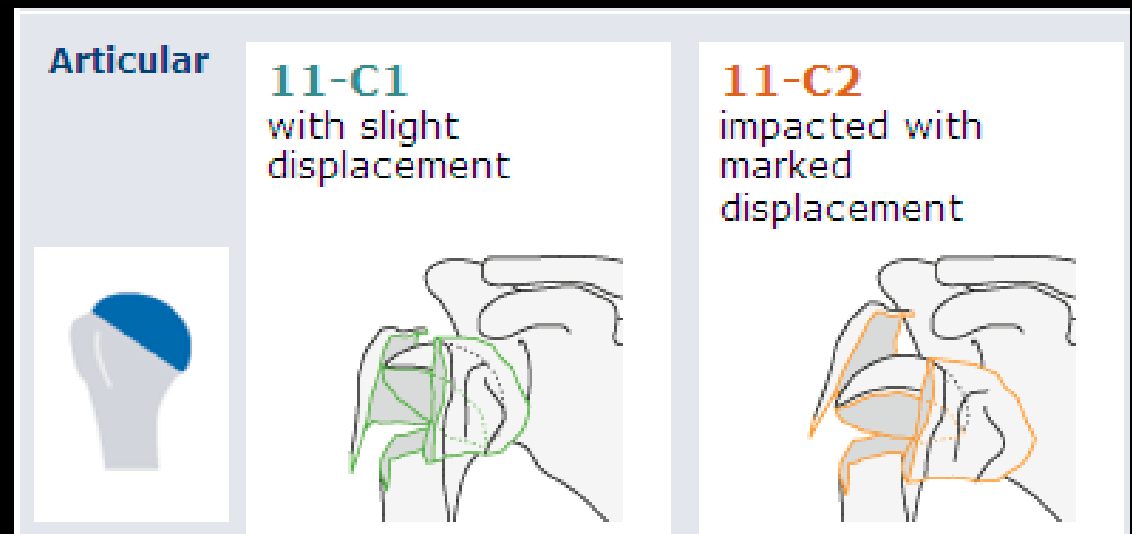
TUBERCULUM MAJUS

- Isoleret eller del af 3-4 parts
 - Efter luksation
 - Operation > 1 cm dislokation
 - Obs sidebillede/CT scan

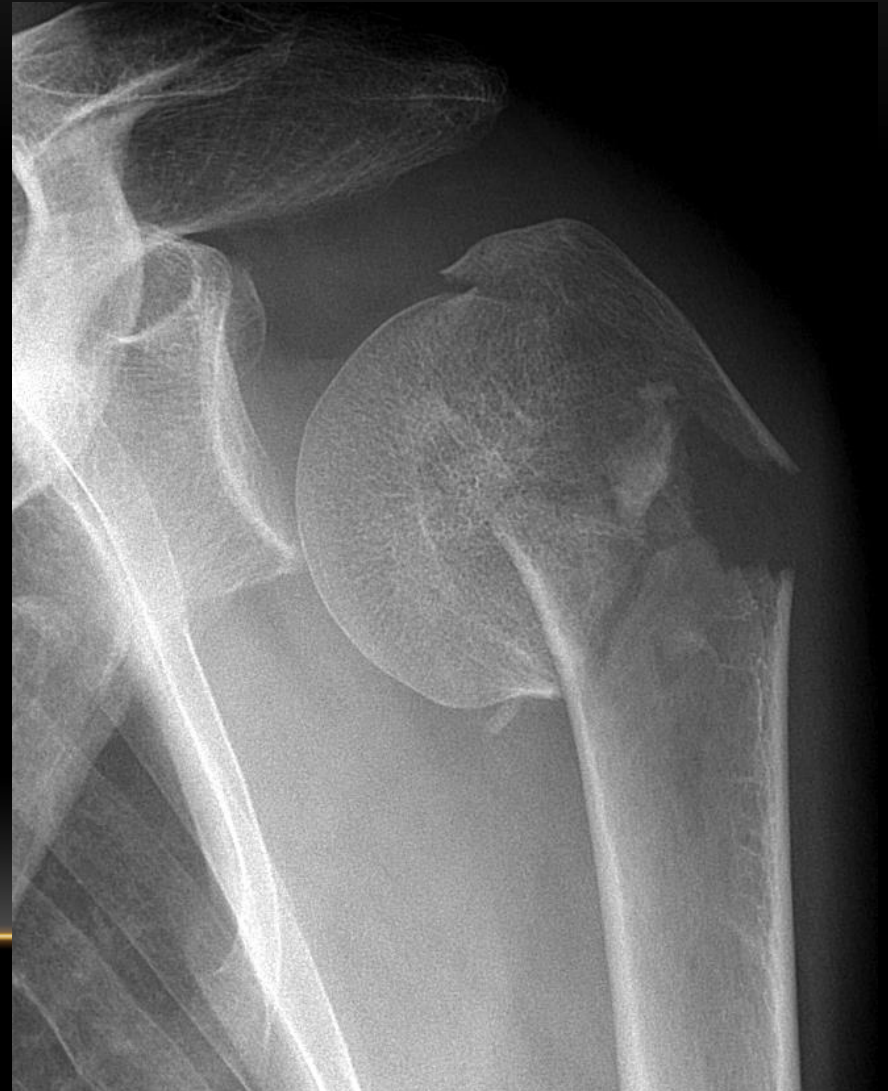
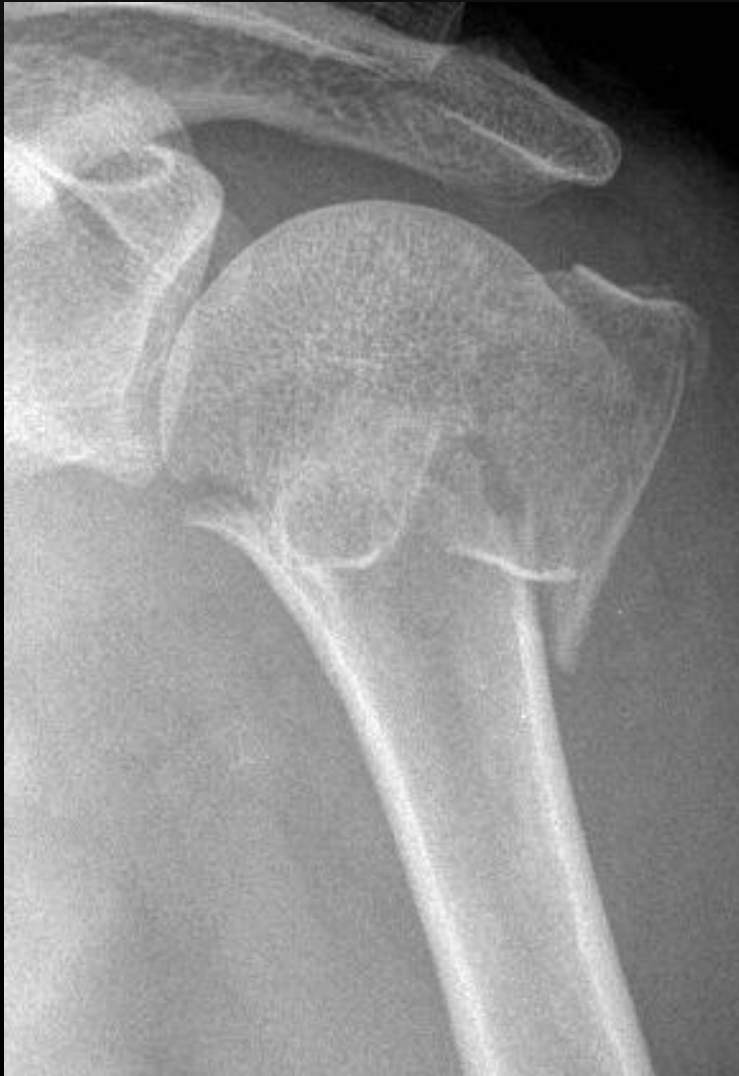
UDVALGTE FRAKTURTYPER

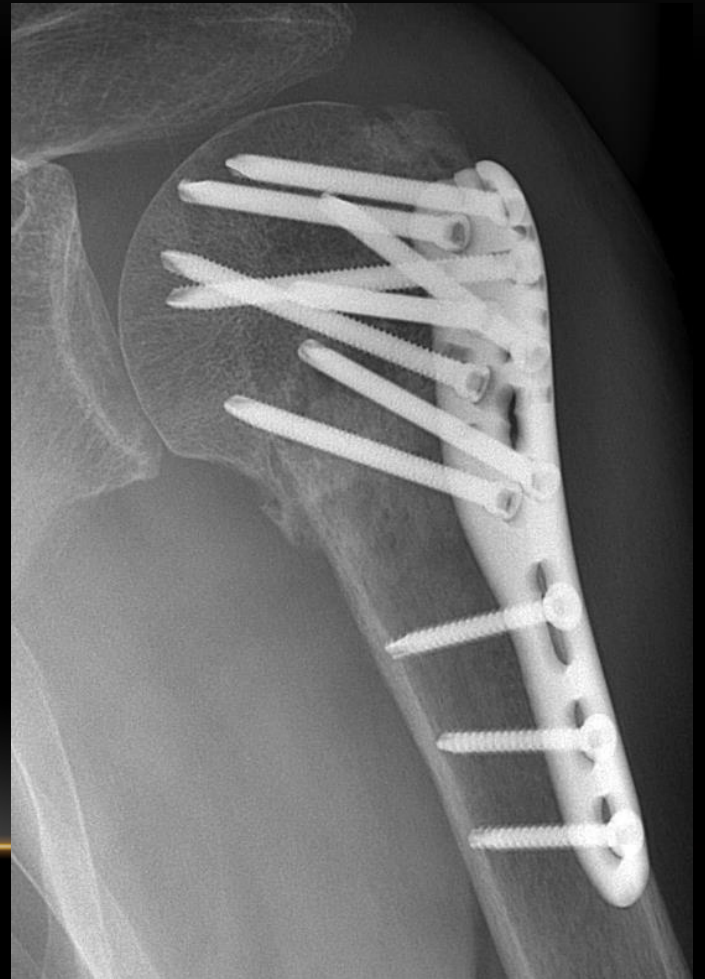
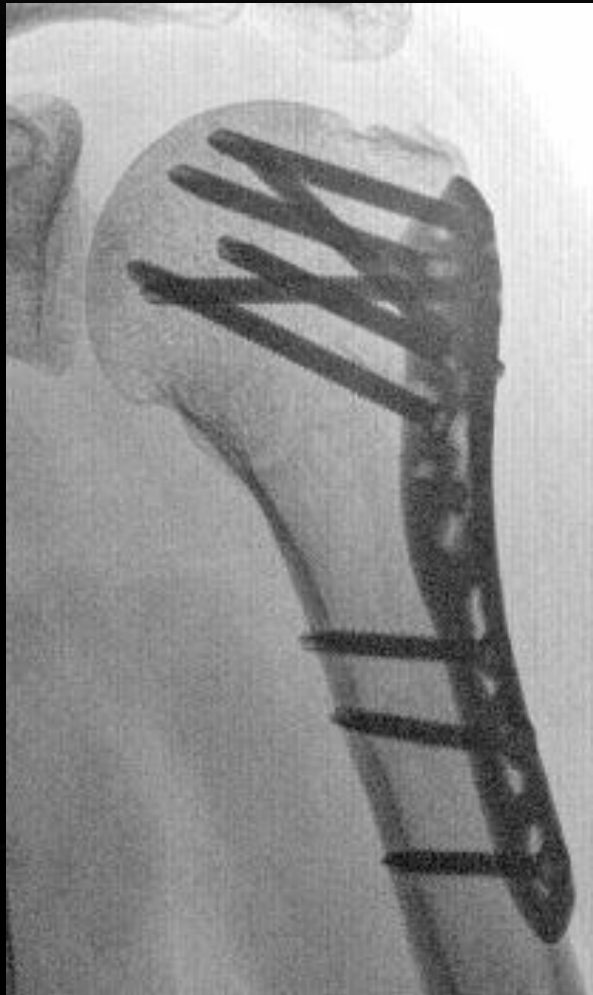
- C1 – C2 frakturer
- Genkendelige mønstre
- Kræver særlige tiltag
 - Reposition
 - Osteosyntese



VALGUS ELLER VARUS

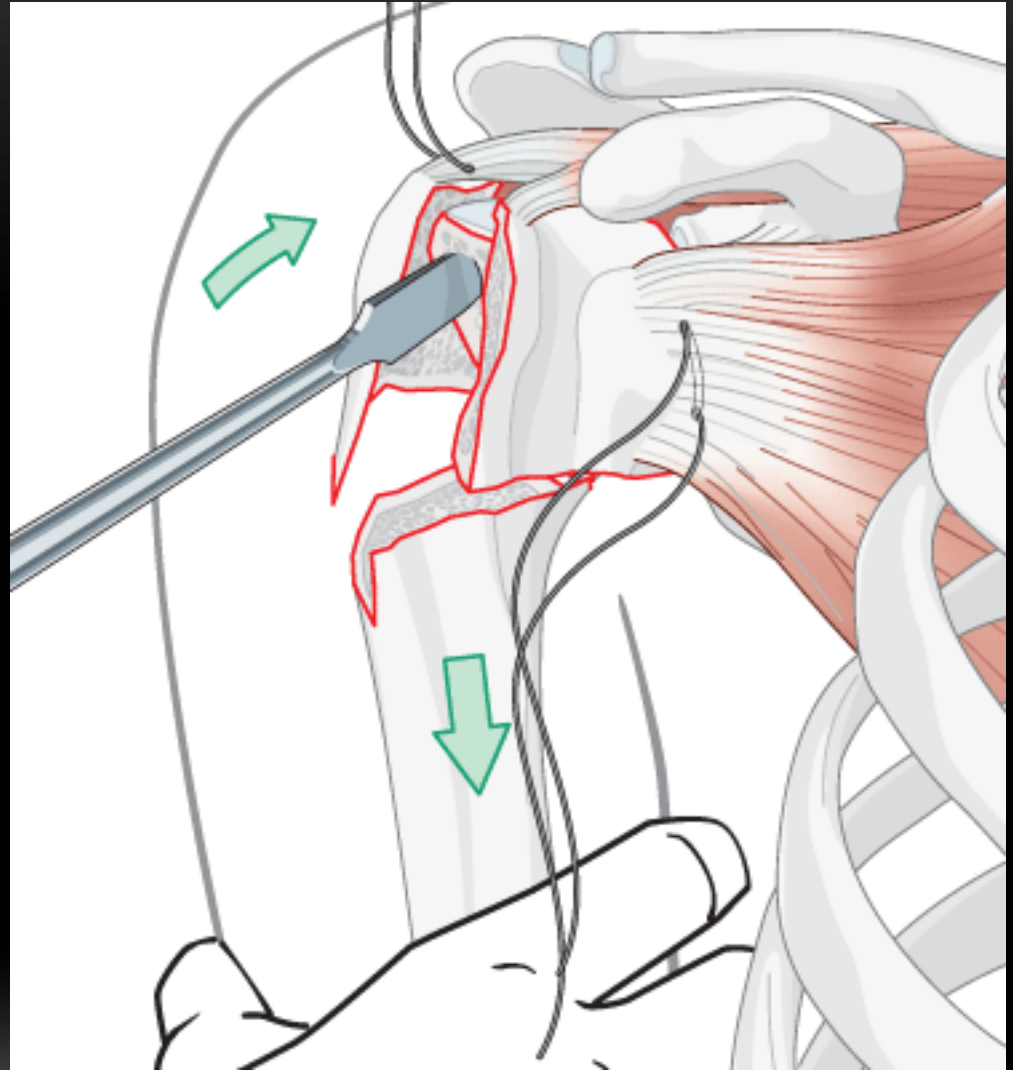


VALGUS ELLER VARUS

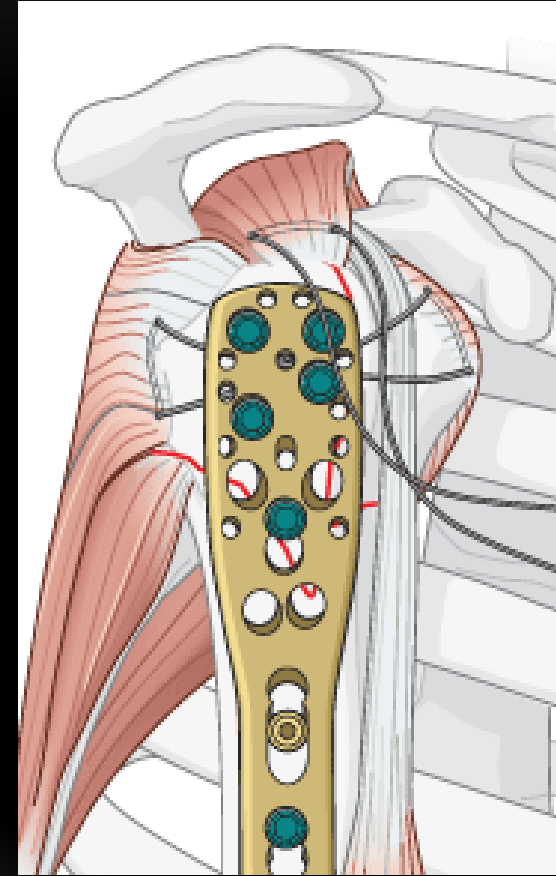
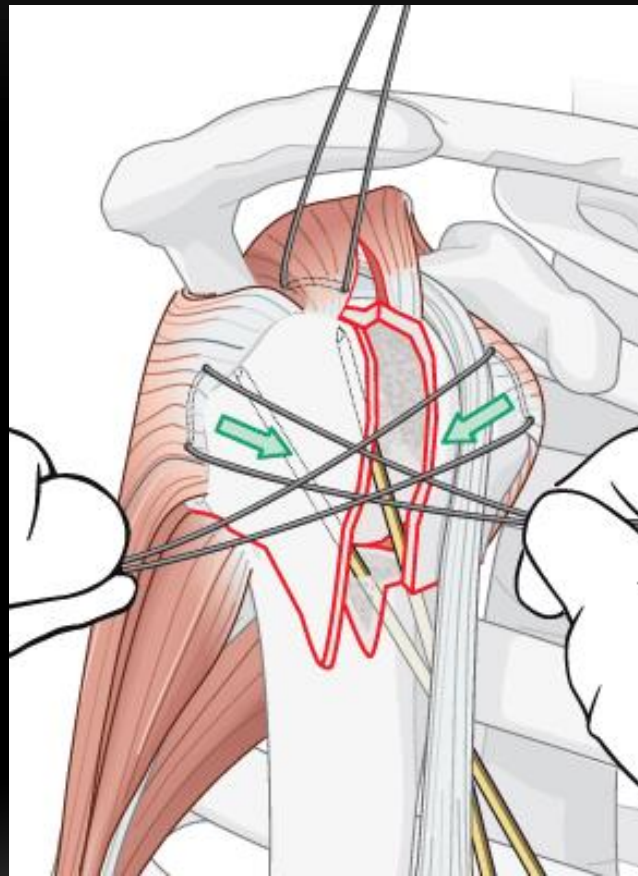
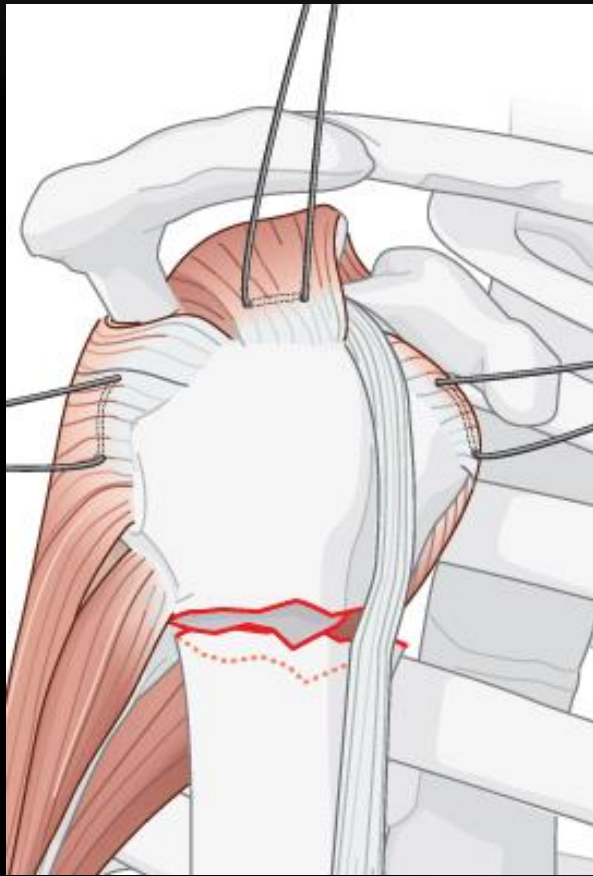


REPOSITION

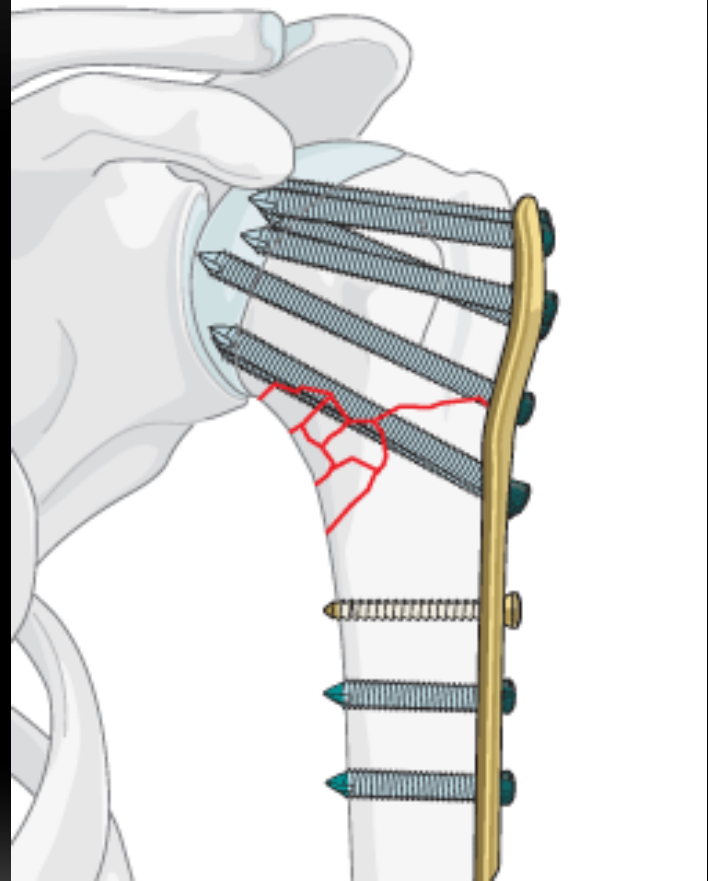
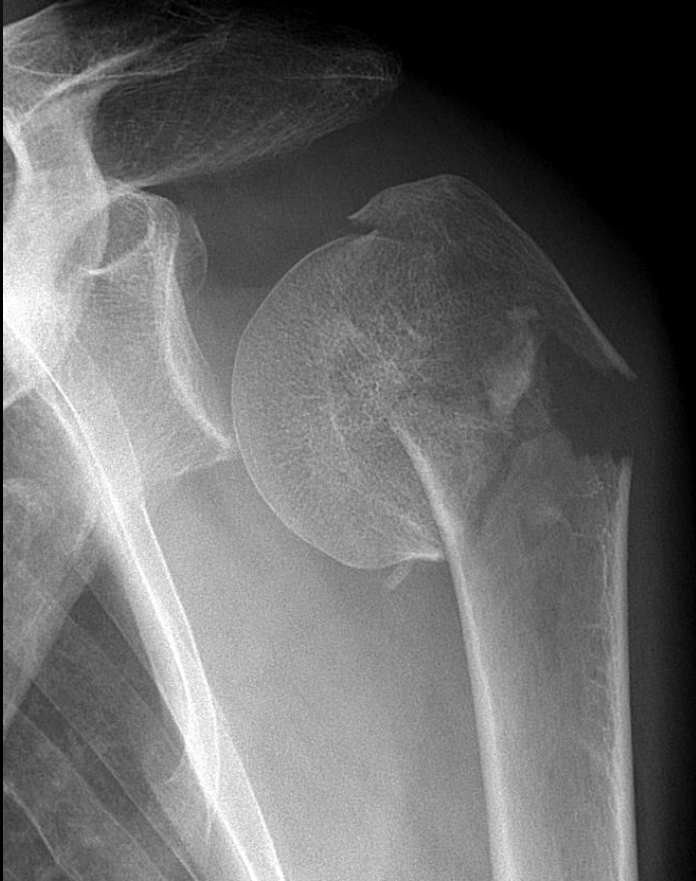- Forskellig varus og valgus
- Forsigtig manipulation af fragmenter



CUFF SUTUR



CALCAR SKRUER



RESUMÉ

- Vær omhyggelig med indikation
 - Patient
 - Fraktur
 - Kirurg
- Præoperativ planlægning
 - Billeddiagnostik
- Operativt
 - Reposition
 - Suturer i cuffen
 - Stabil fiksatation

