

Tibial Shaft Fractures (proximal, distal, segmental)

Søren Kring

Orthopaedic Trauma Surgeon, Hvidovre

AO Trauma Course – Advanced Principles of Fracture Management

April 25–28, 2022 Fredericia, Denmark

AO Basic – Intramedullary Nailing (IMN)

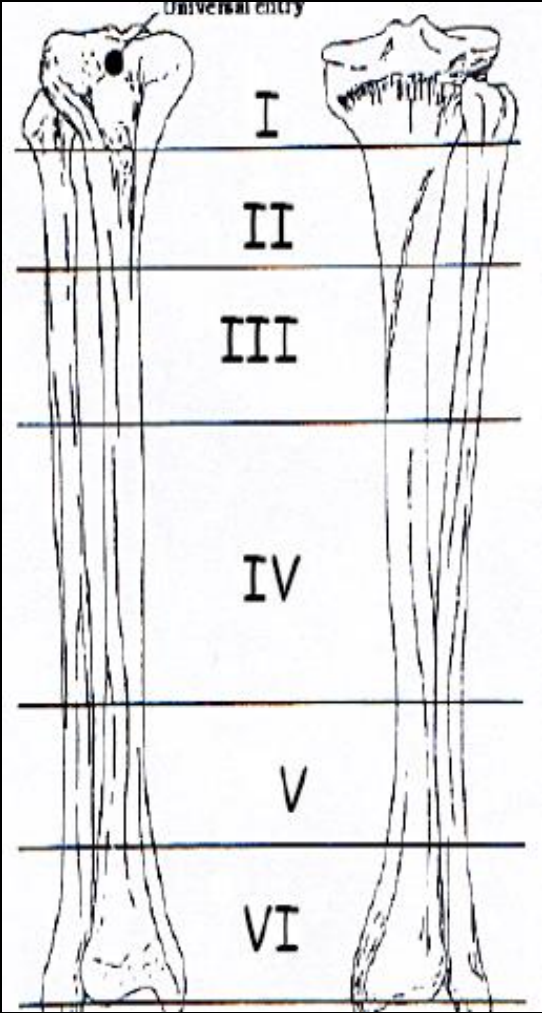
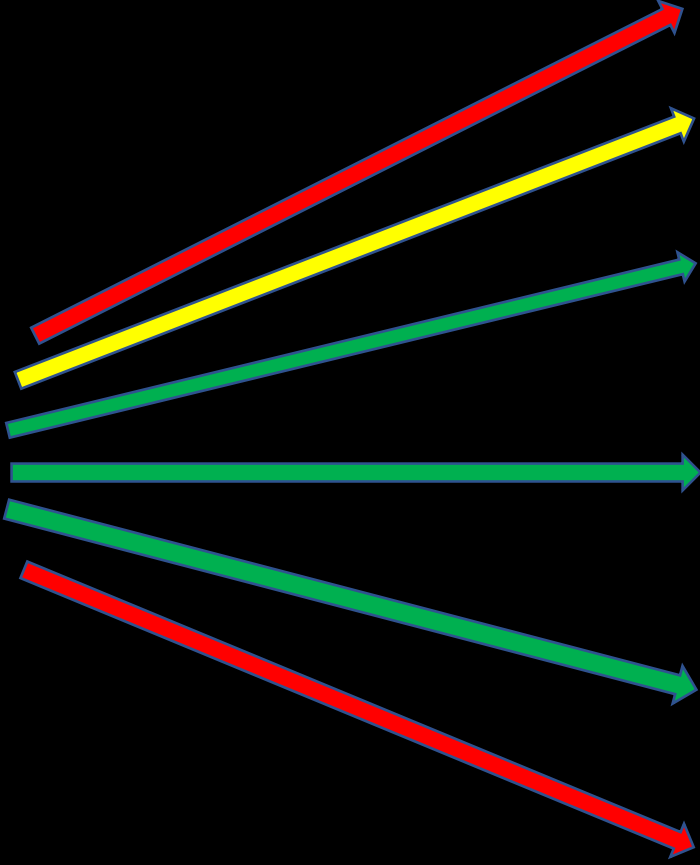
- IMN is the golden standard in diaphyseal tibial fractures (biomechanical better than plate)
- Obtaining correct entry point is crucial
- Reaming leads to better nail-to-bone fit and facilitates fracture union
- Keep the fracture reduced during reaming and nail insertion
- Biomechanics: Long and thick nail to provide stiffness and enhance gripping strength
- Always use af sufficient number og locking screws depending on fracture pattern

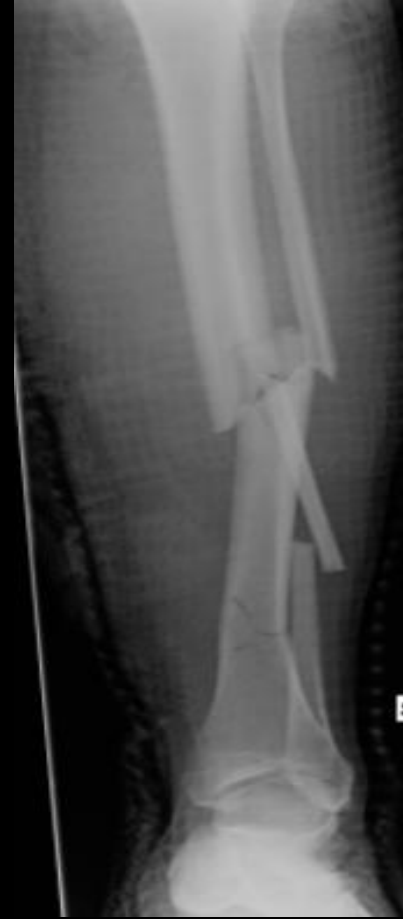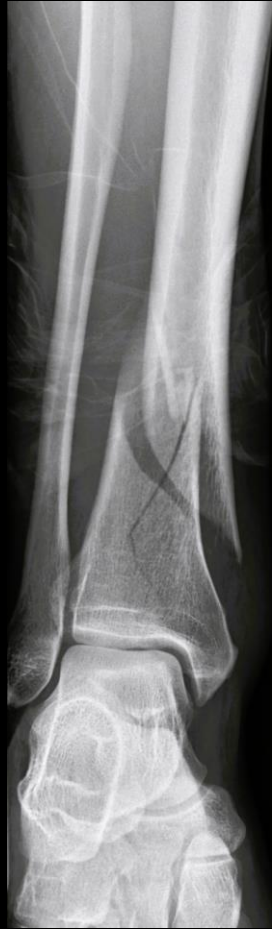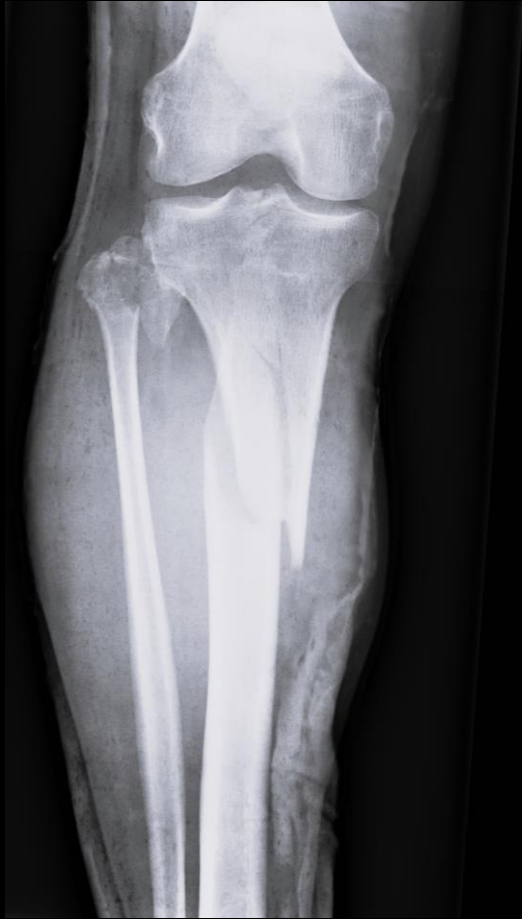[Acta Chir Orthop Traumatol Cech. 2012;79\(6\):499-505.](#)

[Tibial shaft fractures - management and treatment options. A review of the current literature.](#)

[Bode G¹](#), [Strohm PC](#), [Südkamp NP](#), [Hammer TO](#).

AO Basic - Nailing





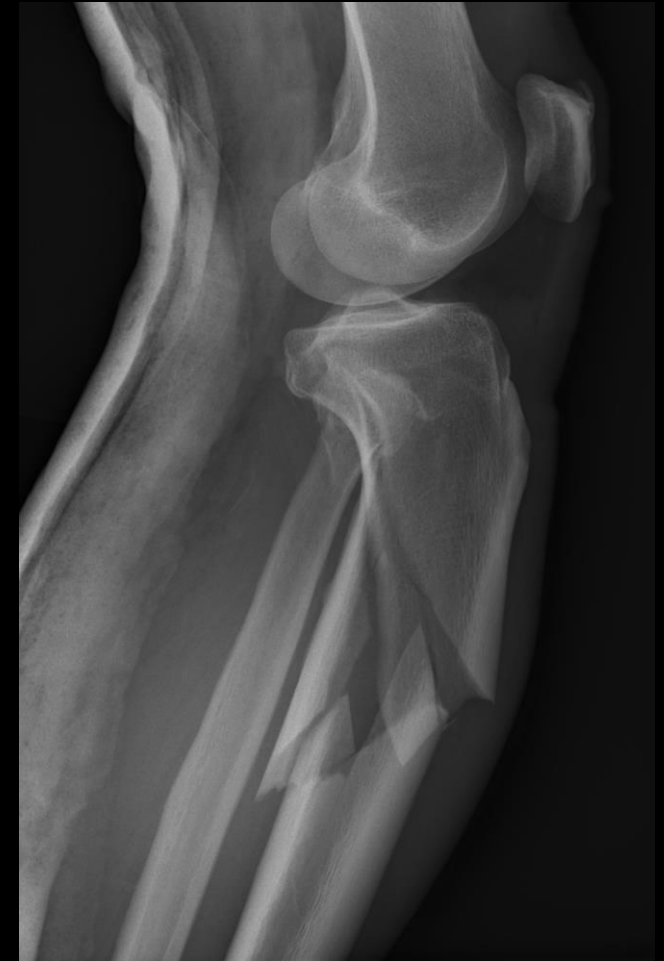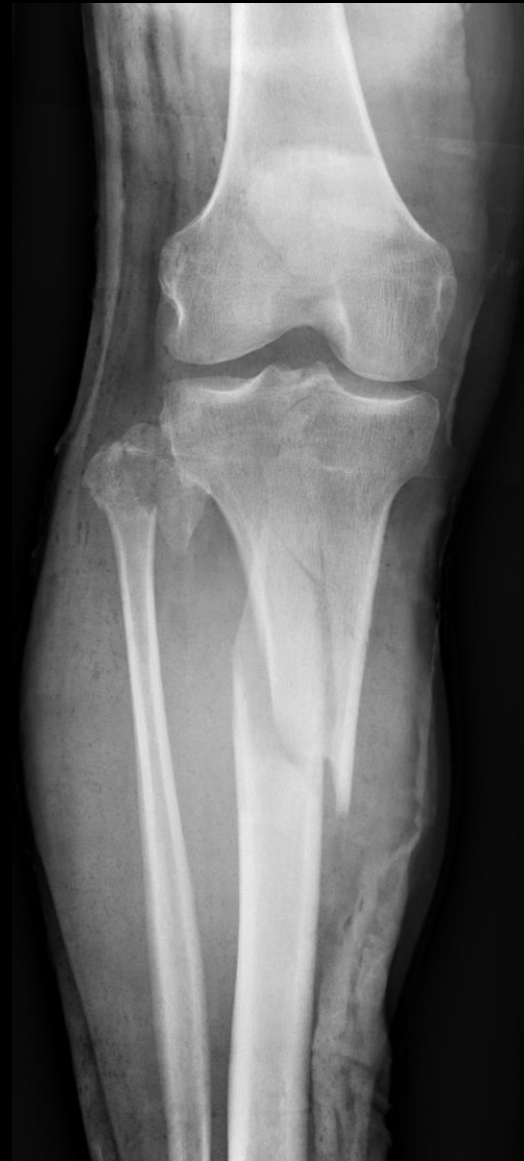Nail, plate, frame – is it all the same?

IMN is the golden standard in diaphyseal tibia fractures

”If you can’t nail a fracture, then make it nailable!”

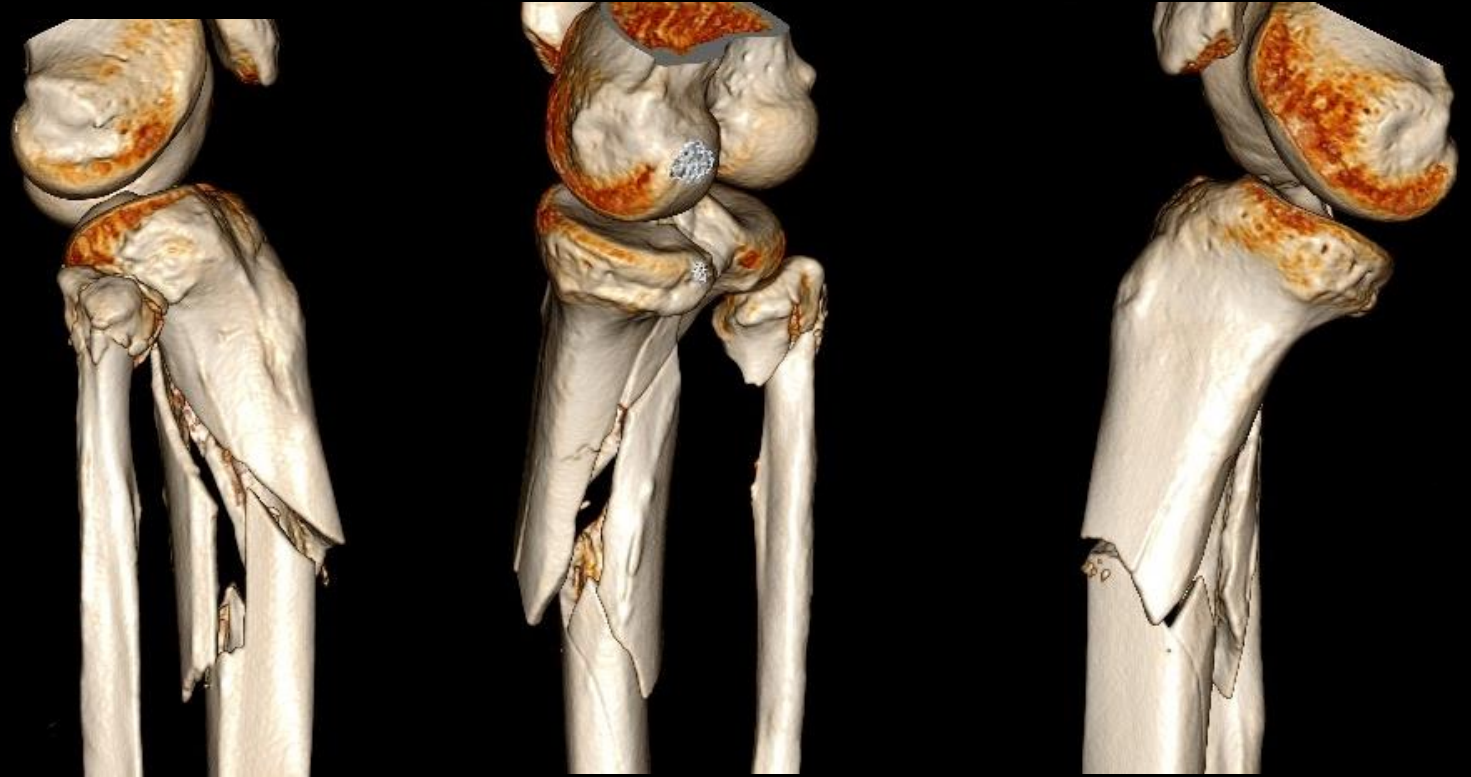Proximal Tibial Fracture

- 50 y/o male, in treatment with Methadone, otherwise healthy (no alcohol, no home help)
- Falls down the stairs
- Deformity of knee, closed injury
- NV intact
- PLAN?



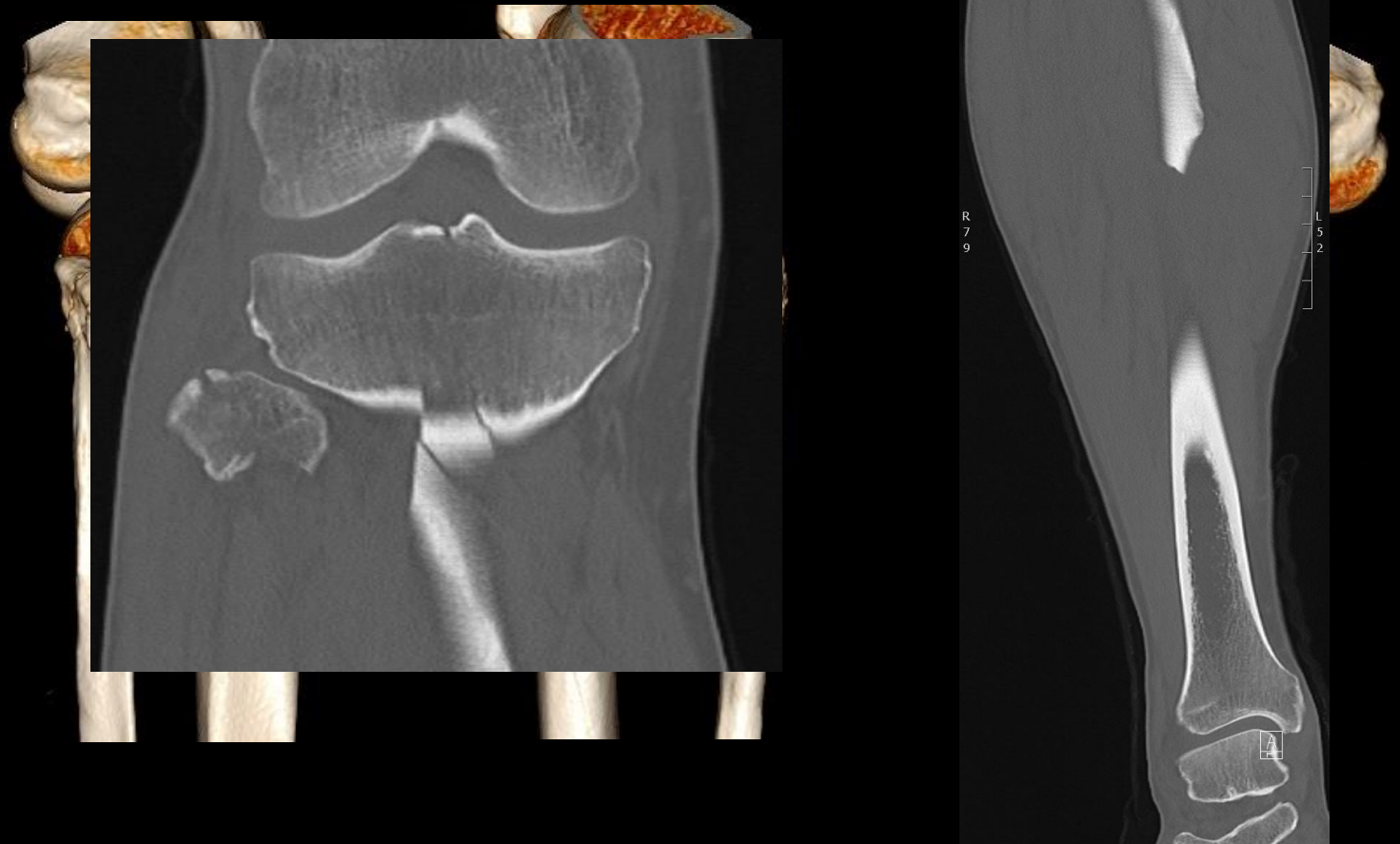
Proximal Tibial Fracture - Plan

- CT-scan (+ 3D)
- PLAN?



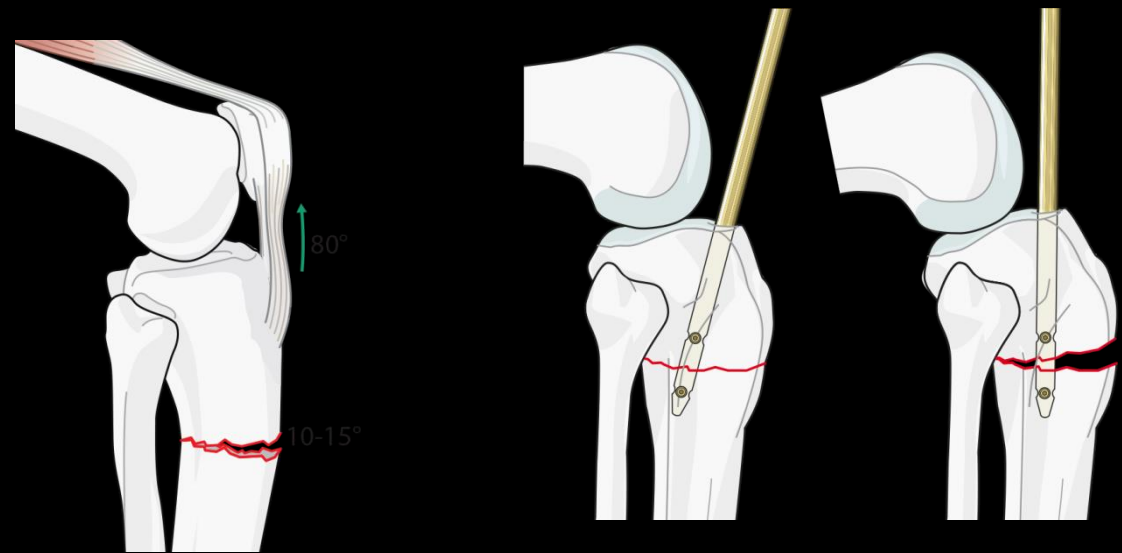
Proximal Tibial Fracture - Plan

- CT-scan (+ 3D)
- PLAN?

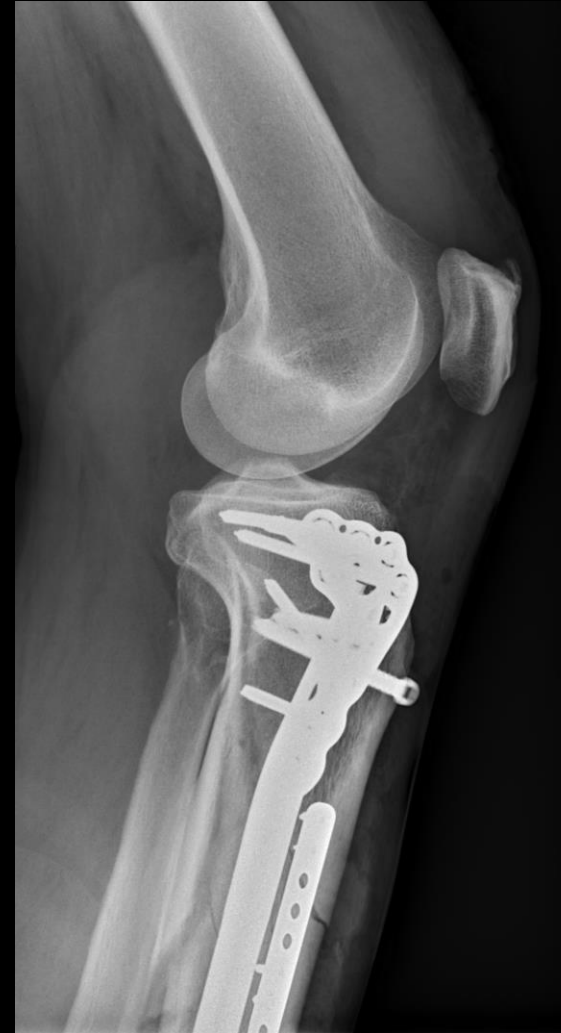
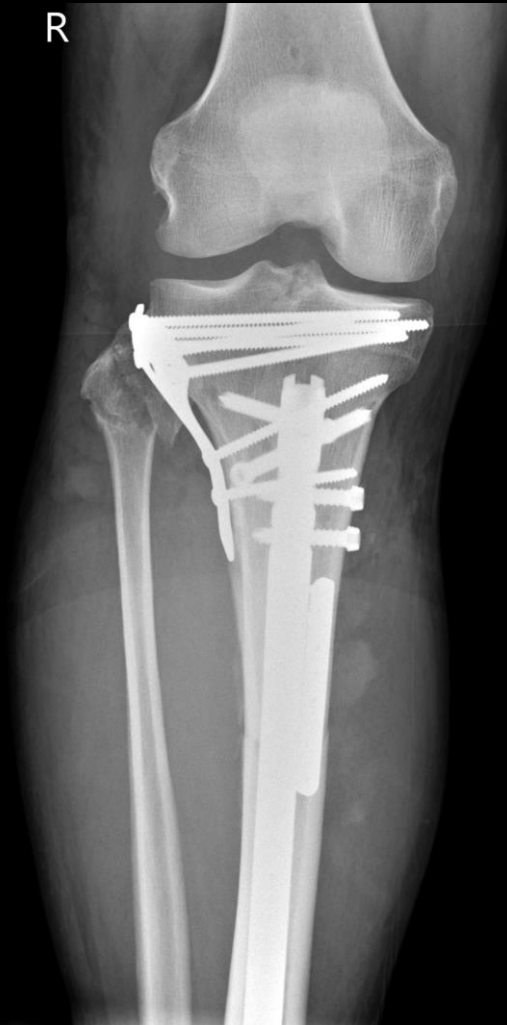
Proximal Tibial Fracture - Challenges

- Intraarticular component?
- Infra- vs. Suprapatellar Approach?

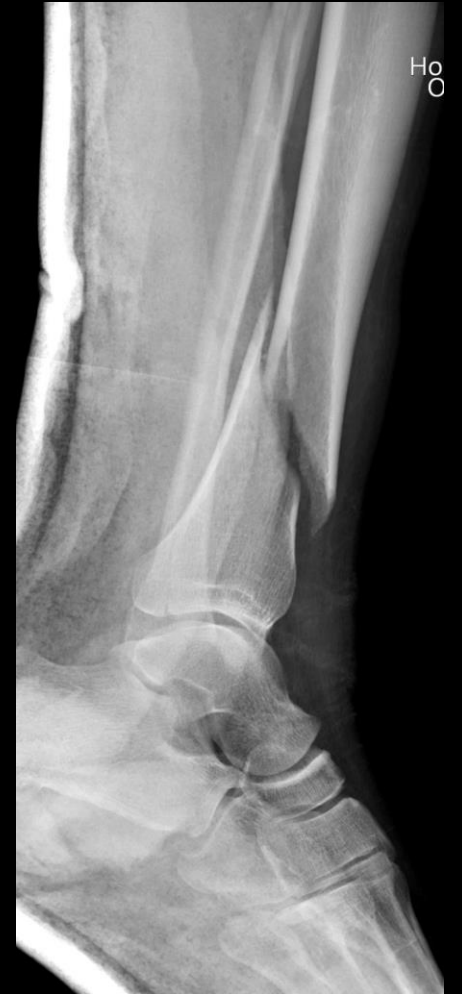
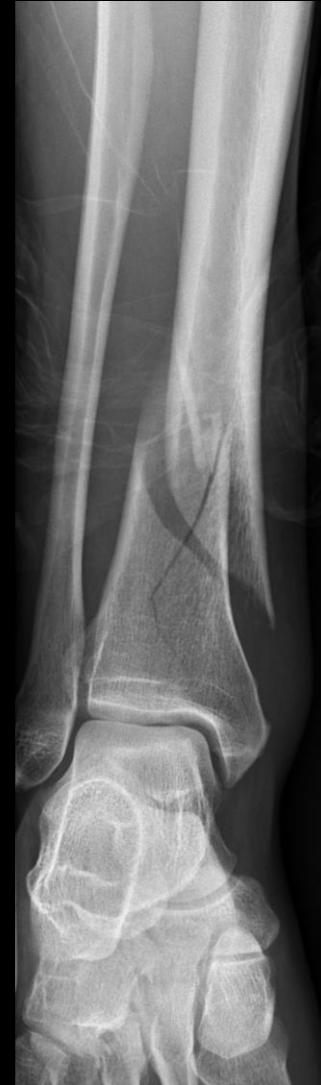
Proximal Tibial Fracture



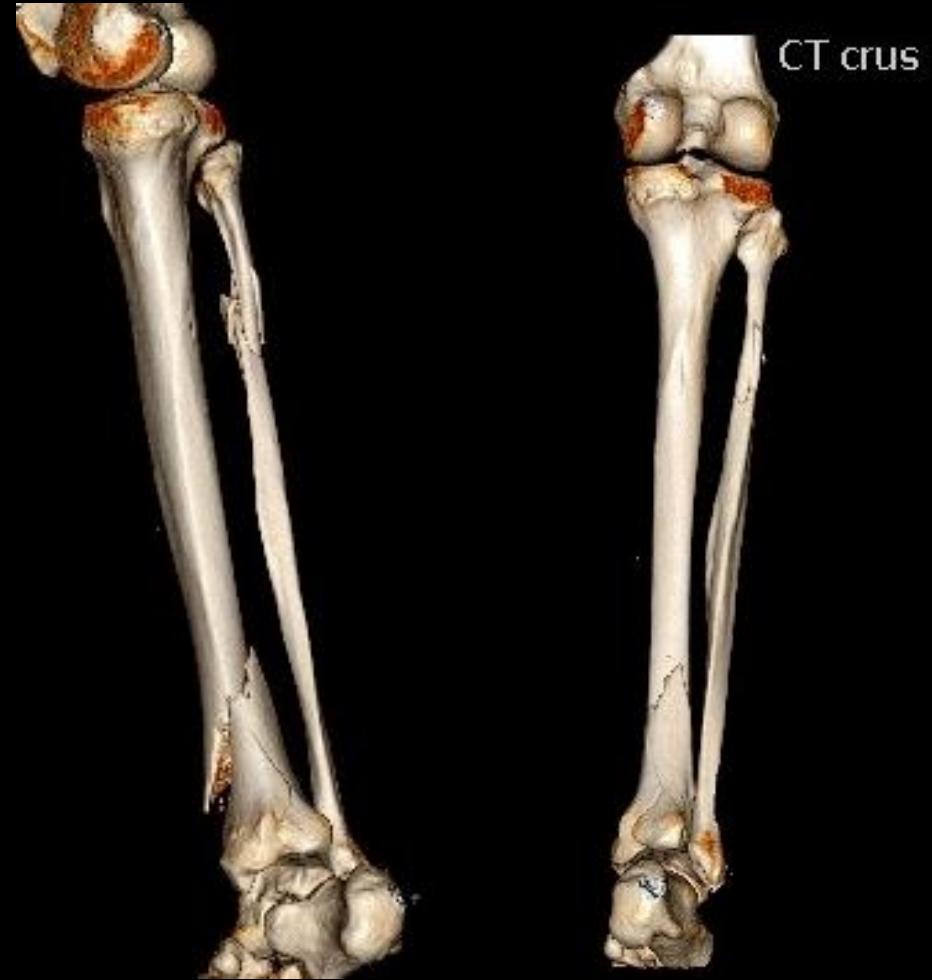Distal Tibial Fracture

- 38 y/o male, too much alcohol and party, otherwise healthy
- Less skilled in Parkour....
- Unable til weight bear, lower leg swollen
- NV intact
- PLAN?



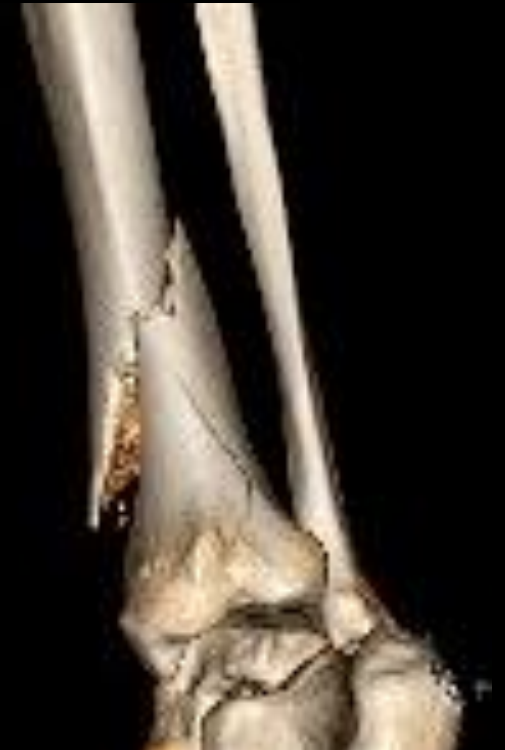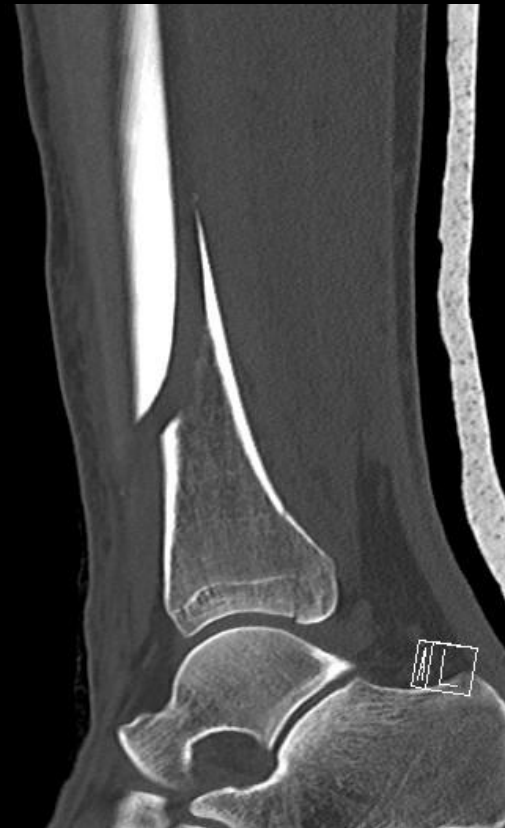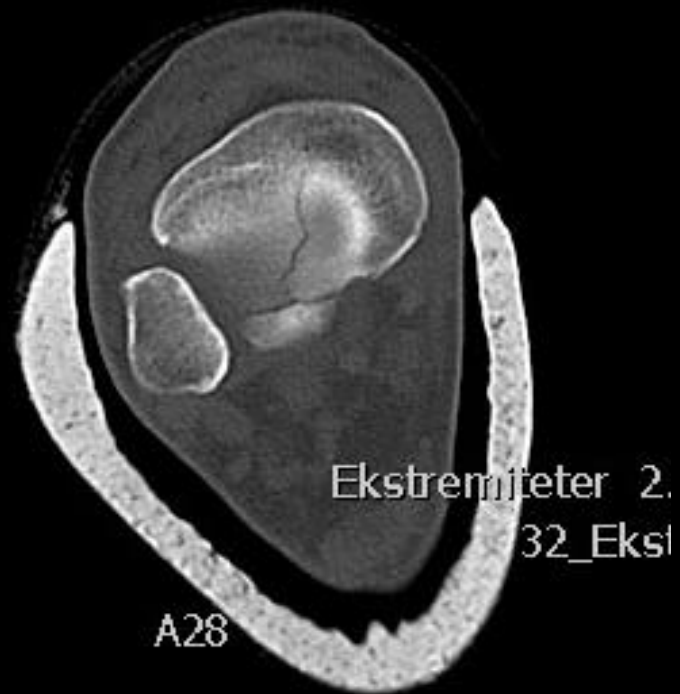Distal Tibial Fracture - Plan

- CT-scan (+ 3D)
- PLAN?



Distal Tibial Fracture - Plan

- CT-scan (+ 3D)
- PLAN?



Distal Tibial Fracture - Challenges

- Intraarticular component?
- Infra- vs. Suprapatellar Approach?

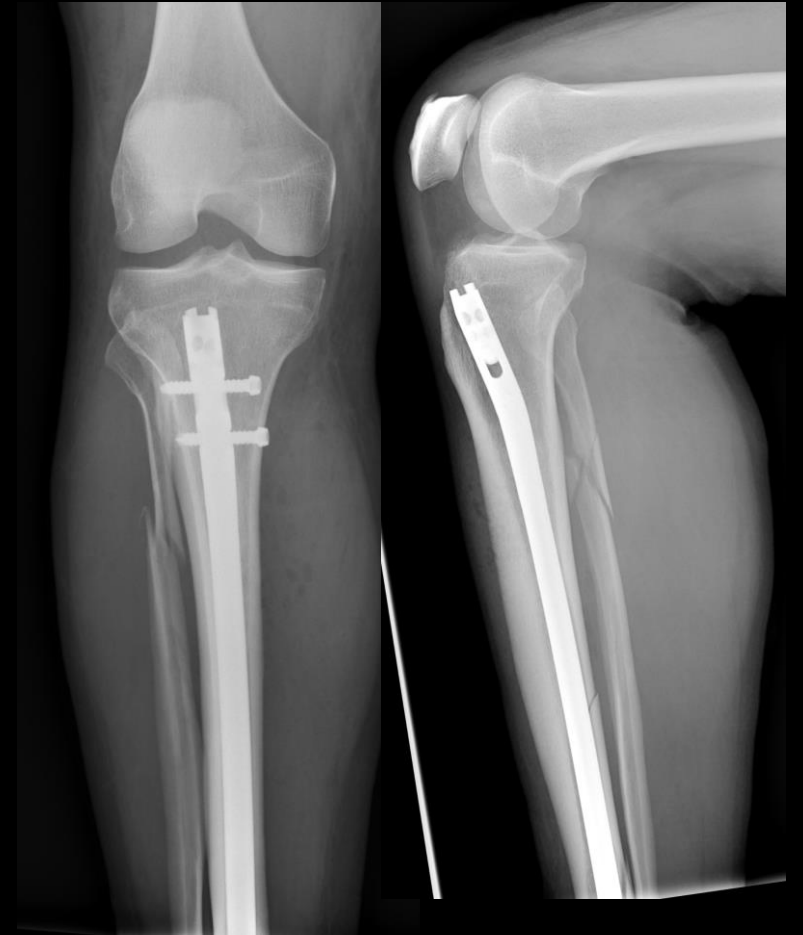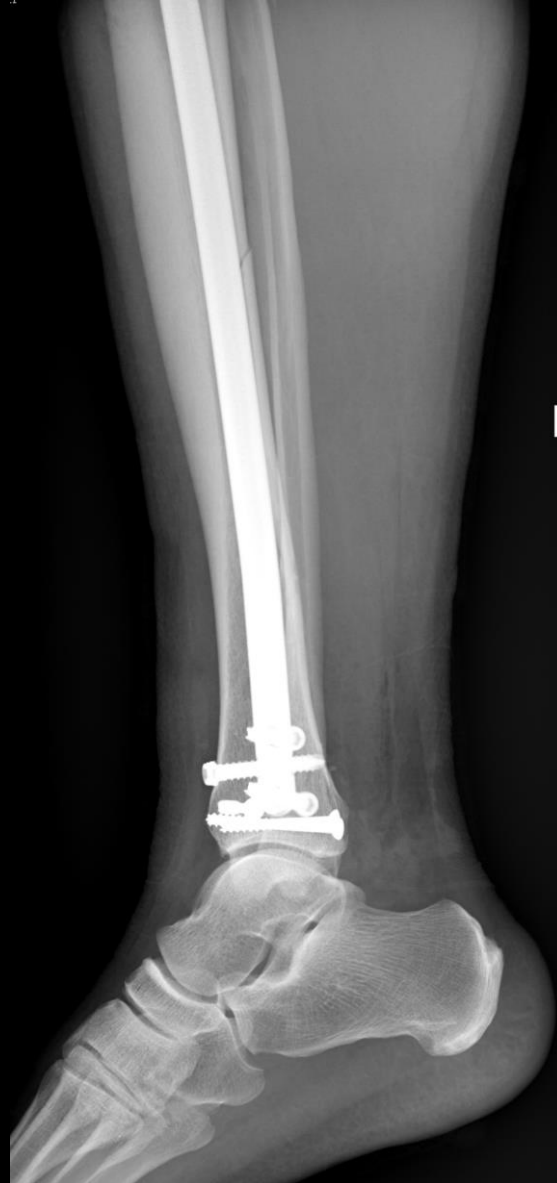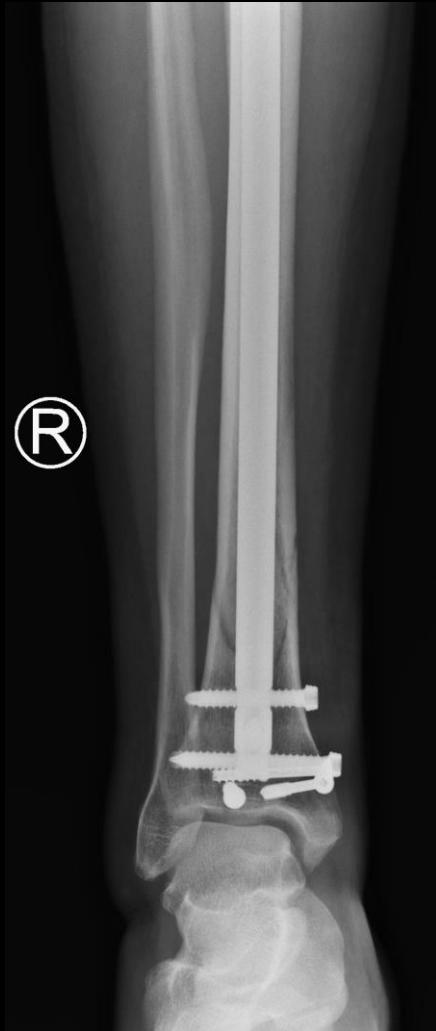“Easier positioning, maintenance of reduction, ease of intraoperative fluoroscopy, more anatomic starting trajectory, decreased malreduction rates, and possible decrease in anterior knee pain are all benefits of suprapatellar nailing”

Suprapatellar Tibial Nailing.

Busel GA, Mir H.

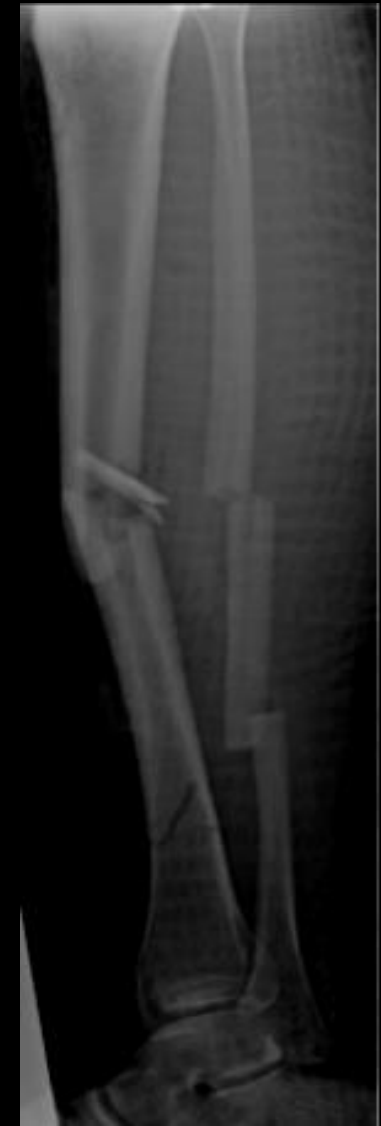Orthop Clin North Am. 2019 Jul;50(3):289-295. doi: 10.1016/j.ocl.2019.03.007.

Distal Tibial Fracture



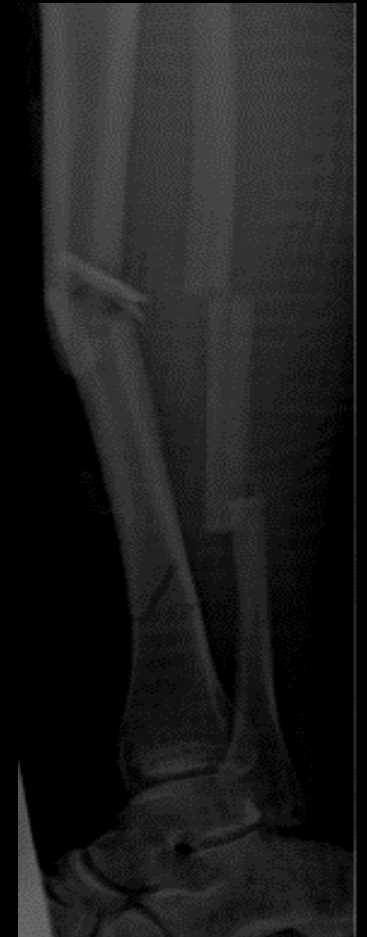Segmental Tibial Fracture

- 44 y/o female, healthy
- Crash on scooter
- Bruising and deformity of left lower extremity
- NV intact
- PLAN?



Segmental Tibial Fracture - Plan

- CT-scan?
- Open or closed fracture?

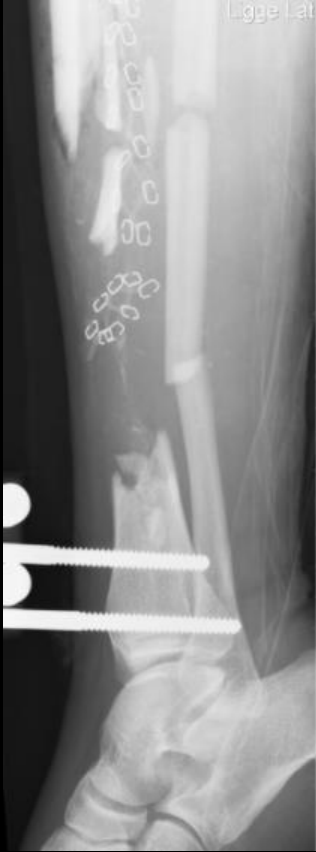
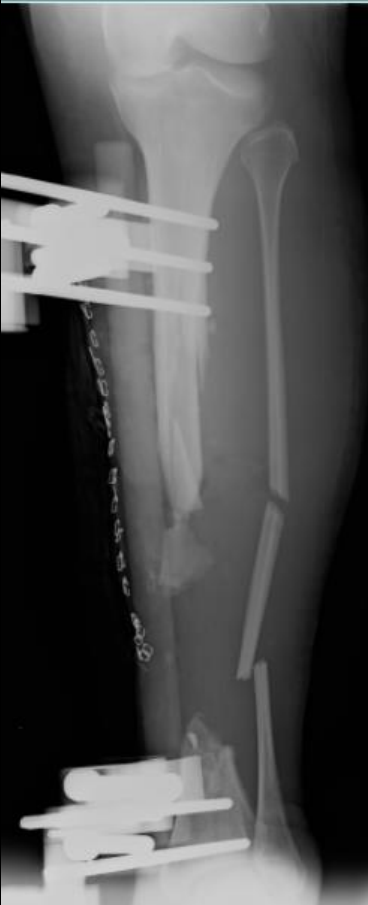
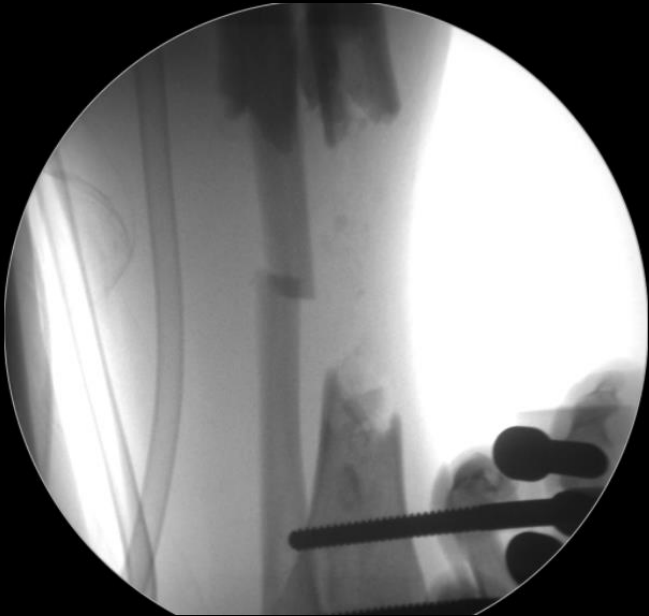The management of segmental tibial shaft fractures: A systematic review

[Samuel E. McMahon](#) [Zoe E. Little](#) [Toby O. Smith](#) [Alex Trompeter](#) and [Caroline B. Hing](#) *Injury*, 2016-03-01, Volume 47

- IMN til lukkede frakturer
- CEF til åbne frakturer

Segmental Tibial Fracture - Challenges



Segmental Tibial Fracture - Challenges

> [Injury](#). 2015 Apr;46(4):643-8. doi: 10.1016/j.injury.2015.01.014. Epub 2015 Jan 16.

Does it really spin? Intra-medullary nailing of segmental tibial fractures--a cadaveric study

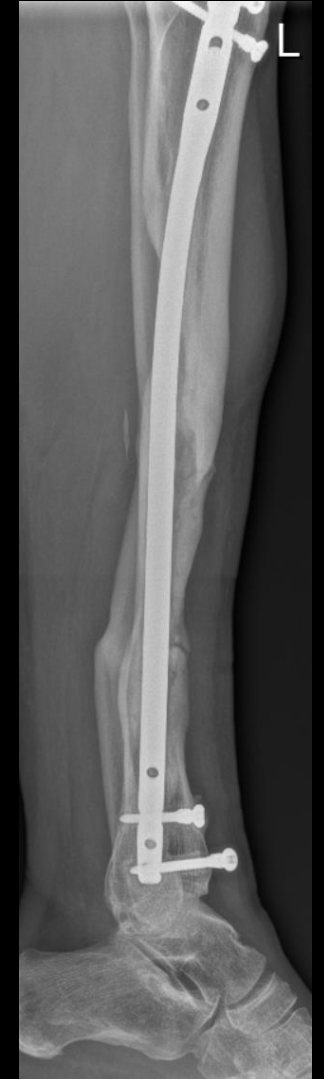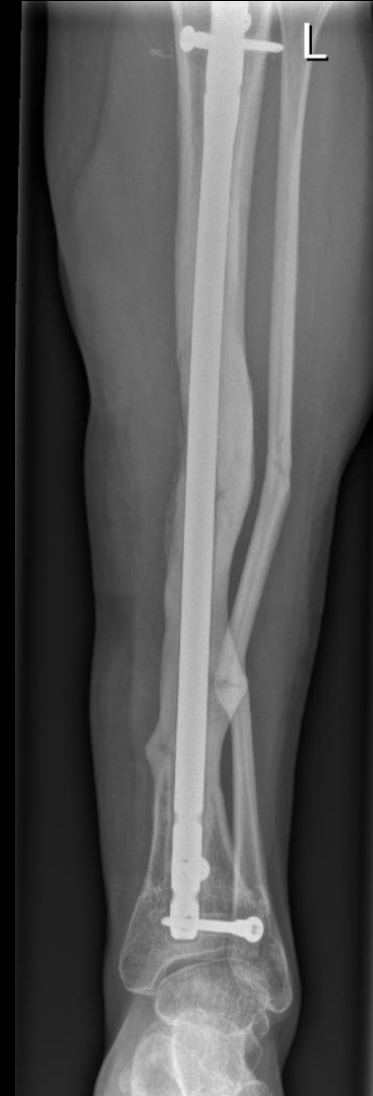Mateen H Arastu ¹, Brendan Sheehan ², Elizabeth Oddone Paolucci ³, Richard E Buckley ⁴

Reaming is a major risk factor for rotational displacement of segmental tibial fractures irrespective of the degree of soft tissue stripping. Long diaphyseal segmental fractures rotate more than shorter segmental fractures

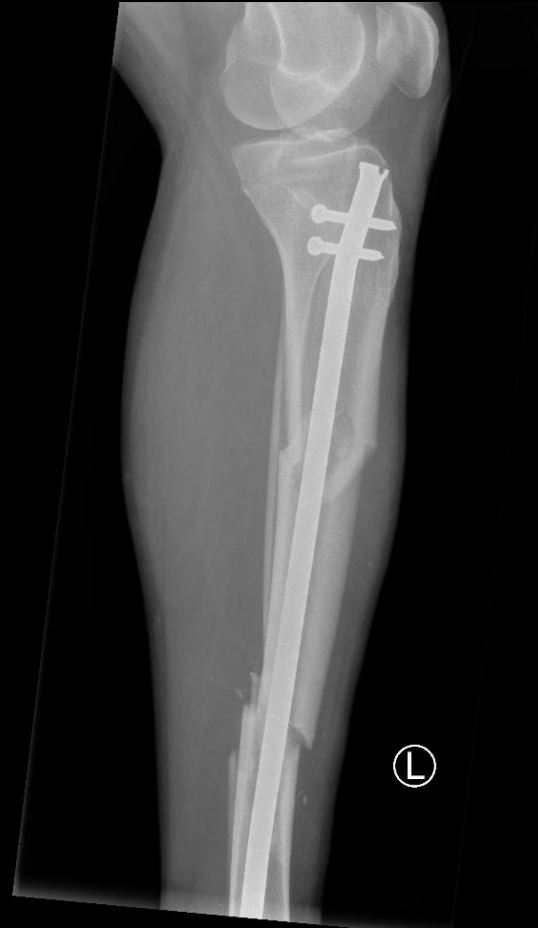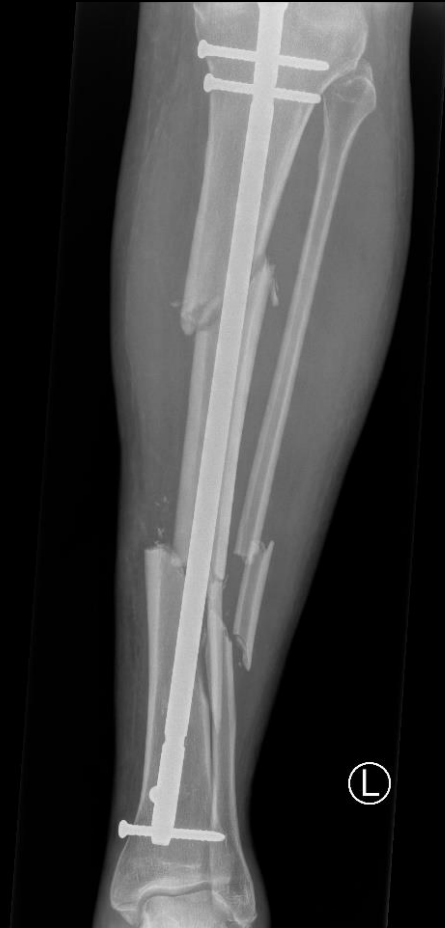Segmental Tibial Fracture - Challenges

After 5 years and several visits to hospital
she can stand and walk short distances

Amputation is an option....



Segmental Tibial Fracture - Challenges



Summary

- Proximal, Distal and Segmental Tibial Fractures are challenging
- If you can't nail a fracture, then make it nailable (if it makes sense)
- IMN have biomechanical advantages over plates
- Be prepared – perform pre-op CT of all proximal and distal tibia fractures
- Which adjuncts do I have in the toolbox
 - External fixator, Pointed Bone Forceps, K-wires/Screws (blocking), Plates