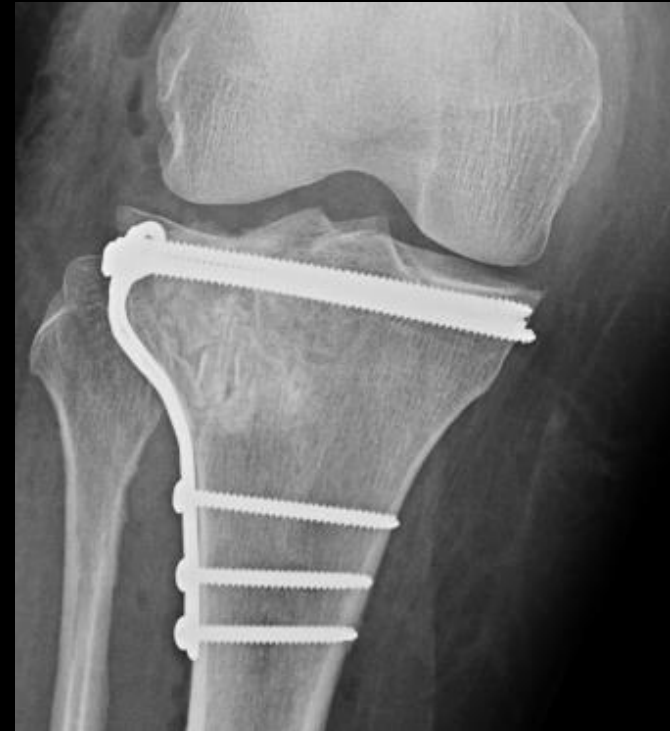
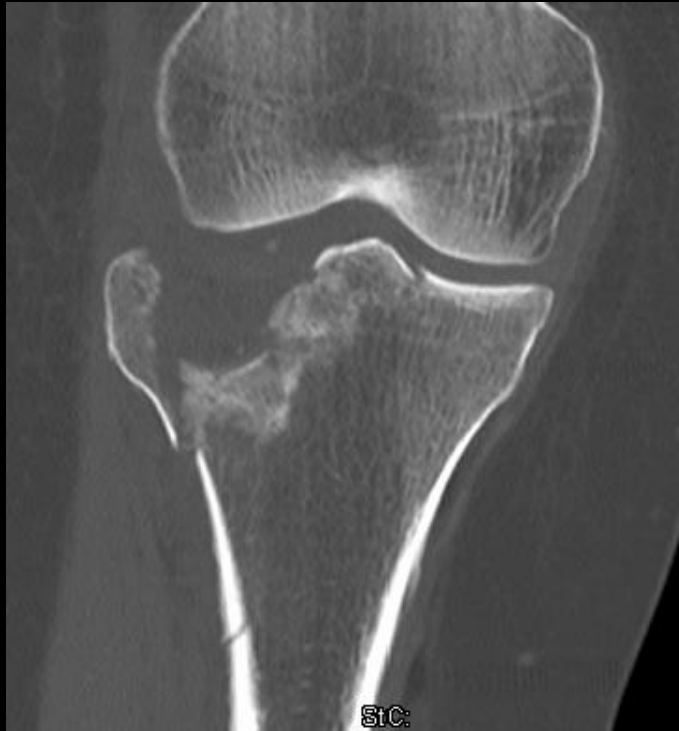
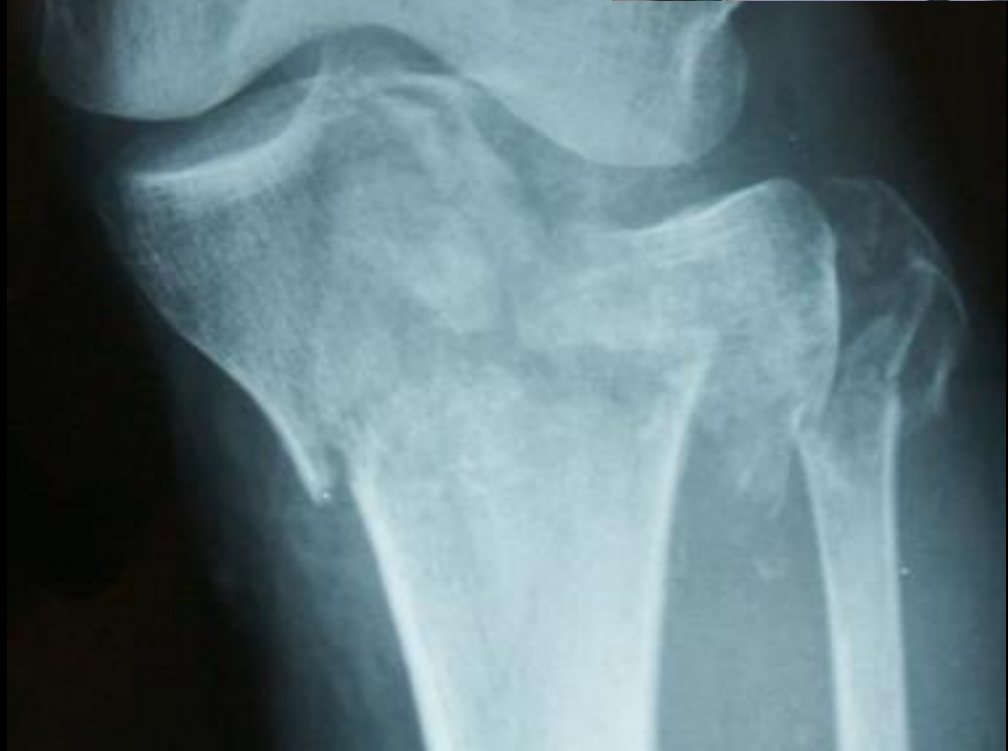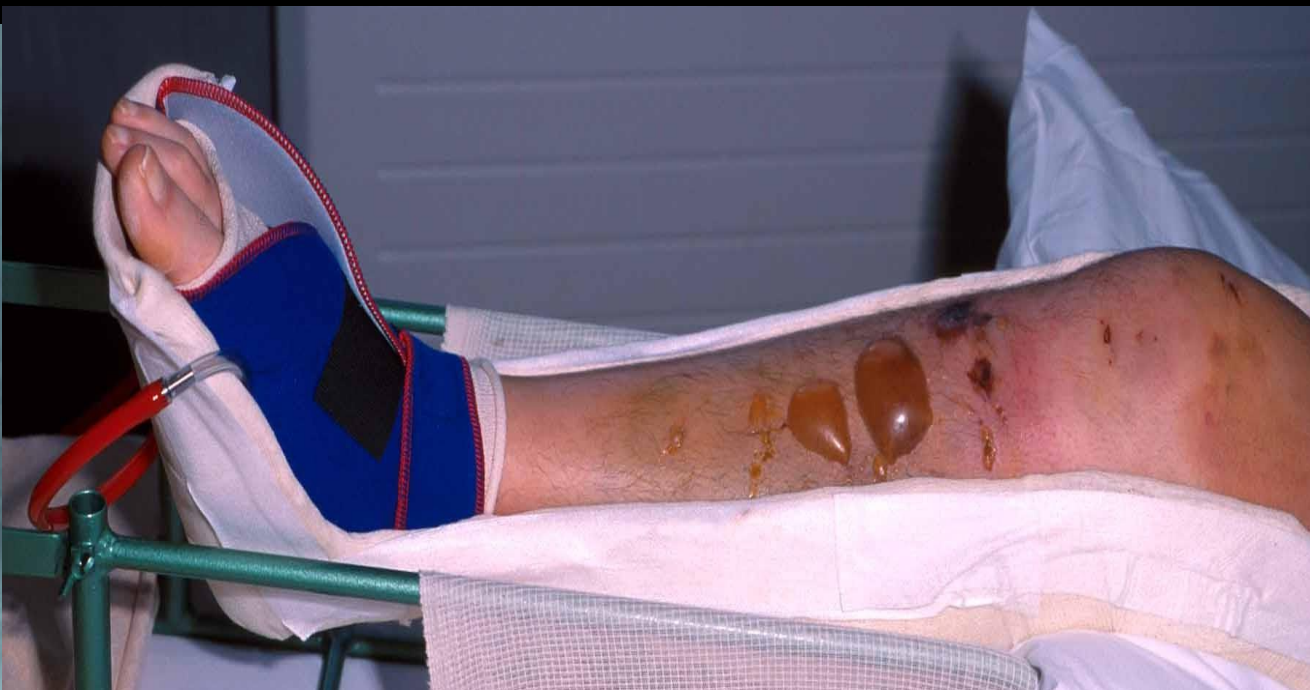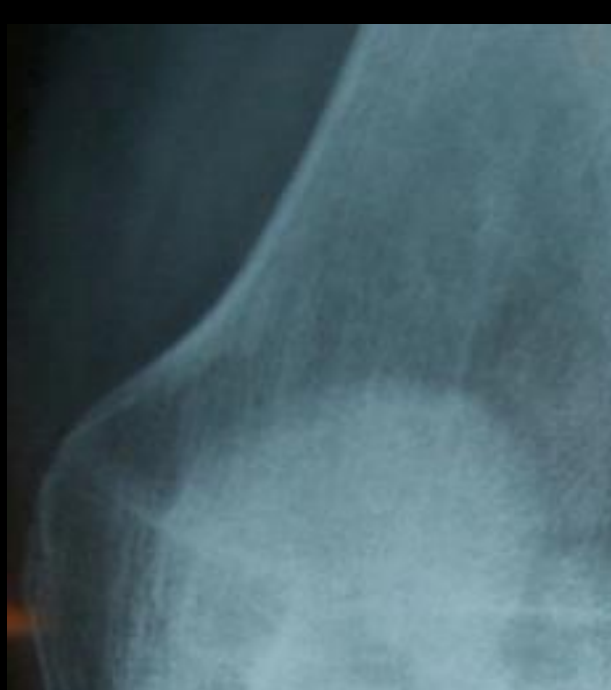# Tibia plateau fraktur

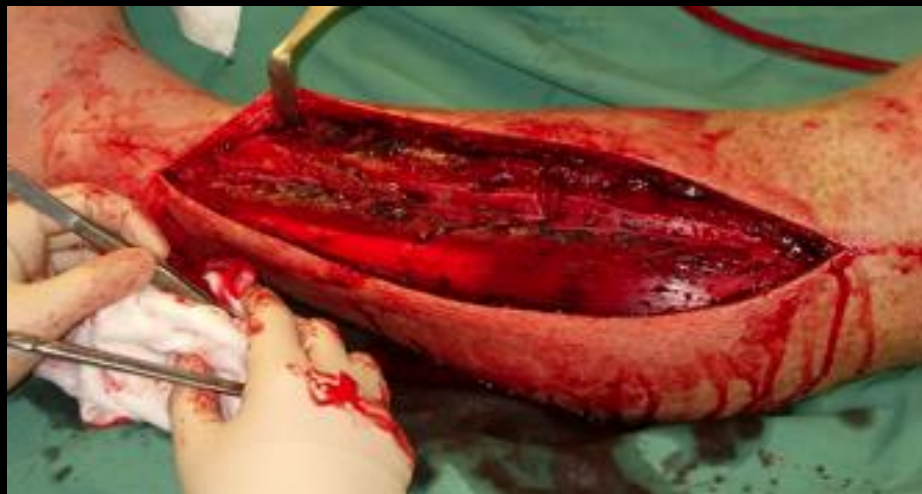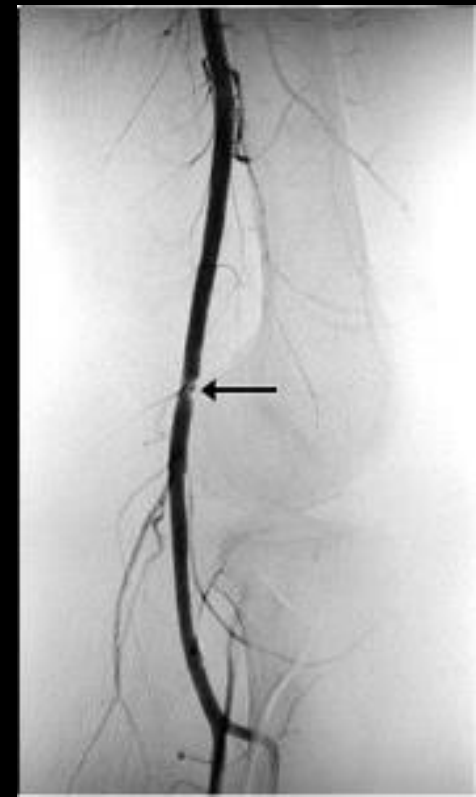
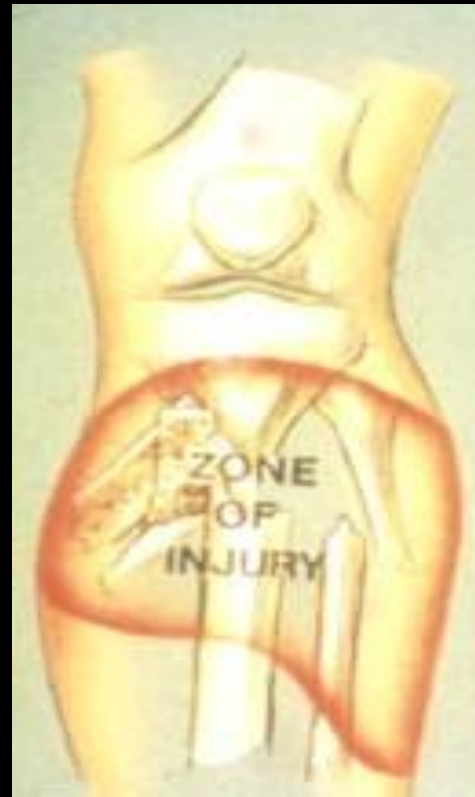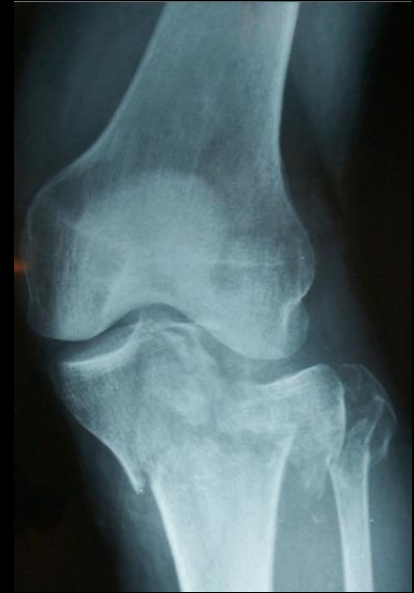Frakturtyper, behandling og kirurgiske adgange






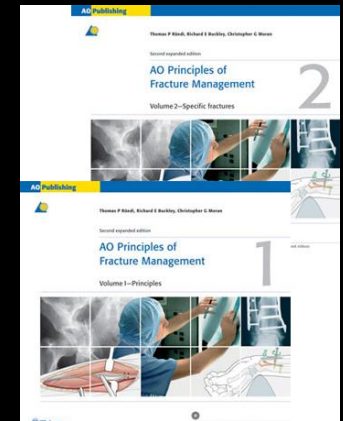
# Bløddele !

- Tyndt bløddelslag
- Høj/lav energi
- Neurovaskulære forhold
- Compartment syndrom





# Bløddele !



Thomas P Rüedi, MD, Professor, Founding and honorary member of the AO Foundation

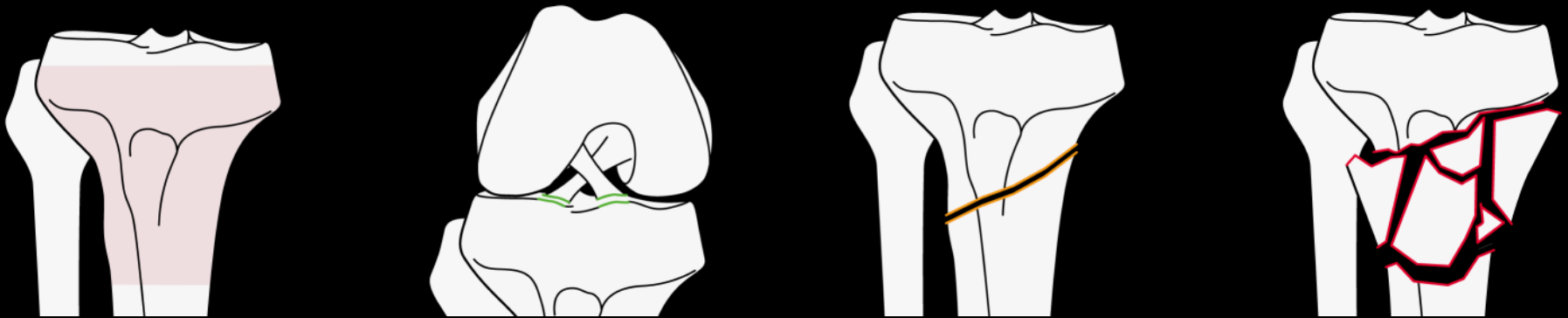
*“a fracture first and foremost is a soft-tissue injury, in which the bone happens to be broken”*

# Etiology

- In low-energy trauma the problem is:
  - **Mechanical**—fixation in osteoporotic bone
- In high-energy trauma the problem is:
  - **Biological** and associated with damage to the soft tissues

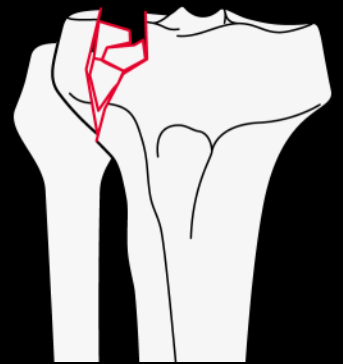
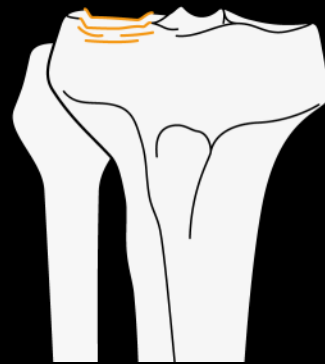
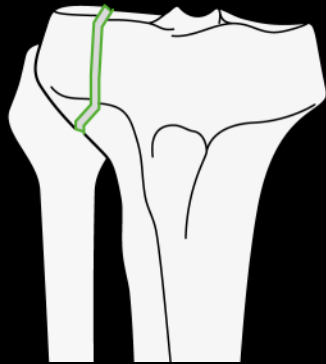
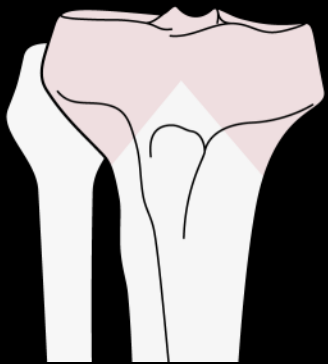
# Classification of proximal tibial fractures (41-A)

- A: Ekstraartikulær
  - A1: avulsion
  - A2: metaphyseal simple
  - A3: metaphyseal multifragmentær



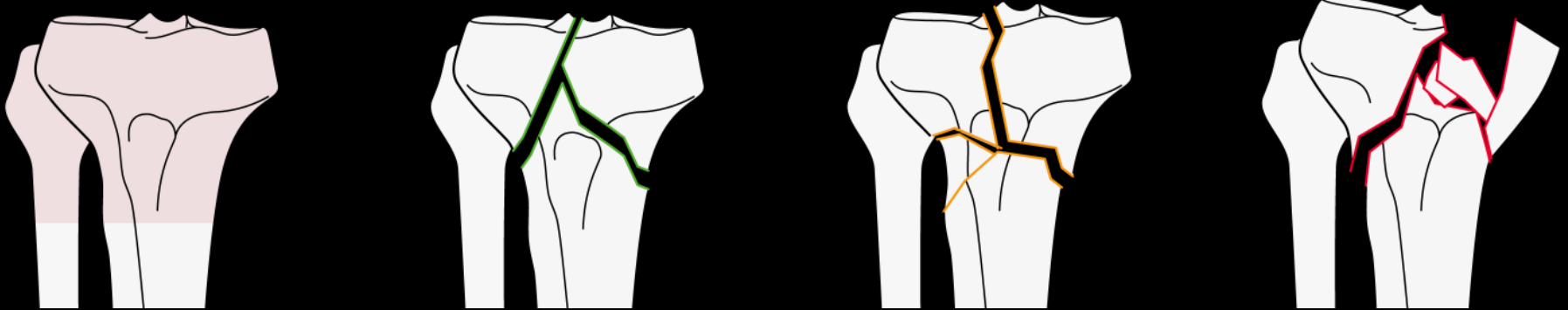
# Classification of proximal tibial fractures (41-B)

- B: Partial articular
  - B1: pure split
  - B2: pure depression
  - B3: split-depression



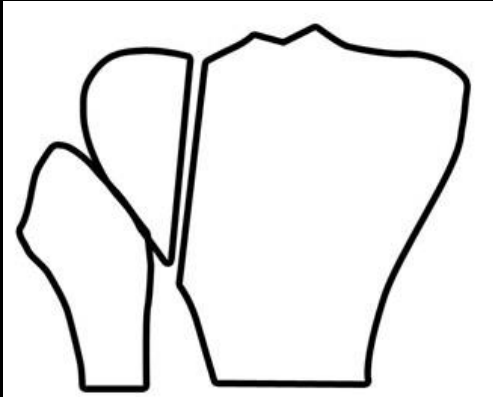
# Classification of proximal tibial fractures (41-C)

- C: Complete articular
  - C1: articular simple, metaphyseal simple
  - C2: articular simple, metaphyseal multifragmentær
  - C3: articular multifragmentær

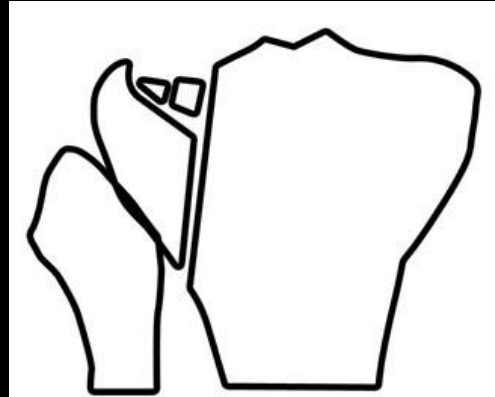




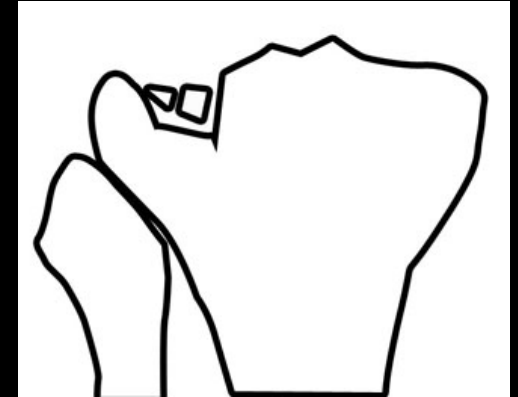
# Schatzker



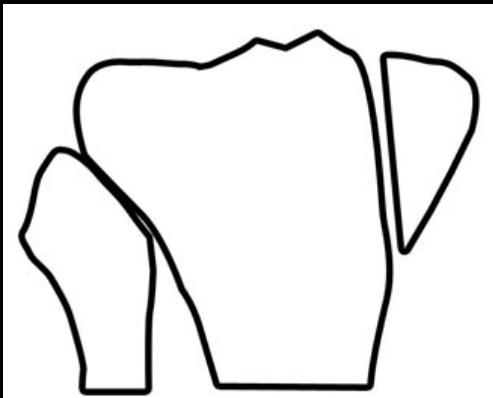
Schatzker I



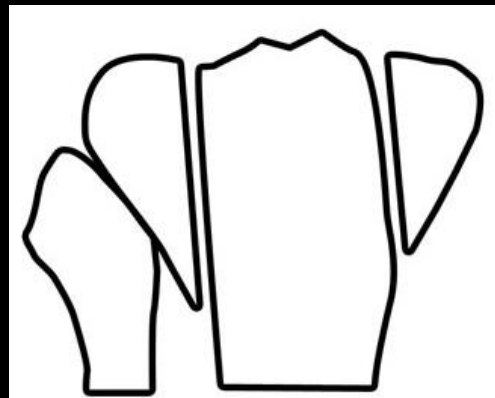
Schatzker II



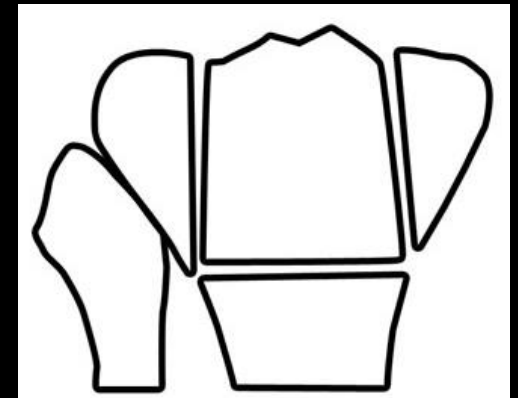
Schatzker III



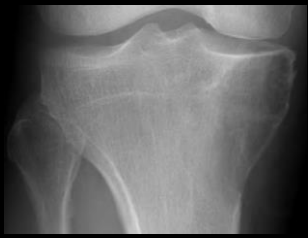Schatzker IV



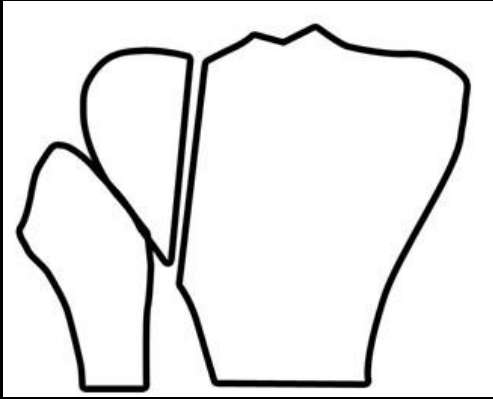
Schatzker V



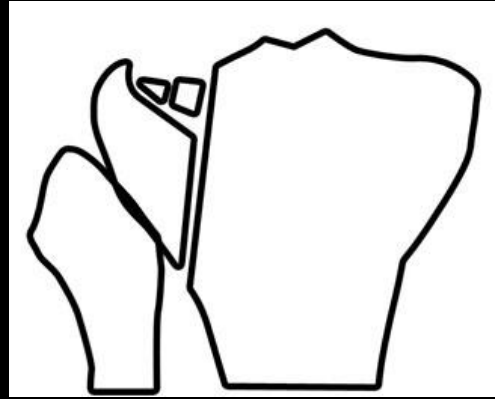
Schatzker VI



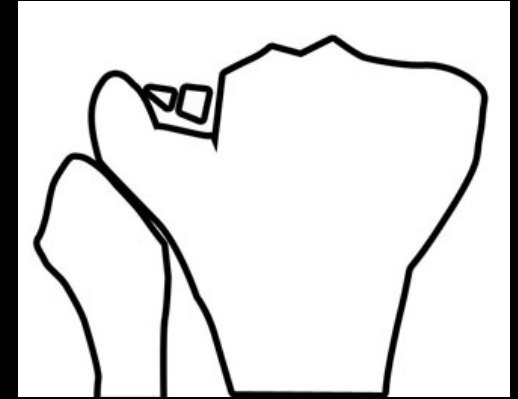
# Schatzker



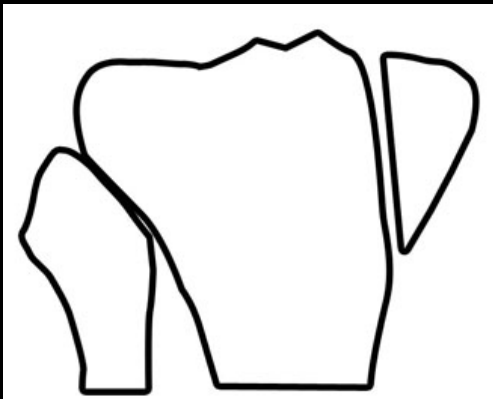
Schatzker I



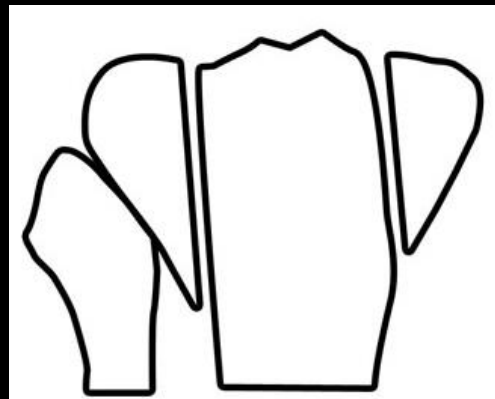
Schatzker II



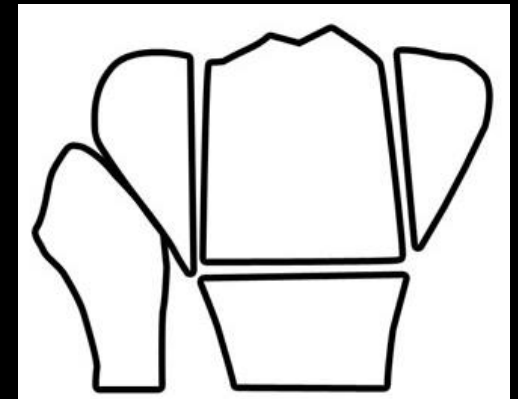
Schatzker III



Schatzker IV

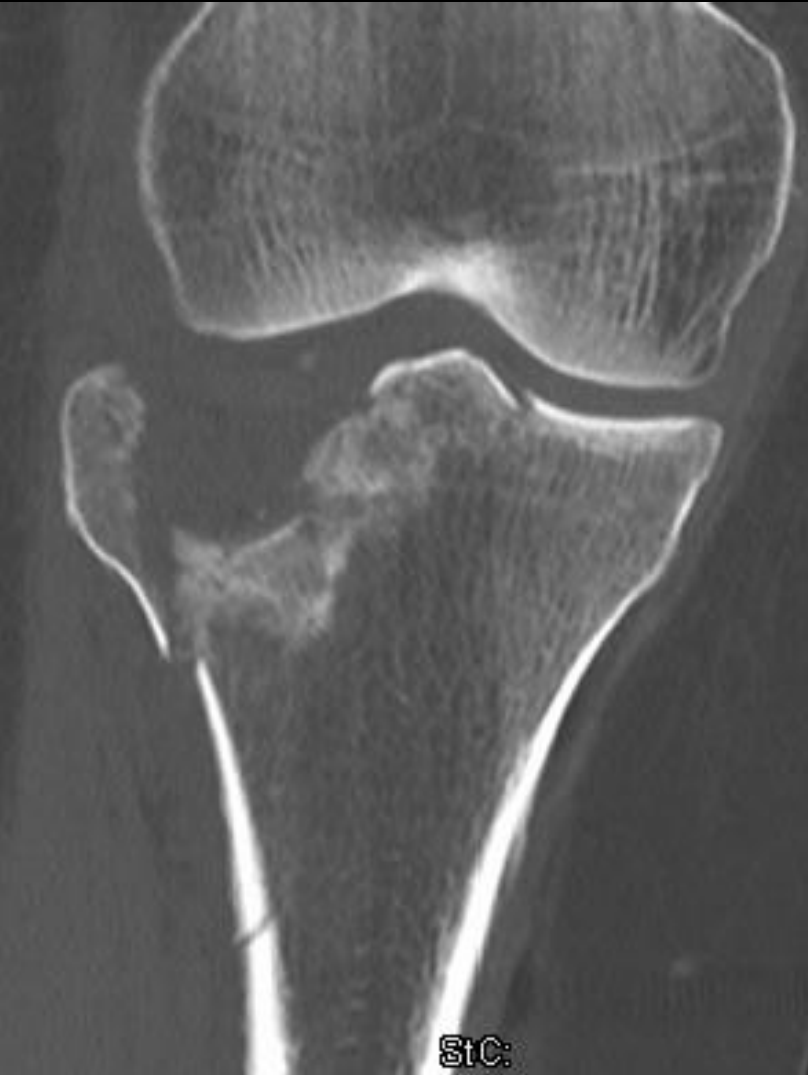

Schatzker V

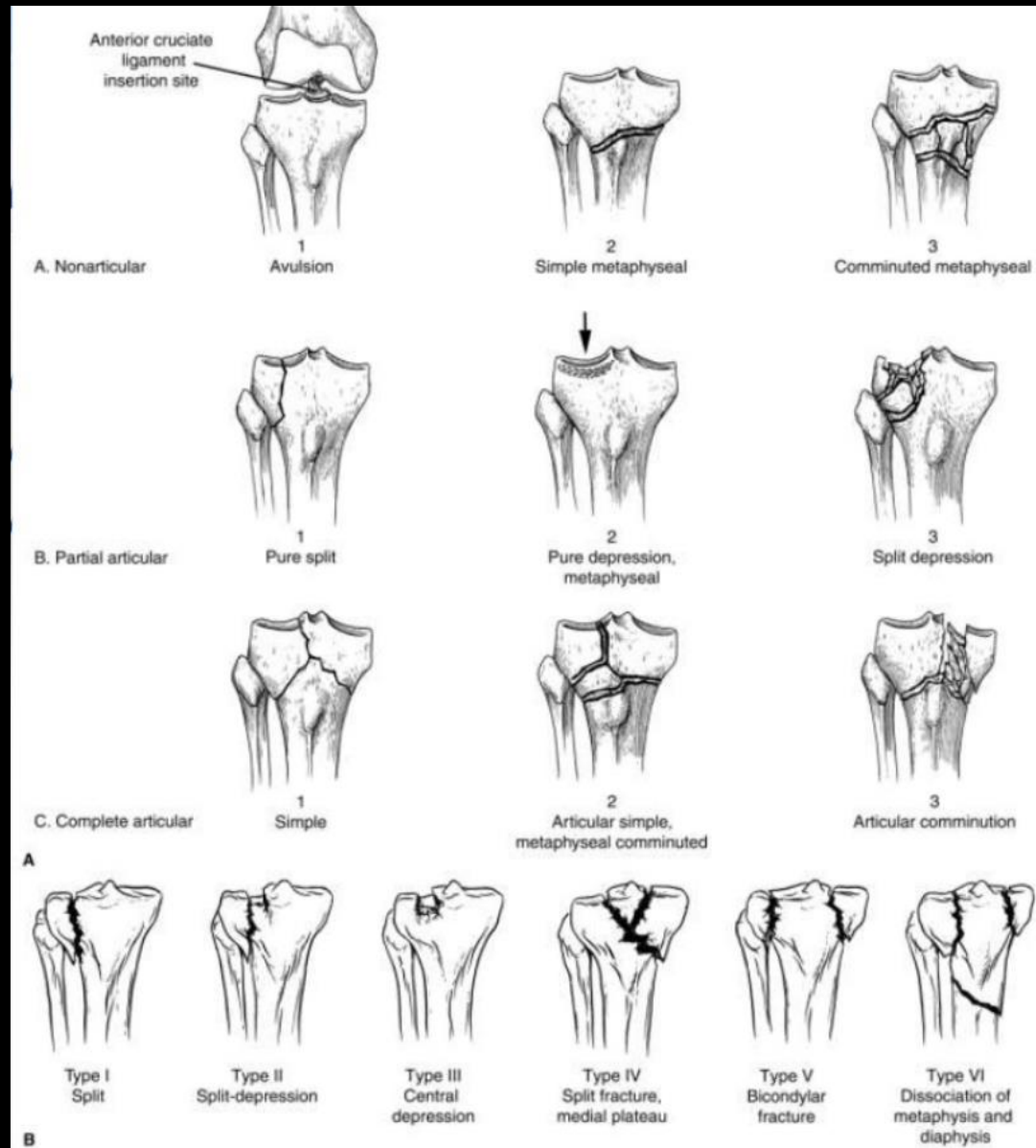


Schatzker VI

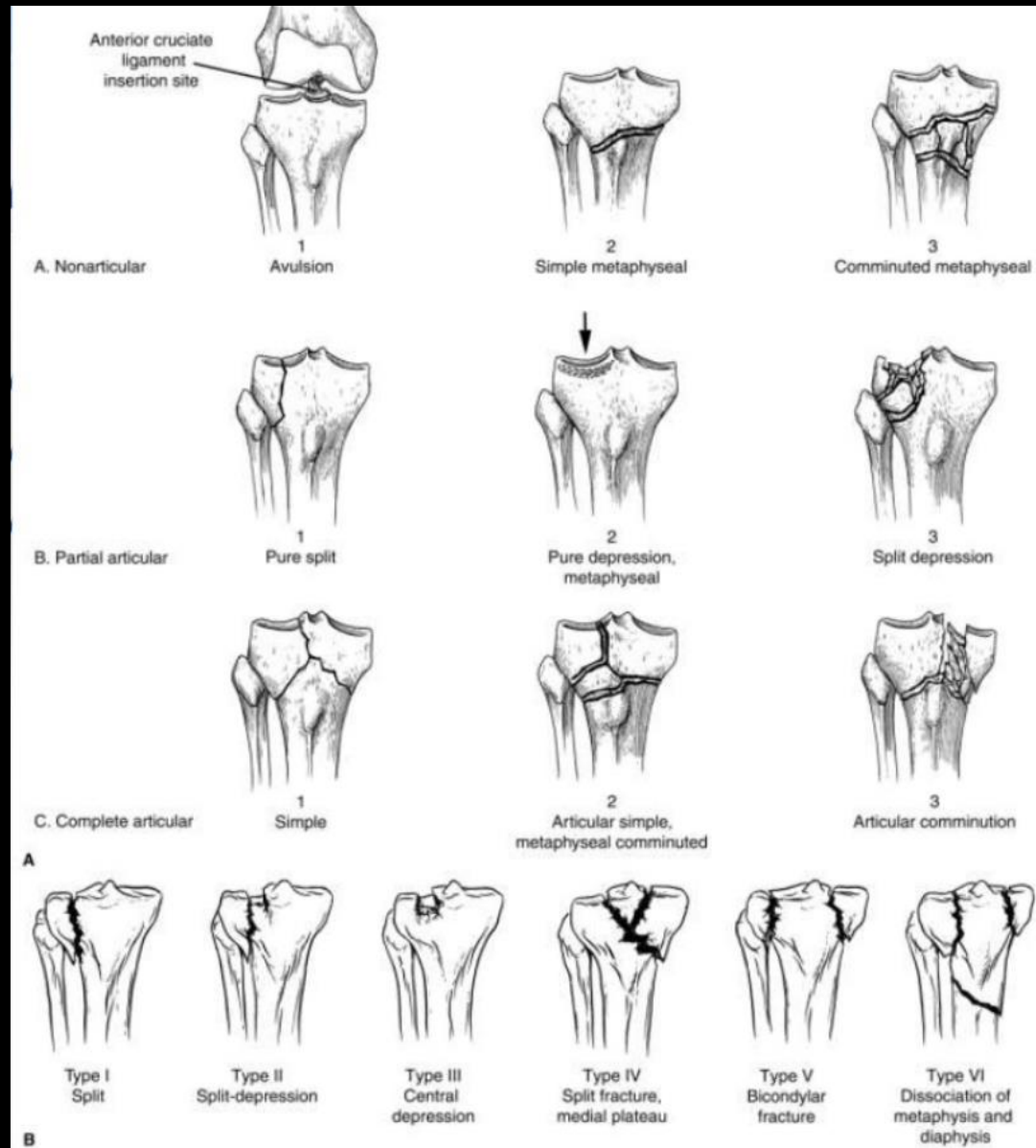
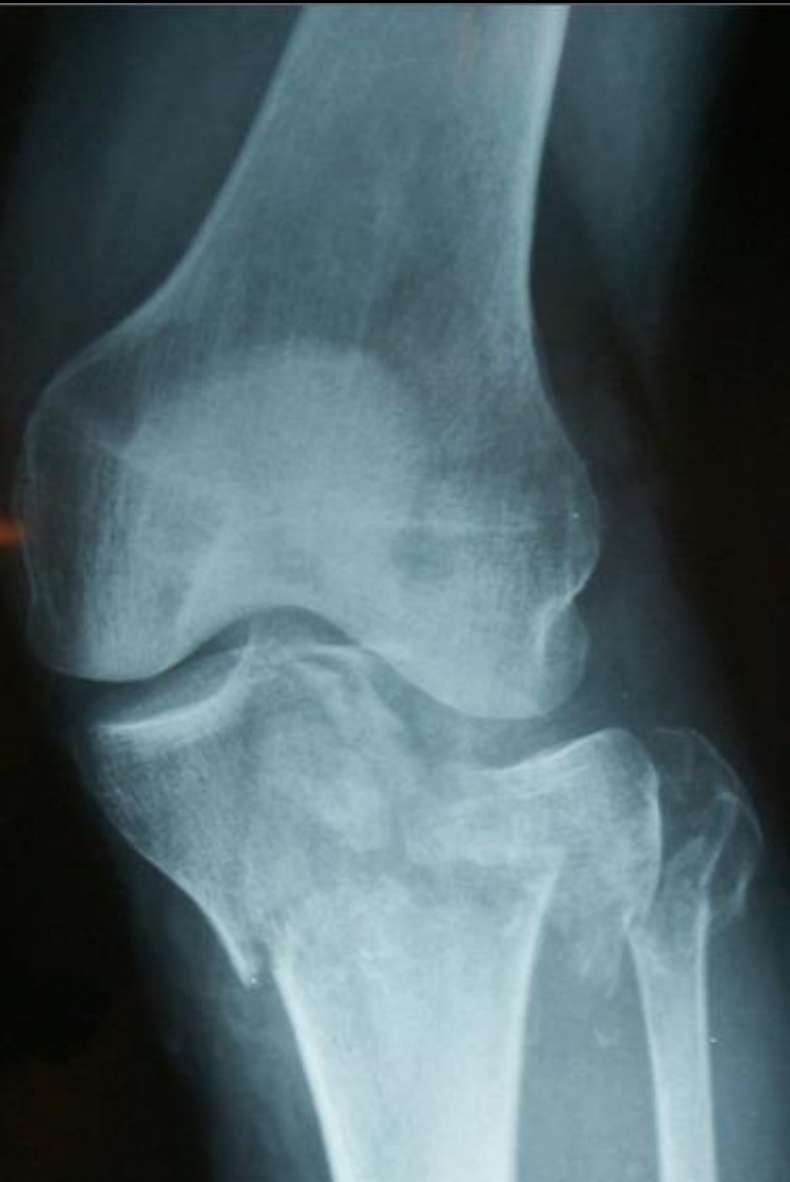# Hvilken type?



St C:

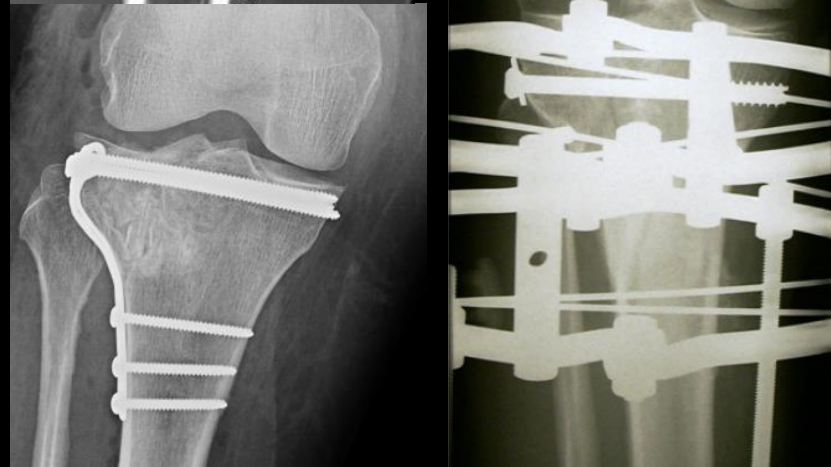
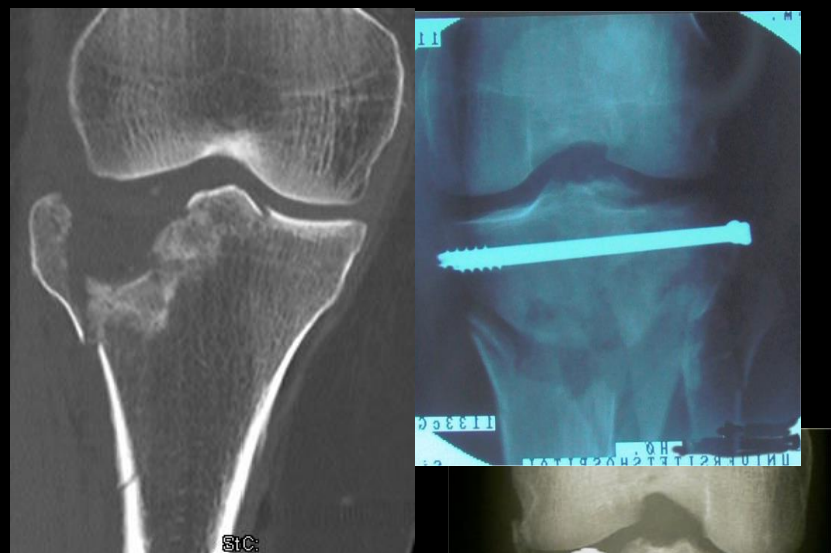
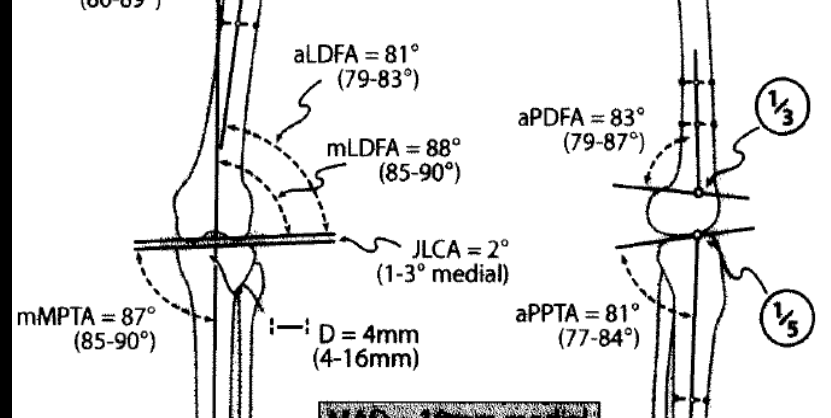


# Hvilken type?

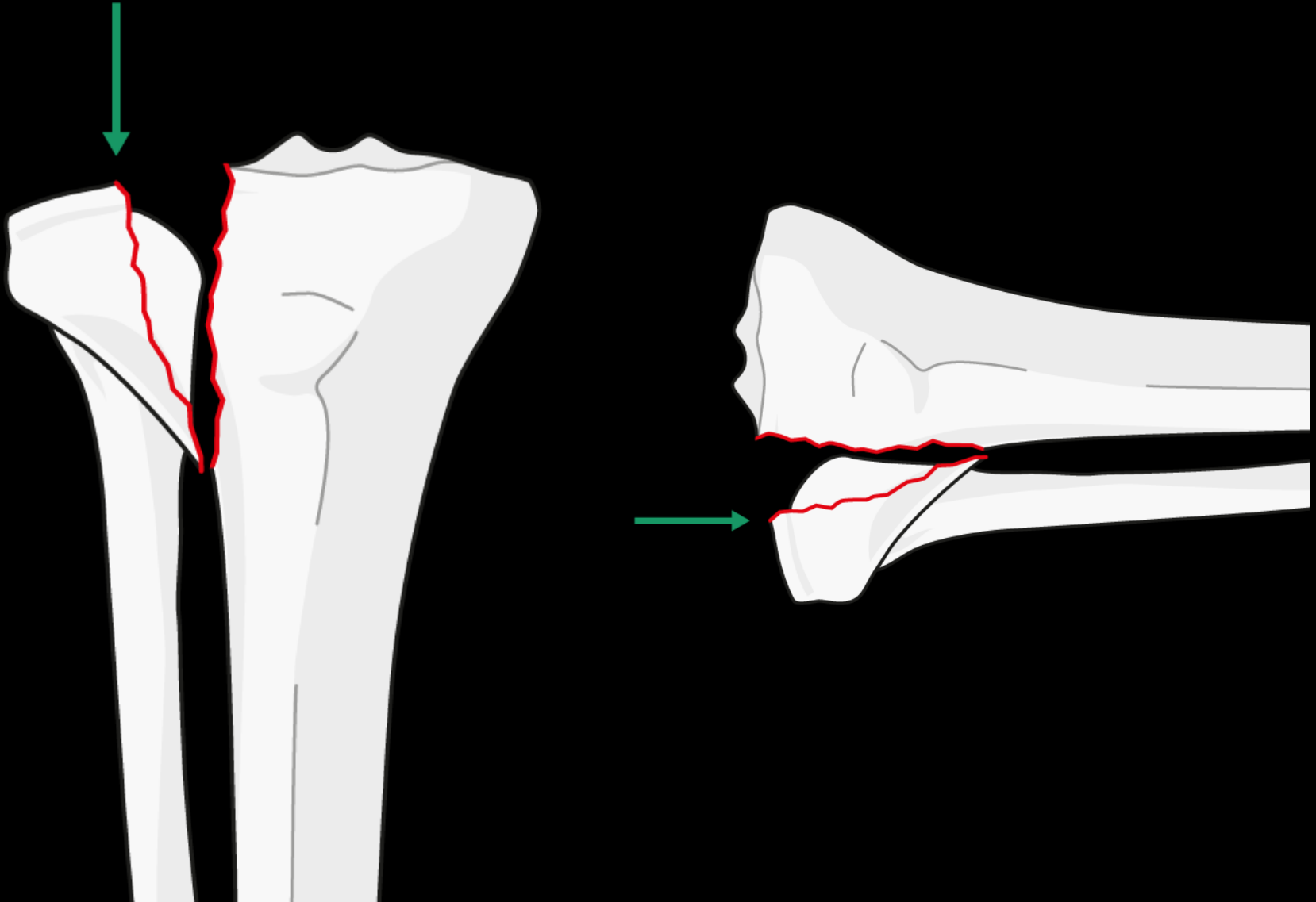


# Behandlingsmål proximal tibia

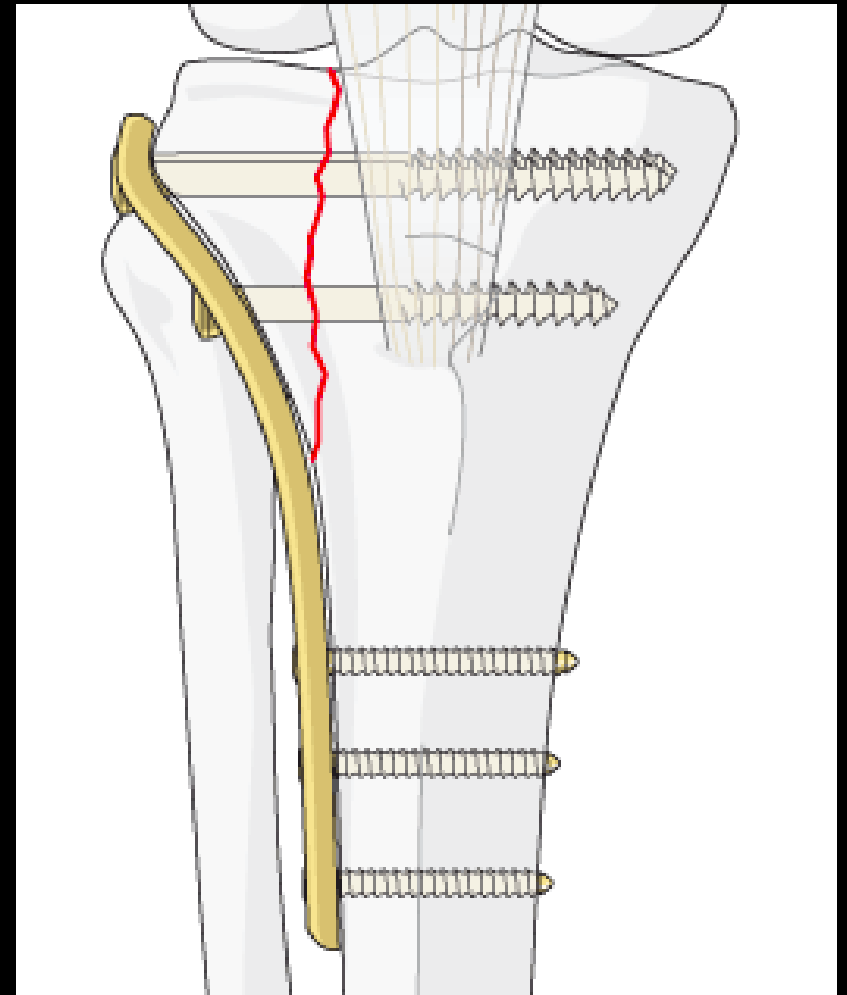
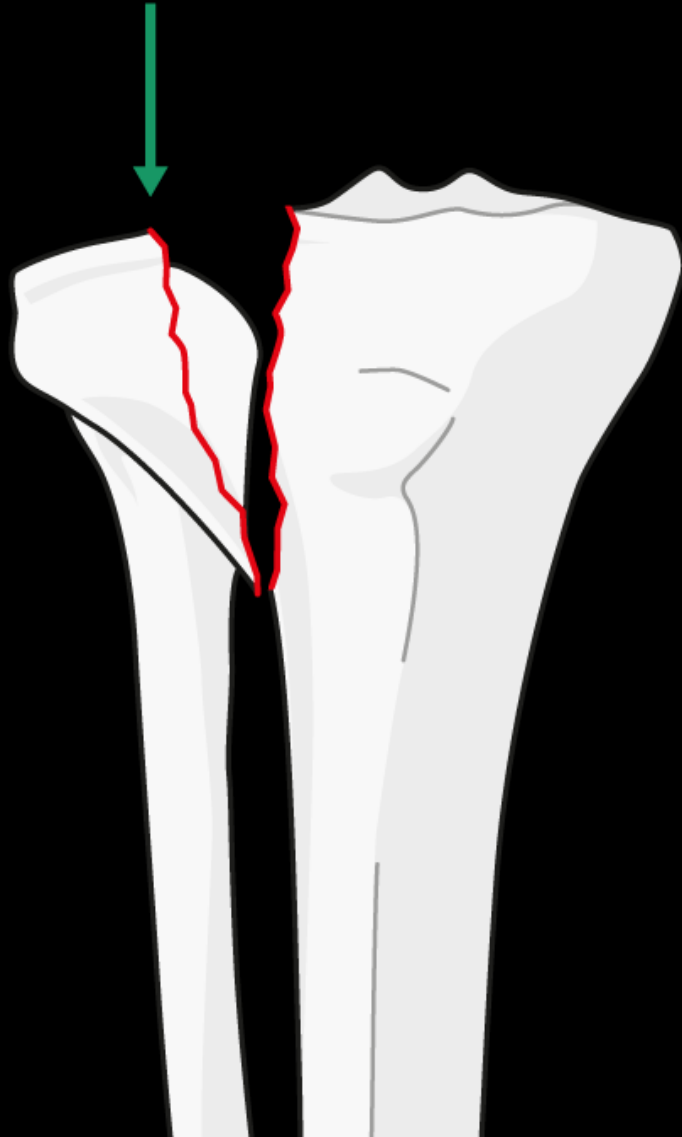
- Anatomisk rekonstruktion af ledflade inkl. kondyl bredde
- Absolut stabilitet (*om muligt*)
- Genskabe akser og rotation
- Stabil fiksaton til metafyse/diafyse
- Tidlig bevægelse



# Behandling



# Behandling

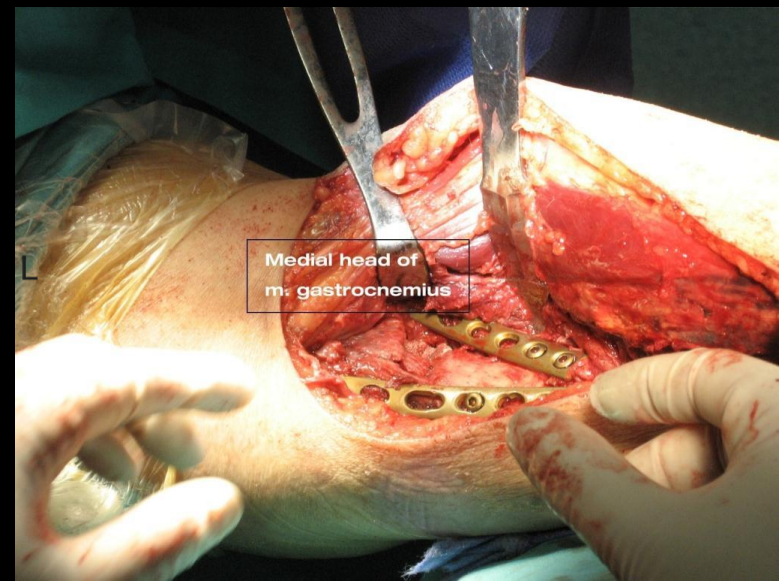
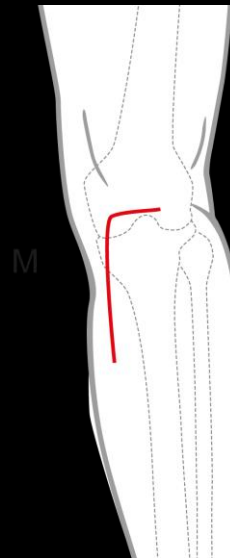
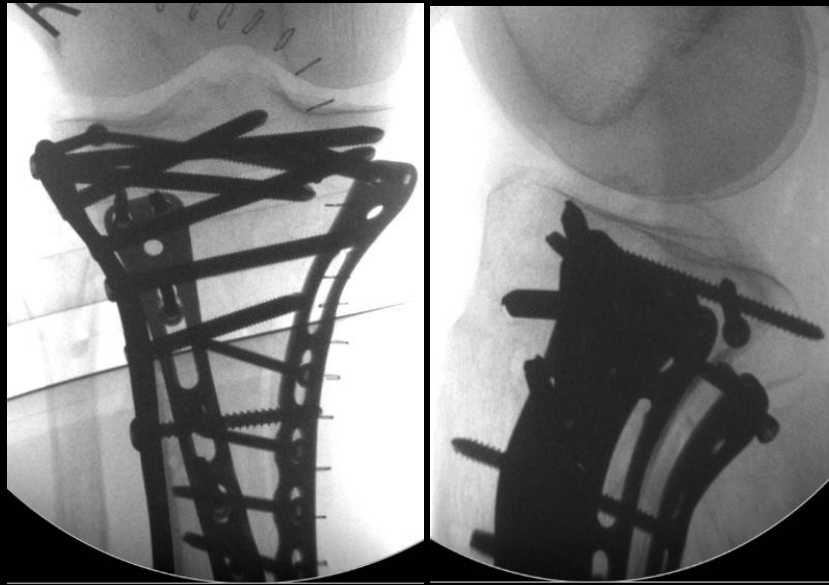
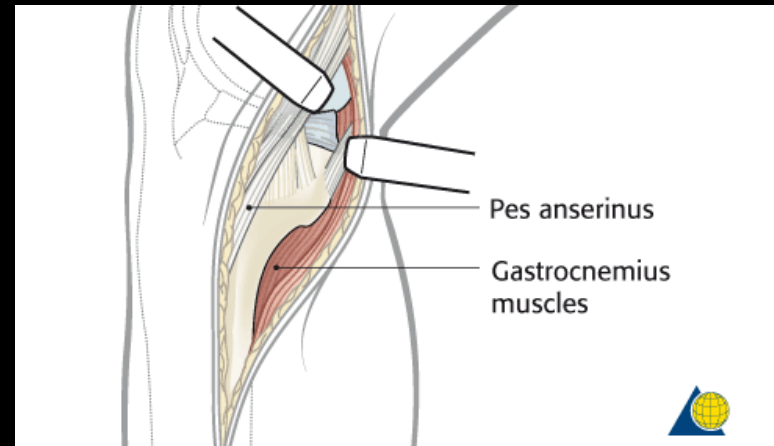
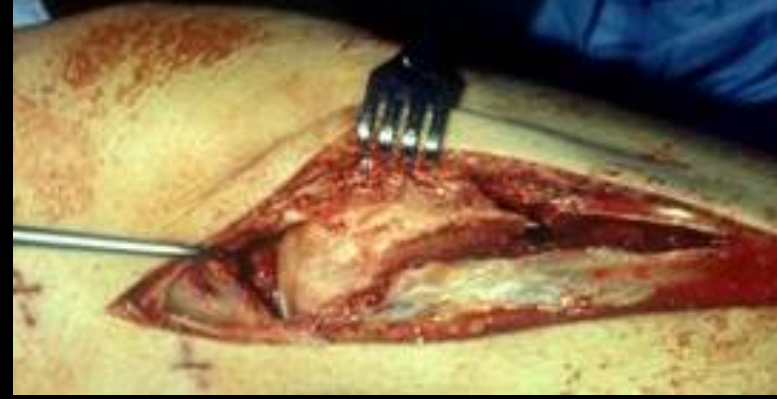




# Kirurgisk adgange

## Proximal tibia

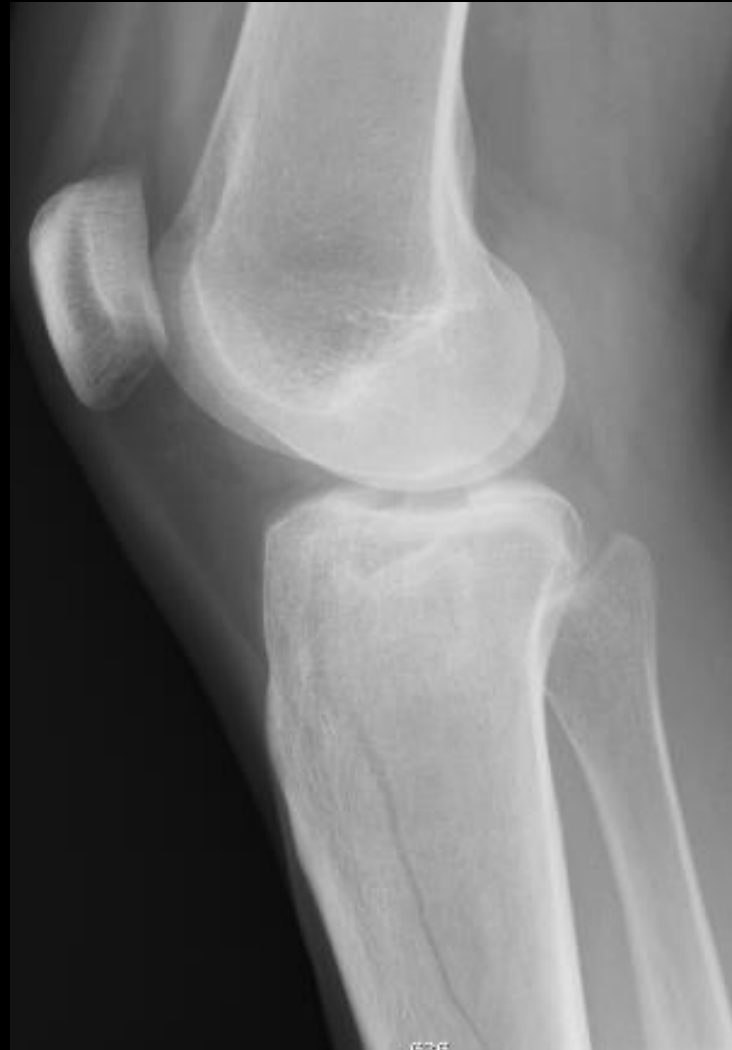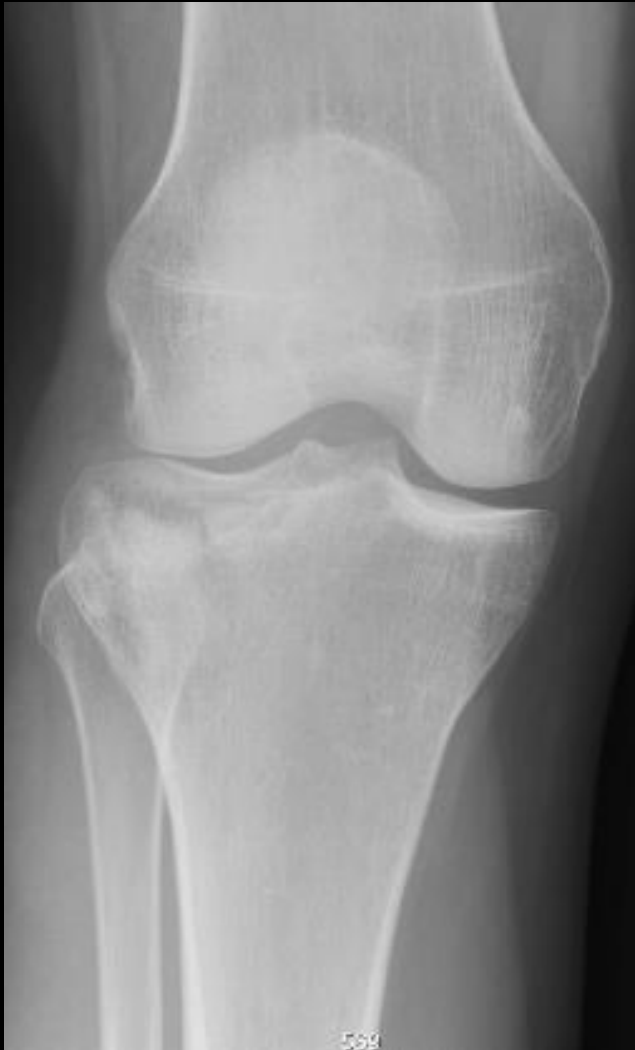- Anterolateral
- Posteromedial
- Posterior





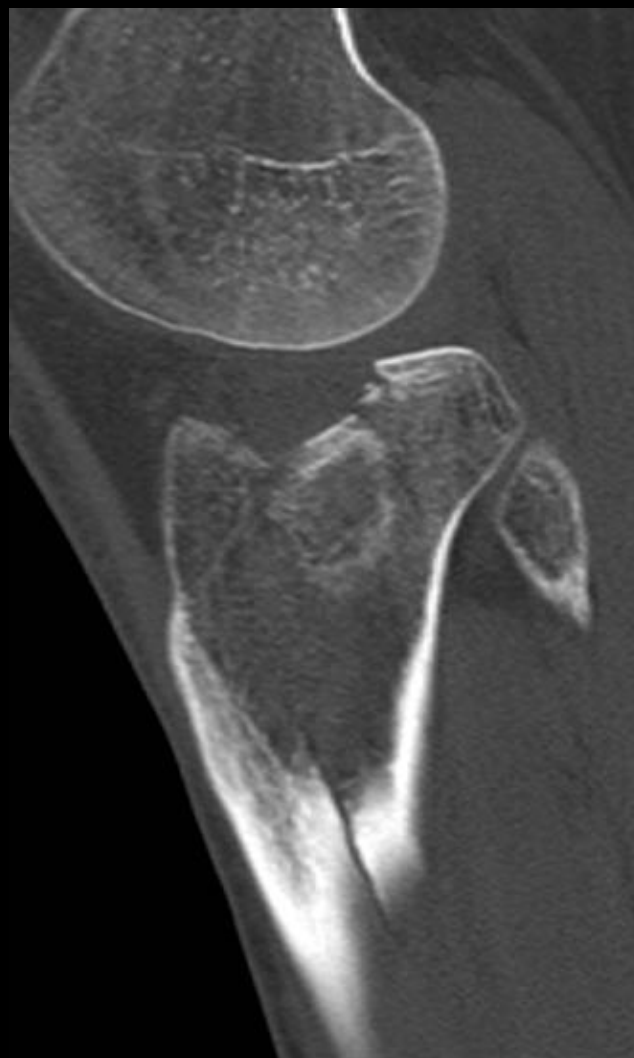
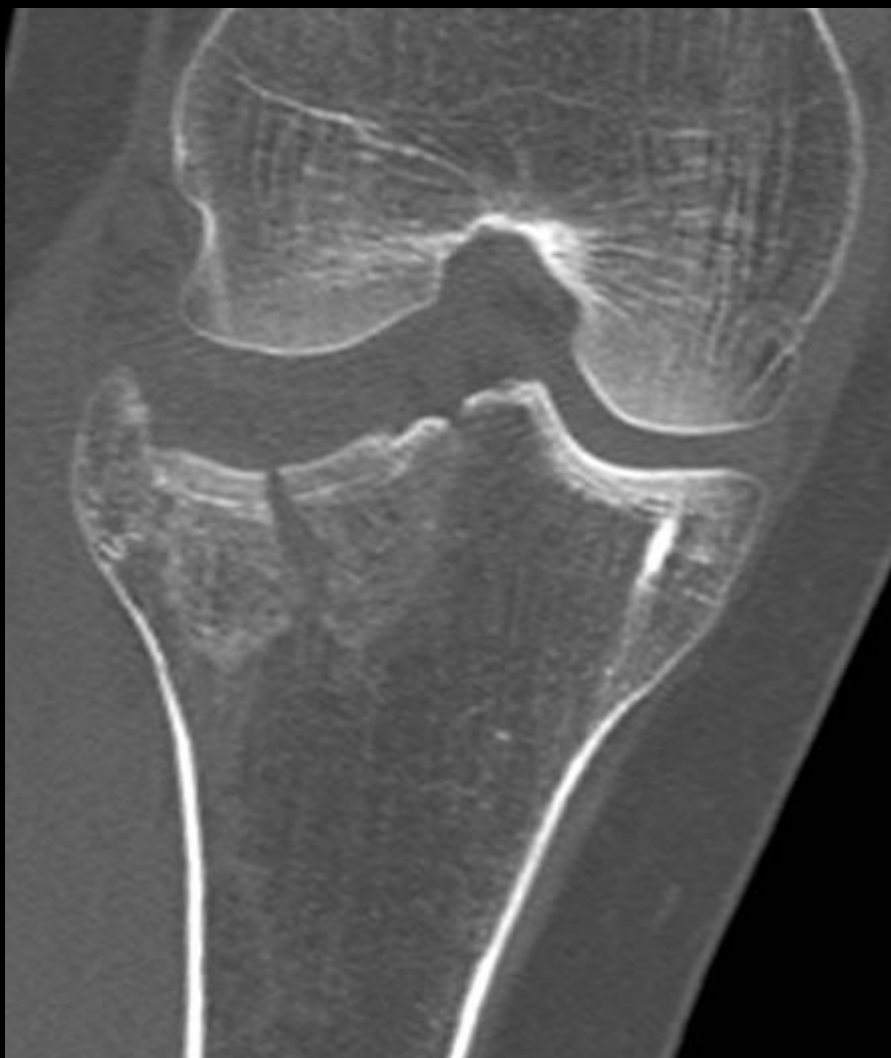**33 år kvinde.**

**Vrid i hø knæ under ridning**



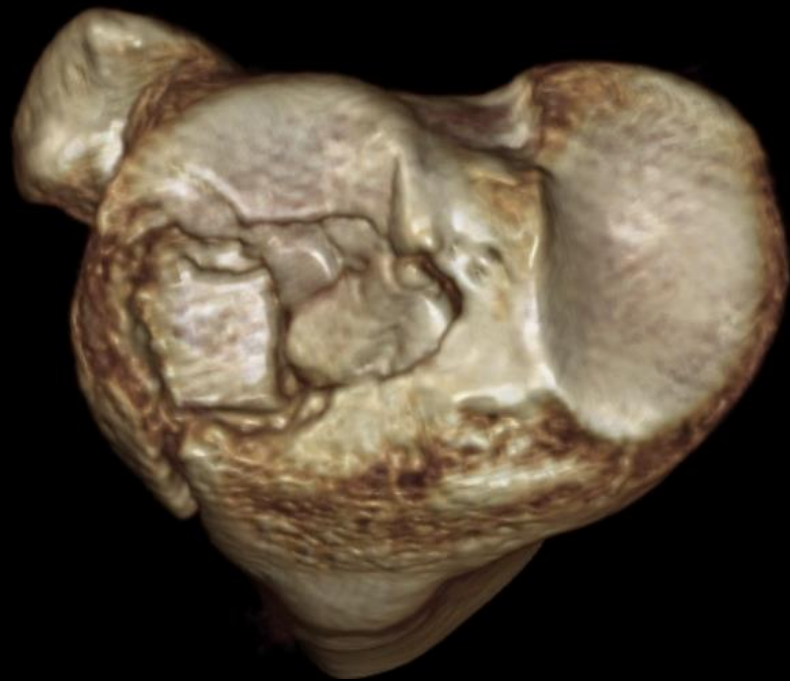
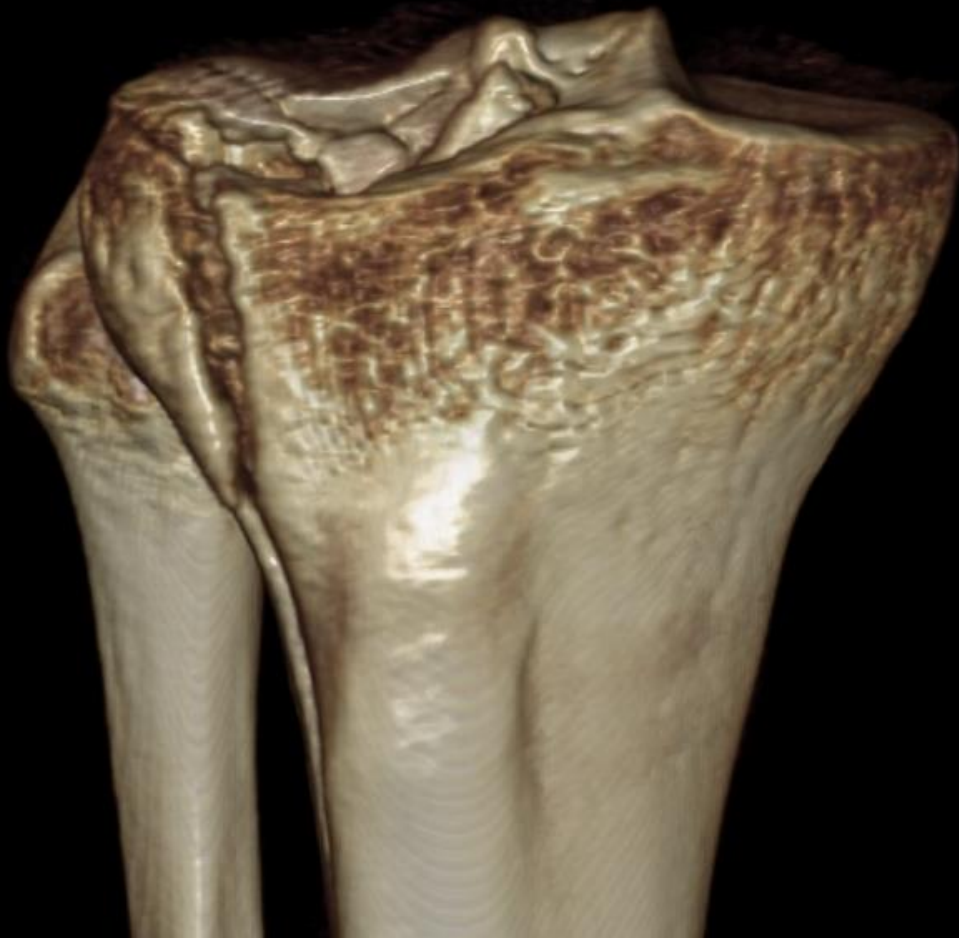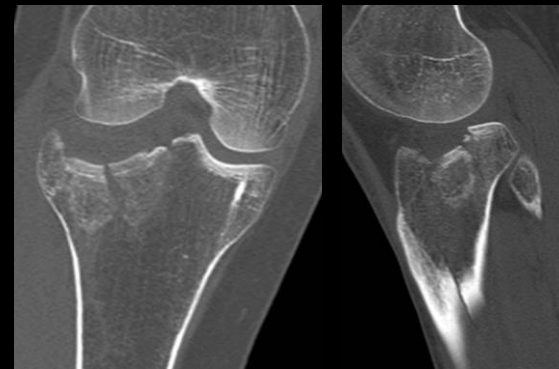
**33 år kvinde.**

**Vrid i hø knæ under ridning**



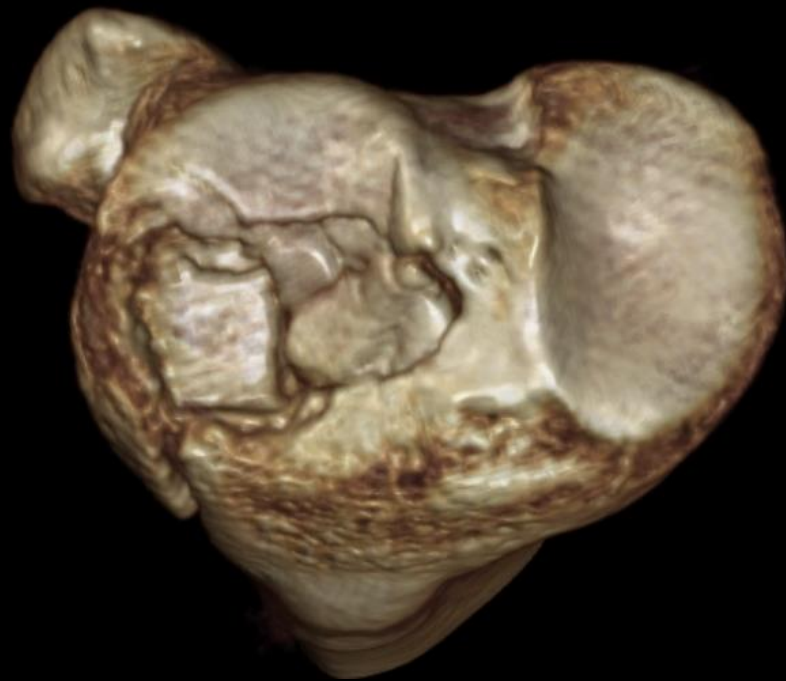
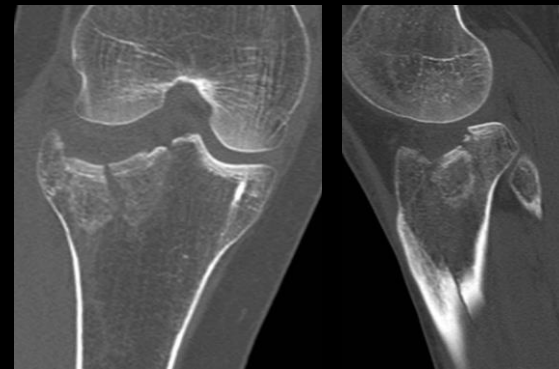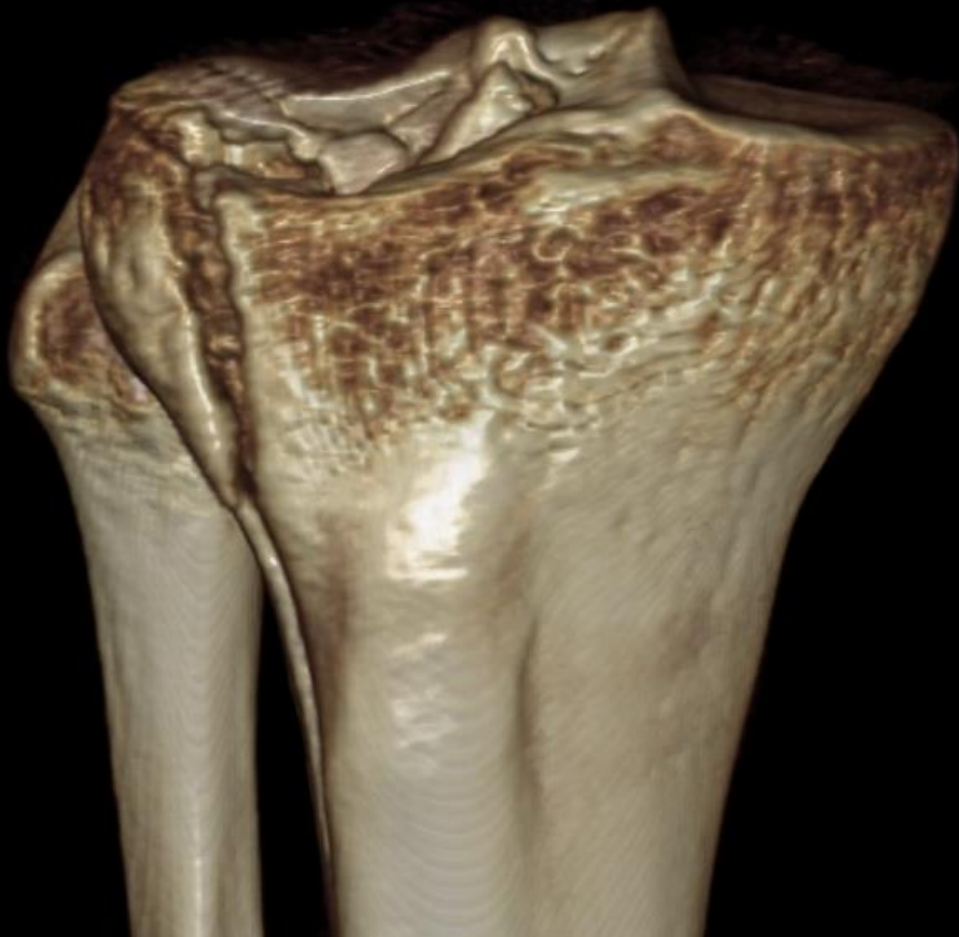
**33 år kvinde.**

**Vrid i hø knæ under ridning**

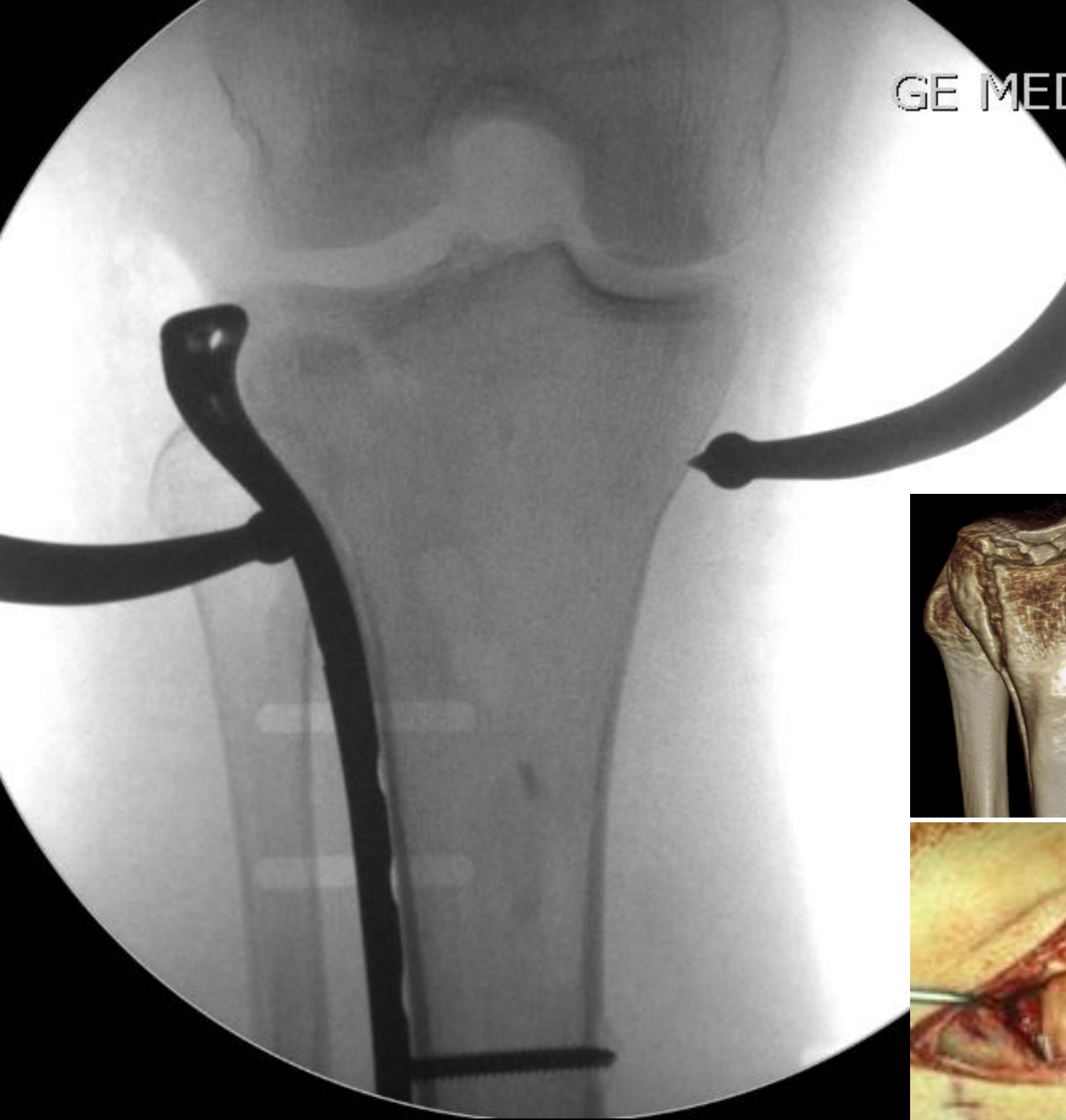


**33 år kvinde.**

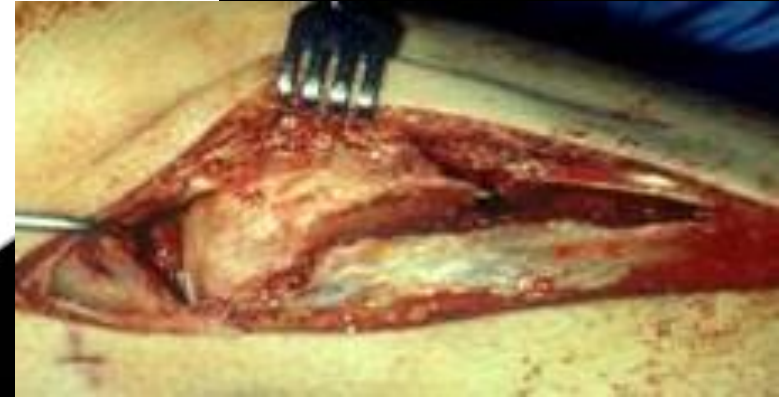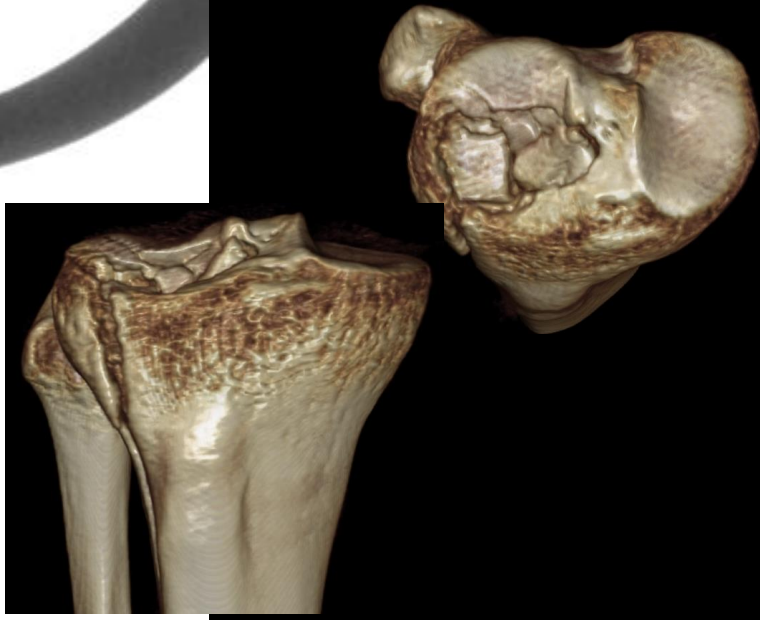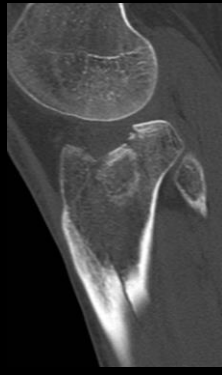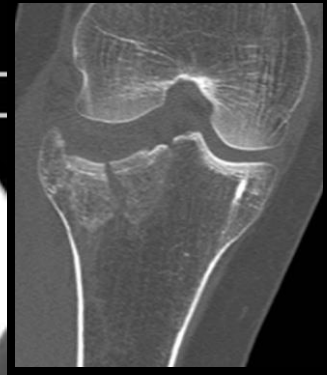
**Vrid i hø knæ under ridning**

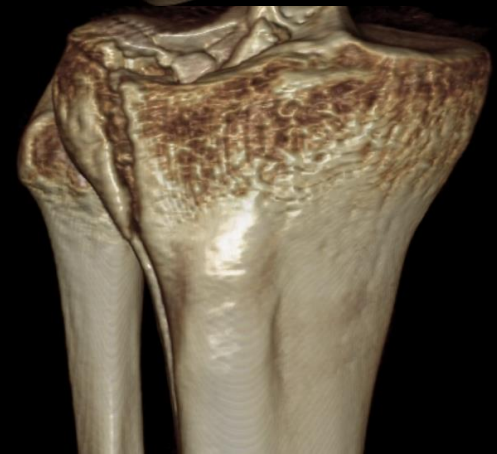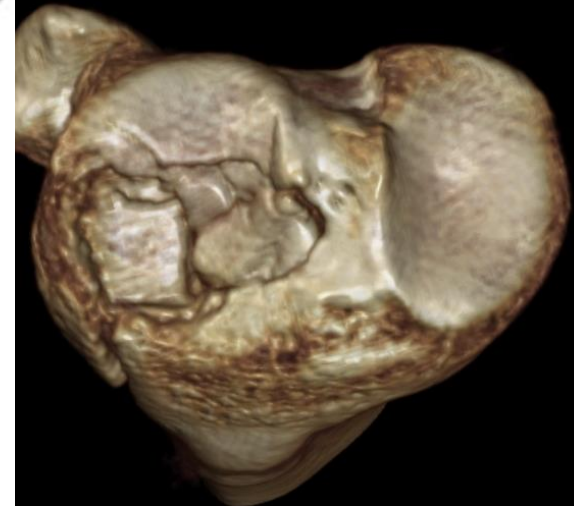
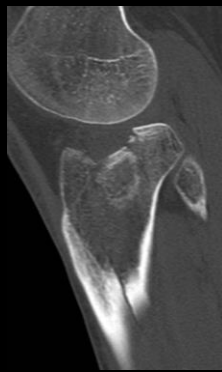
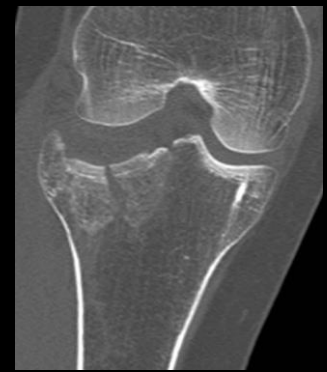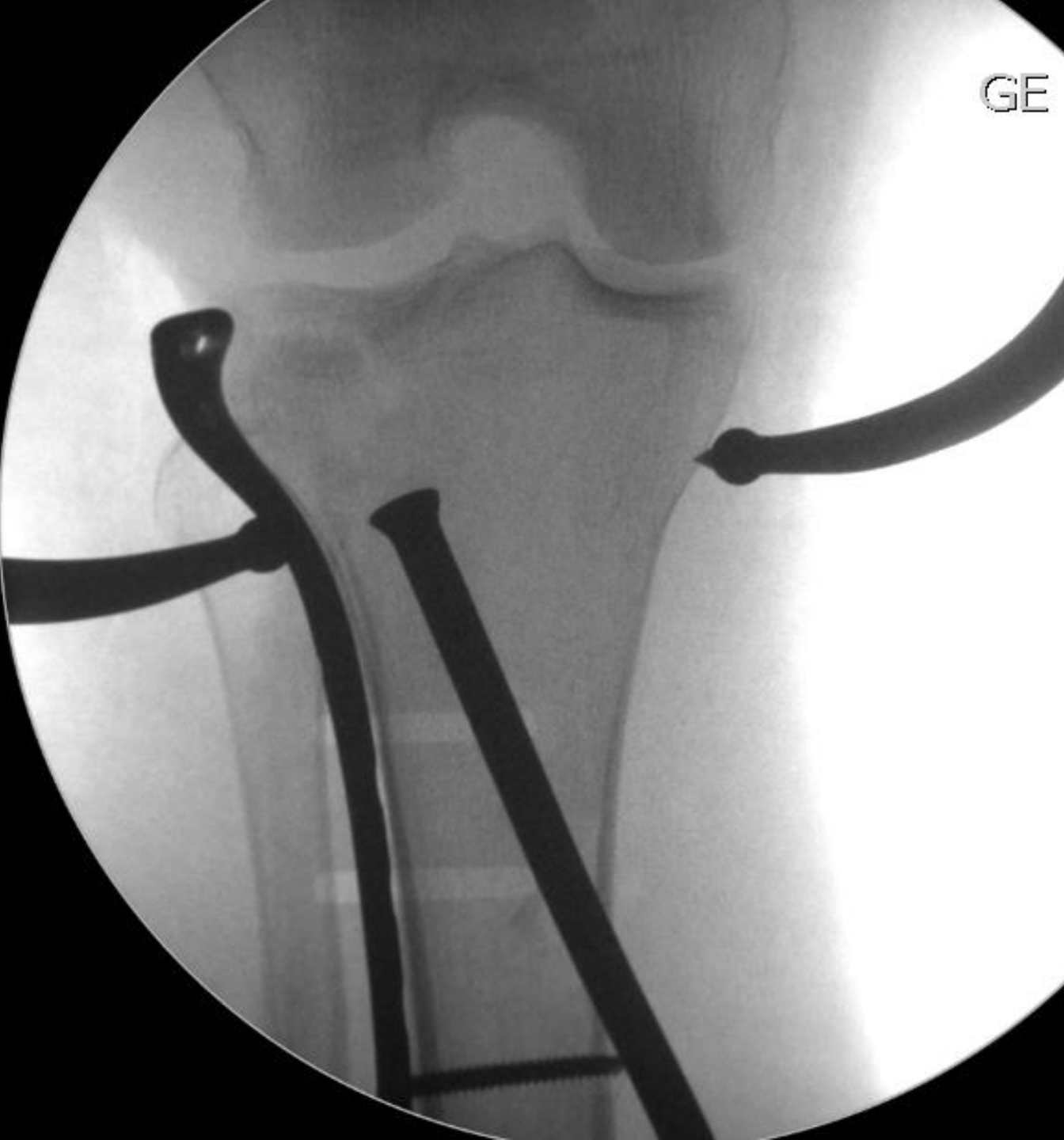


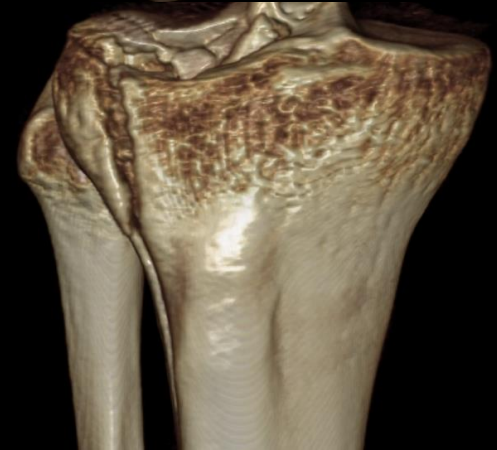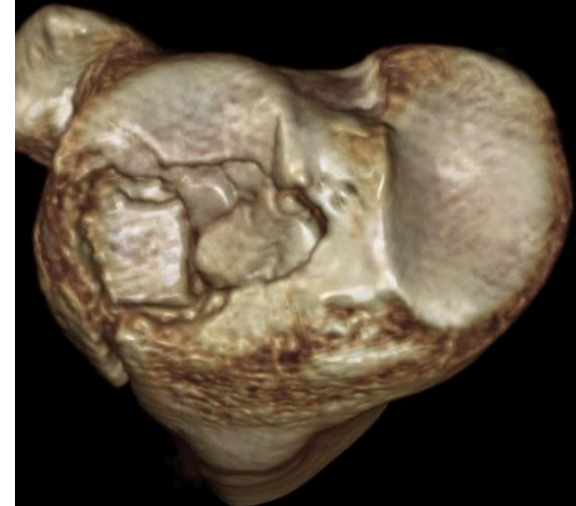
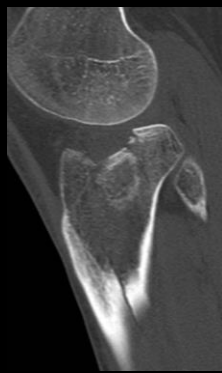



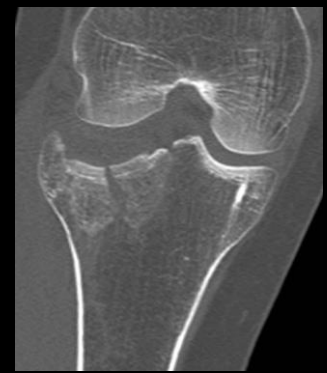
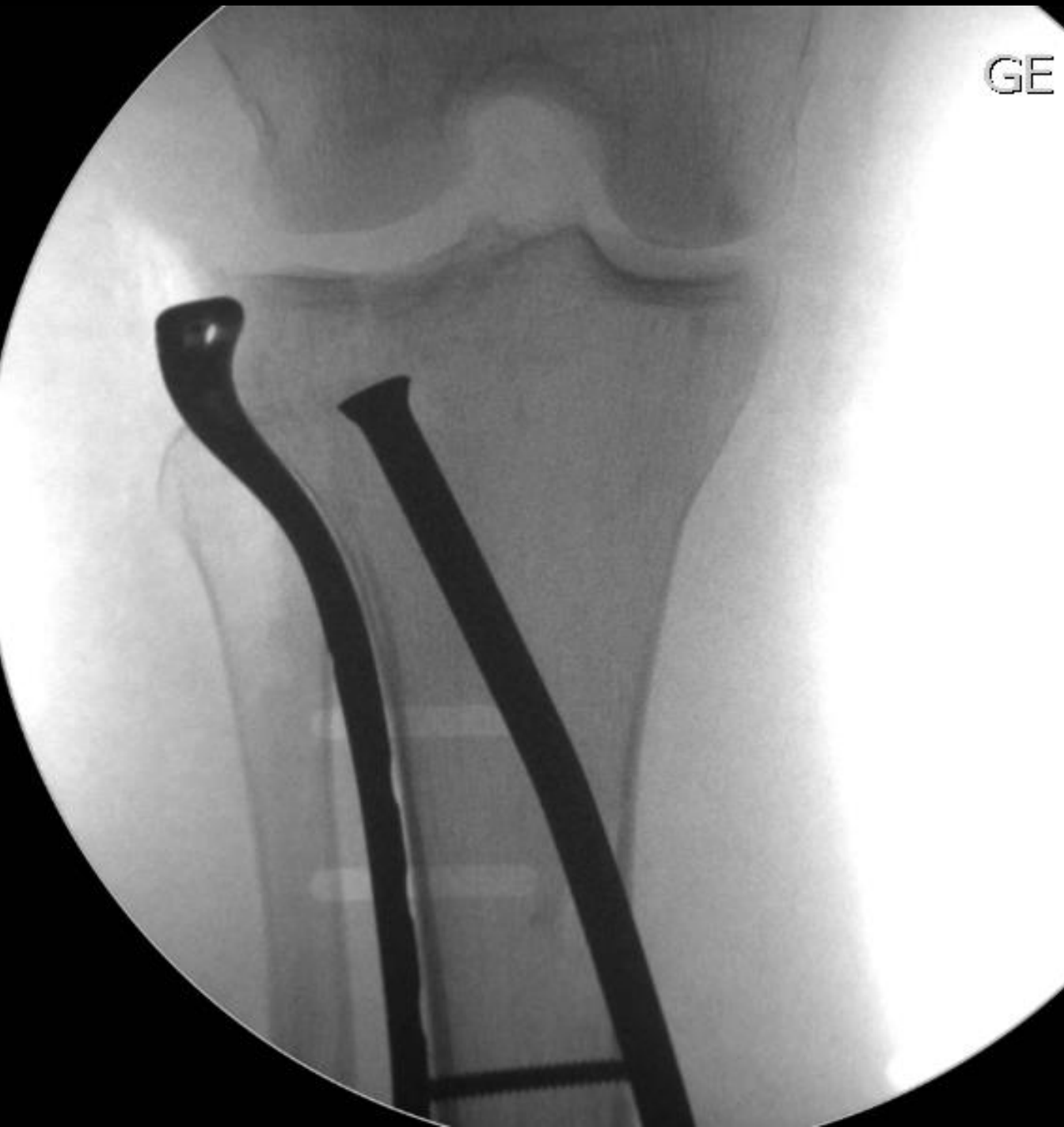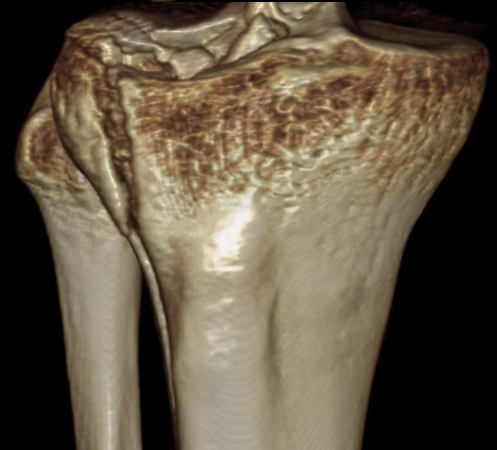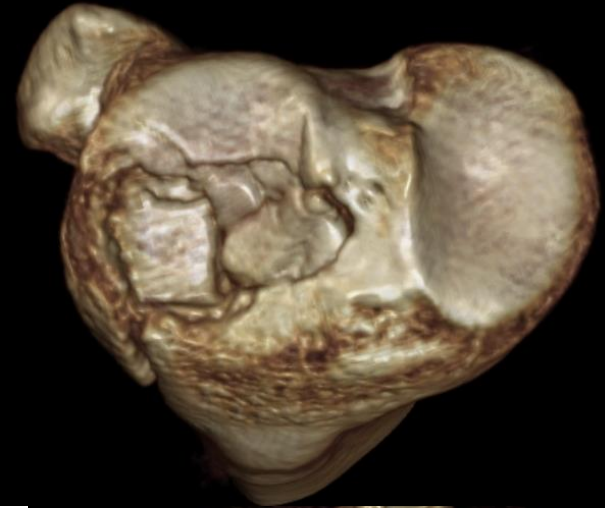
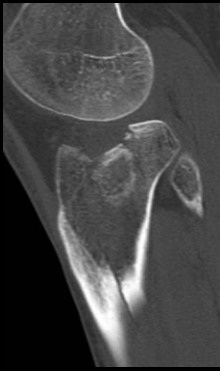
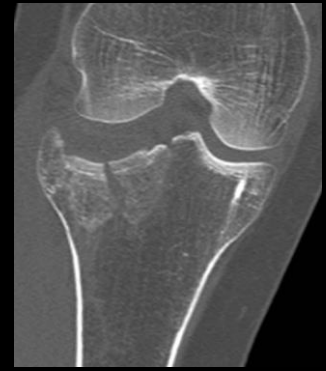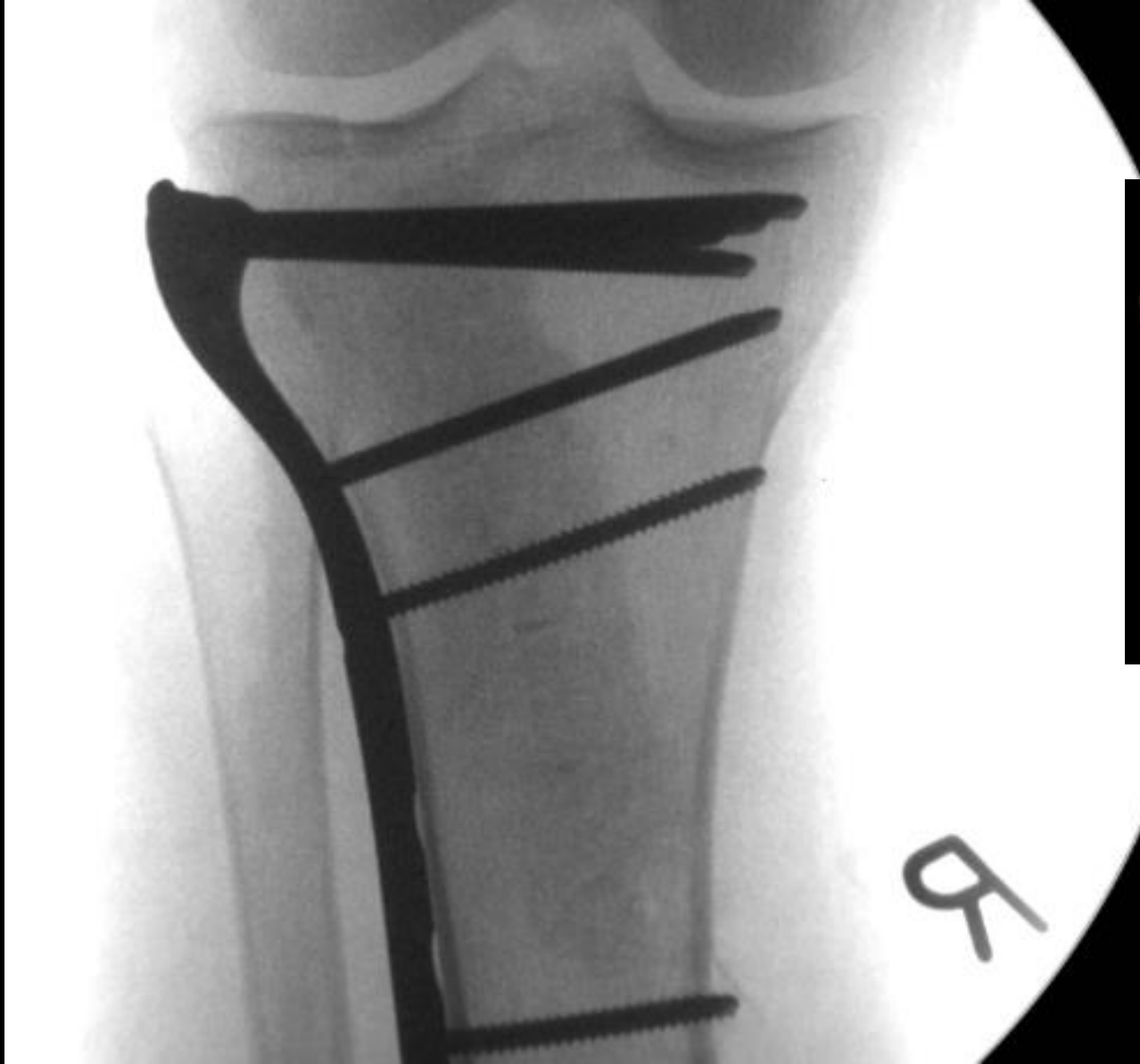GE MED



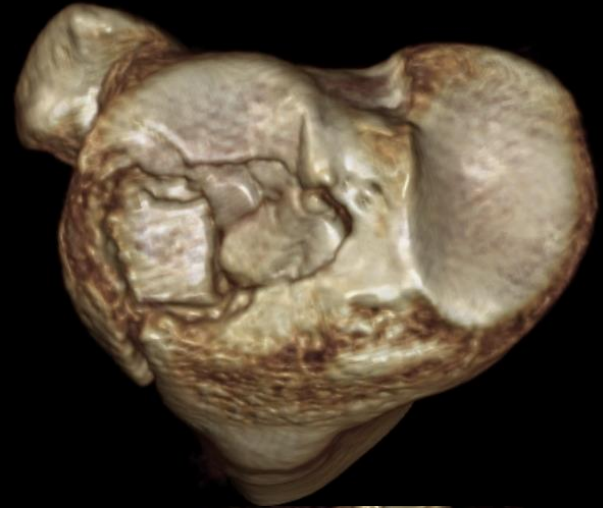
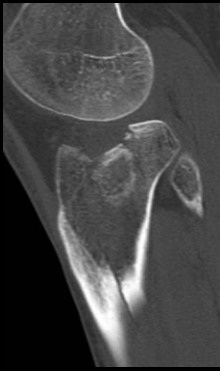


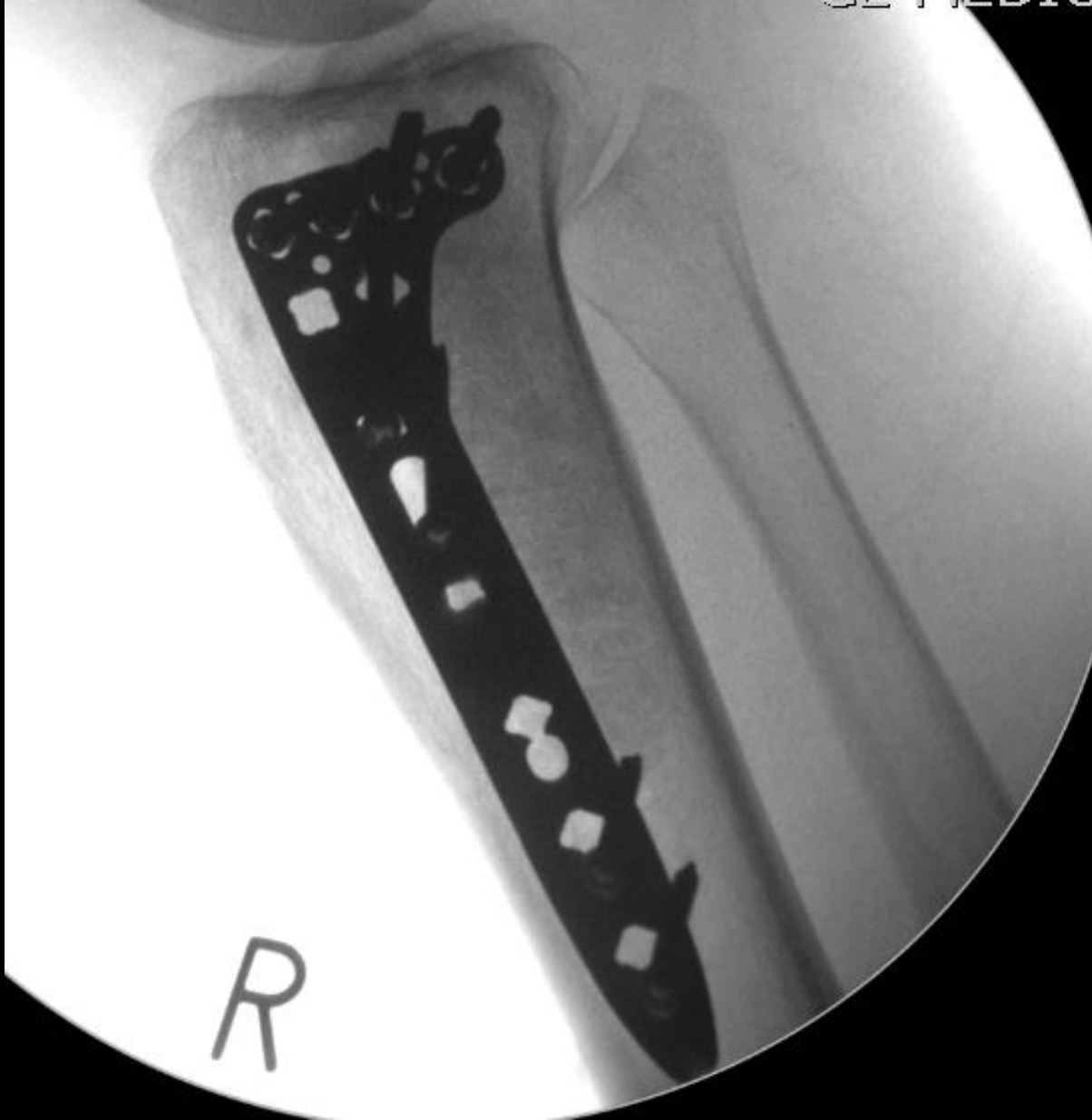

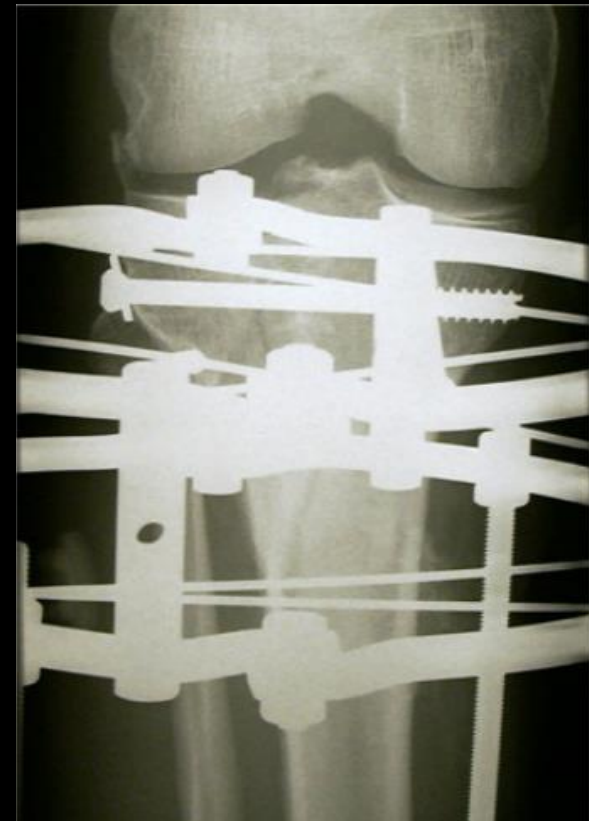



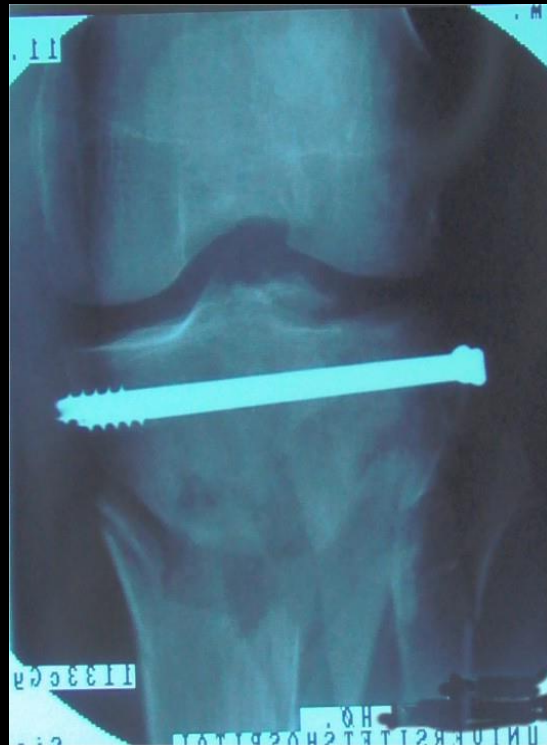
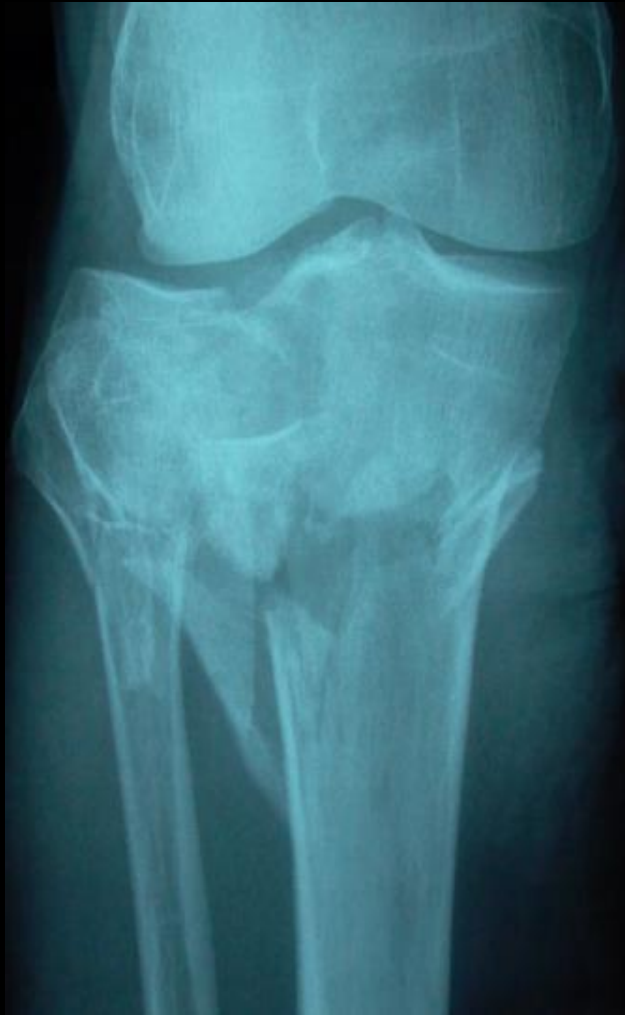



# Ilizarov ekstern fiksdation



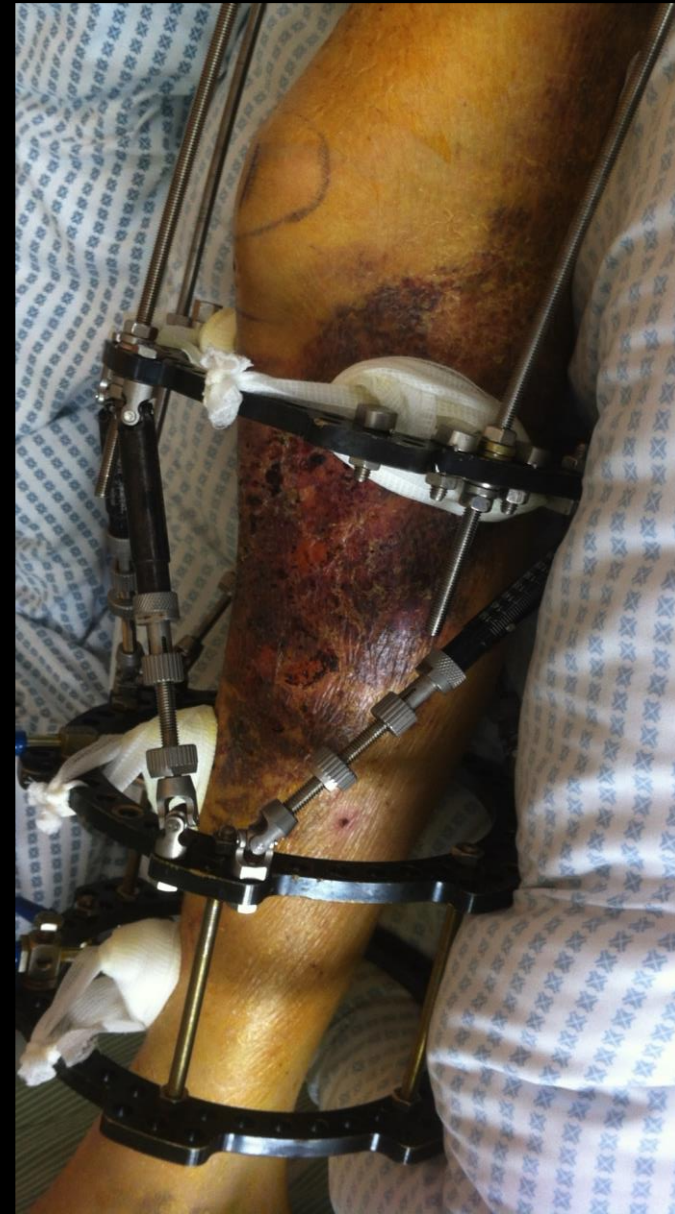# Ilizarov ekstern fikseation

## Fordele:

- Minimal forstyrrelse af bløddede i frakturområdet
- Mulighed at stabilisere knæet ved ligamentærløshed

## Ulemper:

- Udvendig fiksator, kræver pleje; fjernes først når frakturen er helet
- Hyppige pin-hul infektioner - hyppige ambulante kontroller hos problempatienter
- Forhindrer fuld fleksion





# Take-home messages

- Opmærksom på bløddele
  - afgør valg af behandling + timing
- Operations mål:
  - anatomisk reponering af ledflade
  - Korrekt akse og rotation.
  - God fiksatation til metafyse/diafyse
- God præoperativ planlægning . Altid CT
- Ved dårlig bløddele er ringfiksatation 1.valg.
- YDMYGHED – det er svært!!!

